



Burr hole trephination in treatment of convexity arachnoid cyst presenting with headache and anxiety disorder: case report

Baş ağrısı ve anksiyete bozukluğu ile seyreden konveksite araknoid kisti tedavisinde burr hole trefinasyonu: olgu sunumu

Mehmet Turgut^{1,2} 

Murat Özcan Yay¹ 

¹ Department of Neurosurgery, Aydın Adnan Menderes University Faculty of Medicine, Aydın, Türkiye

² Department of Histology and Embryology, Aydın Adnan Menderes University Health Sciences Institute, Aydın, Türkiye

ABSTRACT

In this report, we present a rare case of an arachnoid cyst (AC) of the right frontal convexity in a 18-year-old girl. She presented with a 13-year history of right-sided hemifacial spasm associated with progressive headache during last two months. Her past history revealed that she had not benefited from the drug treatment administered for anxiety disorder. Therefore, surgical drainage via burr-hole trephination was performed and then control examination revealed complete disappearance of her complaints, inspite of partial recurrence of the AC. Here, we present a rare case of convexity AC that caused headache and anxiety disorder and was treated with surgical drainage via burr-hole trephination.

Keywords: Anxiety disorder, arachnoid cyst, burr hole, surgery, trephination.

ÖZ

Bu yazıda, 18 yaşında bir kız çocuğunda nadir görülen bir sağ frontal konveksite araknoid kisti (AK) olgusu sunuyoruz. Son iki ayda progresyon gösteren baş ağrısı ile birlikte 13 yıldır devam eden sağ taraflı hemifasiyal spazm öyküsü ile başvurdu. Öyküsünde, anksiyete bozukluğu nedeniyle uygulanmış olan ilaç tedavisinden fayda görmediği saptandı. Bu nedenle, burr-hole trefinasyonu şeklinde bir cerrahi drenaj uygulandı ve daha sonra yapılan kontrol muayenesinde, AK'in kısmen nüksetmesine rağmen, hastanın yakınmalarının tamamen kaybolduğu görüldü. Burada, baş ağrısı ve anksiyete bozukluğuna sebep olan ve burr-hole trefinasyon yoluyla cerrahi drenaj ile tedavi edilen nadir bir konveksite AK olgusu sunulmaktadır.

Anahtar Sözcükler: Anksiyete bozukluğu, araknoid kist, burr deliği, cerrahi, trefinasyon.

INTRODUCTION

Arachnoid cysts (ACs) are an extra-axial, benign congenital malformation leading to a collection of cerebrospinal fluid (CSF) within the arachnoid membrane (1). They are observed in only 0-1.7% of all magnetic resonance imaging (MRI) studies as an incidental finding in the middle cranial fossa (2, 3). Clinically, they are usually presented with nonspecific symptoms of increased intracranial pressure, such as headache and dizziness, while others rarely present with local neurological deficits. Interestingly, spontaneous

disappearance of an AC has been reported possibly due to absorption of the CSF within the cyst after traumatic event (4). Based on this observation, Kim et al. (5) recently suggested burr hole drainage as a safe surgical procedure for disappearance of the ACs without any recurrence at least 3 months postoperatively. This report illustrates that convexity AC causing headache and anxiety disorder may respond surgical drainage via burr-hole trephination, as a contribution to our understanding of this rare congenital malformation.

Corresponding author: Mehmet Turgut
Department of Neurosurgery, Aydın Adnan Menderes
University Faculty of Medicine, Aydın, Turkey
E-mail: drmturgut@yahoo.com
Application date: 23.03.2021 Accepted: 18.04.2021

CASE REPORT

An 18-year-old girl presented with a 13-year history of right-sided hemifacial spasm and progressive headache during last two months. The past history of the patient revealed that she did not benefit from the drug treatment that was started by the psychiatry department with the diagnosis of anxiety disorder for her complaints. On admission her physical examination and neurological examination was normal. Brain MRI and computed tomography (CT) revealed presence of AC in the right frontal convexity (Figures-1A-C). There was neither any anomaly activity in electroencephalography nor any evidence of recent trauma or hemorrhage. It was

decided to operate due to presence of progressive and persistent anxiety headache. Following the right frontal 3-cm skin incision and 2-mm in diameter burr hole trephination, the outer membrane of AC in the frontal convexity was ruptured after a dura incision and it was then connected to subdural space. A catheter was placed on the burr hole and it was removed in the postoperative first day (Figure-1D). On postoperative first day, her headache and anxiety disorder was completely relieved and CT of the brain scan showed a complete disappearance of the AC (Figure-1 E and F) in spite of partial recurrence of the AC after 1 month after surgery (Figure-1 G and H).

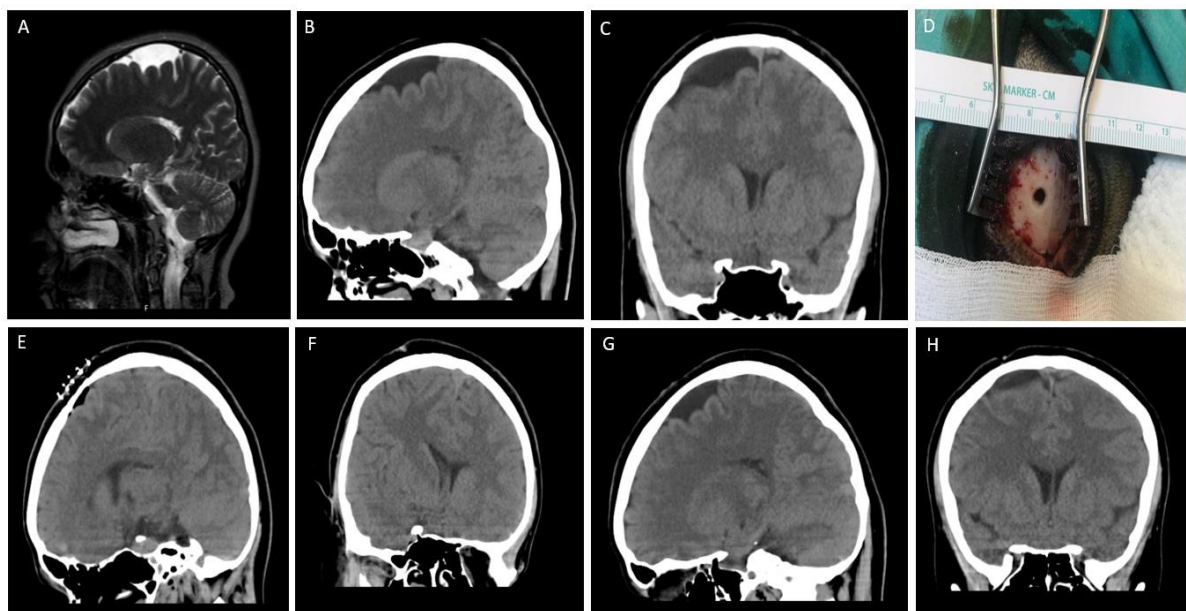


Figure-1. Preoperative sagittal section of MRI (A) and sagittal (B) and coronal (C) sections of CT demonstrating an AC of the right frontal convexity. Intraoperative appearance of the burr hole trephination (D). Postoperative sagittal and coronal sections of CT showing complete disappearance of the AC at first day (E and F) and partial recurrence of AC one month later (G and H)

DISCUSSION

Even today the pathogenesis of the ACs is still controversial and little is known regarding their natural course, although they are generally asymptomatic throughout life and diagnosed incidentally on CT scan and MRI (2, 3, 5-7). Occasionally, they are complicated by intracystic or subdural hemorrhage with/without history of preceding trauma (6, 7). Clinically, ACs are generally detected incidentally and they are often considered silent, but the diagnosis itself can have a significant impact on patients and their

families because of the co-existence of psychiatric and cognitive disorders with AC in some cases, as did in our patient (8-10).

Nowadays, optimal form of treatment of AC is still controversial, although different surgical techniques for treatment of ACs, such as cystoperitoneal shunting and (endoscopic) fenestration with craniotomy or craniectomy, have been described in the literature to date (7). In 2019, Kim et al (5) reported complete and long-term disappearance of the ACs in their three cases following its rupture via burr hole

trephination as a novel surgical option. Considering its minimally invasive feature, we used same burr hole trephination technique in our case, but it resulted recurrence of the AC after one month from initial surgery of the cystic lesion in the frontal convexity, possibly due to development of a new membrane covering the burr hole.

The current case of AC in the frontal convexity presenting with complete relief of headache and

anxiety disorder after surgery is reported to be worth publishing.

Consent for publication

We declared that a written informed consent was taken from the legal guardians of the patient.

Conflicts of interest: There is no conflict of interest.

References

1. Pradilla G, Jallo G. Arachnoid cysts: case series and review of the literature. *Neurosurg Focus*. 2007; 22: E7.
2. Heier LA, Zimmerman RD, Amster JL, Gandy SE, Deck MD. Magnetic resonance imaging of arachnoid cysts. *Clin Imaging*. 1989; 13: 281-91.
3. Gandy SE, Heier LA. Clinical and magnetic resonance features of primary intracranial arachnoid cysts. *Ann Neurol*. 1987; 21: 342-8.
4. Mori T, Fujimoto M, Sakae K, Sakakibara T, Shin H, Yamaki T, Ueda S. Disappearance of arachnoid cysts after head injury. *Neurosurgery*. 1995; 36: 938-41.
5. Kim DU, Park HR, Chang JC, Park SQ, Cho SJ, Park HK. Disappearance of arachnoid cysts after burrhole trephination: case report. *Korean J Neurotrauma*. 2019; 15: 170-5.
6. Huang D, Abe T, Kojima K, Tanaka N, Wataube M, Ohkura A, Nishimura H, Hayabuchi N, Norbash AM. Intracystic hemorrhage of the middle fossa arachnoid cyst and subdural hematoma caused by ruptured middle cerebral artery aneurysm. *AJNR Am J Neuroradiol*. 1999; 20: 1284-6.
7. Sprung C, Armbruster B, Koeppen D, Cabraja M. Arachnoid cysts of the middle cranial fossa accompanied by subdural effusions-experience with 60 consecutive cases. *Acta Neurochir (Wien)*. 2011; 153: 75-84.
8. Cuny ML, Pallon M., Piana H, Boddaert N, Sainte-Rose C, Vaivre-Douret L, Piolino P, Puger S. Neuropsychological improvement after posterior fossa arachnoid cyst drainage. *Child Nerv Syst*. 2017; 33: 135.
9. Gjerde PB, Litleskare S, Lura NG, Tangen T, Helland CA, Wester K. Anxiety and depression in patients with intracranial arachnoid cysts-a prospective study. *World Neurosurg*. 2019; 132: e645-e53.
10. Schertz M, Constantini S, Eshel R. Neurodevelopmental outcomes in children with large temporal arachnoid cysts. *J Neurosurg Pediatr*. 2018; 21: 578-86.