



FETAL SUPRAVENTRICULAR TACHYCARDIA IN ONE OF THE TWIN : A CASE REPORT

İKİZ BEBEKLERİN BİRİNDE FETAL SUPRAVENTRİKÜLER TAŞİKARDİ : OLGU SUNUMU

Ertürk LEVENT A.Ruhi ÖZYÜREK Hasan GÜVEN Aytül PARLAR

Medical Faculty of Ege University, Pediatric Cardiology Department, Bornova, İzmir

Key Words: fetus-fetal tachycardias-multiple pregnancies

Anahtar Sözcükler: fetus-fetal taşikardi-çoklu gebelik

SUMMARY

Many cases have been reported about fetal arrhythmia in single fetus, but up to now few data have been reported about fetal arrhythmia in multiple pregnancies. In this study, we presented the case history of fetal supraventricular tachycardia (SVT) in one of twin who has no structural cardiac abnormalities, from a mother treated betamimetic agents and Magnesium sulfate due to imminent preterm. Digoxin was administered to the mother for fetal SVT in the 28th gestational week. Fetal SVT was treated successfully with digoxin. The babies were delivered at 38th week of the gestation. Transient tacypnea was seen in the fetus with SVT for 12 hours. Electrocardiography (ECG), echocardiography and 24-Hour Holter recordings were normal in both of them. We reported this case because of fetal SVT is seen in one of twin who was successfully treated with digoxin although there was no structural abnormality in heart.

ÖZET

intrauterin olarak tek bebeklerde fetal ritm bozuklukları bildirilmekle birlikte, çoklu gebeliklerde bebeklerde oluşan ritm bozukluk/arıyla ilgili yayınlar nadirdir. Bu çalışmada erken doğum tehdidi nedeniyle magnezyum sülfat alan annenin, kalplerinde yapısal anomali olmayan ikiz bebeklerinin birinde saptanan, fetal supraventriküler taşikardi (SVT) sunulmuştur. Anneye 28. haftada oral digoksin tedavisi verilmiş ve fetal SVT, başarı ile tedavi edilmiştir. 38. haftada doğum olmuş ve SVT olan bebekte geçici takipne gözlenmiştir. Her iki bebekte de doğum sonrası elektrokardiografi, ekokardiografi ve 24-saat holter kayıtları normal olarak saptanmıştır. Bu olgu kalpte yapısal anormallik olmadan, ikiz bebeklerin birinde saptanan fetal SVT ve başarılı tedavisi nedeniyle sunulmuştur.

INTRODUCTION

During pregnancy, a number of rhythm disturbances can occur in both the mother and fetus ranging from benign ectopy to life-threatening arrhythmias (1). Fetal echocardiography plays a major role in the diagnosis and observation of these arrhythmias. Fetal echocardiography can be used to diagnose fetal cardiac disrhythmias accurately with combination of M-mode, 2-D and doppler echocardiography. The nonhydropic fetus with a tachycar-

dia has an excellent prognosis with transplacental treatment (2-4). Although an important success is achieved in the treatment of tachycardias in singleton especially nonhydropic fetus, few publications have been reported about multiple pregnancies (5, 6). We reported this case since fetal SVT is seen in one of twin although there is no structural abnormality in the heart.

CASE

A 32-year old gravida 1 para 0 multiple inseminated pregnant who had no significant medical, drug history or alcohol ingestion, came to our clinic. The mother had no signs of any disease. Mother had been treated

Yazışma adresi: Ertürk Levent, Medical Faculty of Ege University, Pediatric Cardiology Department, Bornova, İzmir

Makalenin geliş tarihi: 18.01. 2002 ; Kabul tarihi: 14. 05. 2002

betamimetic agent (ritodrine) and Magnesium sulfate intravenously due to imminent preterm since 26th gestational week. In the 28th gestational week, SVT is observed in one of twin by obstetrical USG. On fetal echocardiography a normal appearing of two fetuses was seen. The cardiac structures were normal. There was no evidence of hydrops in both of them. The atrial and ventricular rate was 275-286 beats per min in one fetus in Doppler and M mode (Figure 1, 2). The other fetus' heart rate was normal. Maternal digoxin treatment was given orally at a dose of 0.25 mg daily and the dose was adjusted to achieve a maternal serum concentration in the therapeutic range. Maternal serum levels of digoxin ranged between 1,7 and 2.4 ng/ml and no maternal side effects of digoxin. The fetus was noted to be in sinus rhythm with a rate of 140-148 beats per min by M-Mode at the 72nd hour after digoxin started (Figure 3). Other fetus' heart rate was observed between 132 and 148 beats per min during the digoxin treatment. No rhythm disturbances were observed during weekly evaluation of the fetus' heart rate. The female babies were delivered at 38th weeks of gestation without dysrhythmia. Apgare scores were 6-7 at 1 minute and 8-9 at 5 minute and their weights were 2370g and 2640g consequently. ECG, echocardiography and 24-Hour Holter recordings were normal in both of them. Transient tacypnea was seen in the fetus with SVT for 12 hours. The digoxin levels of the newborns were measured as 0,67 and 0.78 ng/ml consequently at the 24th hour of life.

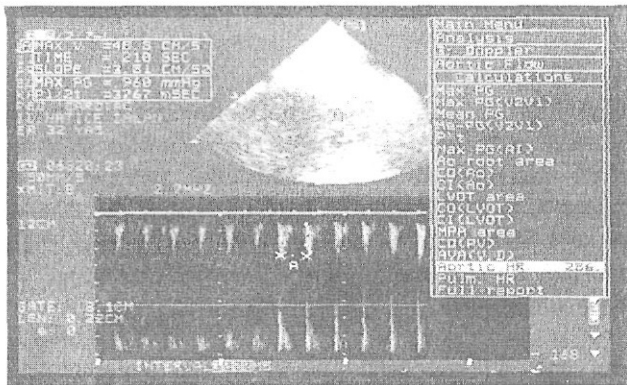


Figure 1. Fetal Doppler examination from the one of twin who has SVT




Figure 2. Fetal M-mode examination from the one of twin who has SVT




Figure 3. Fetal M-mode examination after digoxin treatment

DISCUSSION

Fetal echocardiography with a combination of the two-dimensional, M-mode, and pulsed doppler techniques can be used to accurately diagnose fetal cardiac arrhythmias (1). The majority of the nonhydropic fetuses were converted to sinus rhythm using oral maternal digoxin therapy alone in fetal tachyarrhythmias (2, 4). However limited published data were reported about fetal tachyarrhythmias in multiple pregnancies.

Czeszynska et al. reported fetal and neonatal arrhythmia in one of the twins from two mothers treated with betamimetic agents (5). Their first case with fetal bradycardia due to complete AV block had VSD and PFO. In their second case with prenatal detected extrasistol had normal heart anatomy. They administered digoxin to the mother but postnatal bradycardia was observed in the baby. In our case, both babies did not have any cardiac abnormalities, and digoxin was administered with success.

Edward et al. presented the case of twin pregnancy in which one fetus developed hydrops secondary SVT at 30 weeks' gestation (6). They treated SVT successfully without evidence of side effects with flecainide administration.

In our case, betamimetic (ritodrine) and magnesium sulfate were administered to the mother intravenously in order to prevent imminent preterm. Beta agonists have many potential cardiovascular side effects. Clinical significant fetal effects are less common (7). Neonatal cardiac tachyarrhythmias have been reported with these sympathomimetic agents especially intravenous ritodrine (7). Fetal and neonatal cardiovascular complications attributable to magnesium sulfate are rare (8). A study of more than 7000 fetuses and offspring of mothers treated with magnesium sulfate showed no adverse effects (8). In

our case, these agents were administered to the mother in order to prevent preterm labor during artificial insemination gestation.

In our case fetal SVT was observed and there was no cardiac abnormality in both fetuses. Digoxin therapy was started immediately and rhythm converted to sinus at 72nd hour. No side effects were seen in the other baby and the

mother. Postnatal rhythm disturbances were not observed in the babies.

In this case, maternal digoxin therapy was treated with success. Drug choice is an important issue in the multiple pregnancies with fetal arrhythmias. Some ethical and legal issues can be occur in case of the treatment of one fetus in a twin pregnancy, cause complications to the other fetus and the mother.

REFERENCES

1. Rowland DG, Wheller JJ. Fetal cardiac arrhythmias. Ailen HD, Ciark EB, Gutgesell PH, Driscoll DJ, ed. Moss and Adams' heart disease in infants, children, and adolescents, 6th ed. Vol. 1. Philedelphia: üppincott, Williams & Wilkins, 2001: 577-580.
2. Joglar JA, Page RJ. Antiarrhythmic drugs in pregnancy. *Curr Opin Cardiol* 2001; 16(1): 40-45.
3. Simpson JM, Sharland GK. Fetal tachycardias: rmanagement and outcome of 127 consecutive cases. *Heart* 1998; 79(6): 576-581.
4. Simpson LL. Fetal supraventricuiar tachycardias: diagnosis and management. *Semin Perinatol* 2000; 24(5): 360-372.
5. Czeszynska MB, Wegrzynowski J, Czajkowski Z, Dawid G. Fetal and neonatal arrhythmia in one of the twins-a case history. *Açta Genet Med Gemellol* 1998; 47(3-4): 197-200.
6. Edvrards A, Peek MJ, Curren J. Transplacental fleacinide therapy for fetal supraventricuiar tachycardia in a twin pregnancy. *Aust N Z J Obstet Gynaecol* 1999; 39 (1): 110-112.
7. Reiss RE. Maternal diseases and therapies affecting the fetal cardiovascular system. Ailen HD, Clark EB, Gutgesell PH, Driscoll DJ, ed. Moss and Adams' heart disease in infants, children, and adolescents. 6th ed. Vol.1. Philedelphia: Lippincott, Williams & Wilkins, 2001:551-557.
8. Stone SR, Pritchard JA. Effect of maternally administered magnesium sulfate on the neonate. *Obstet Gynecol* 1970; 35:574-577.