



EFFECTS of SYSTEMIC FLUORIDE INTAKE on RAT GASTRIC MUCOSA

RAT GASTRİK MUKOZASINDA SİSTEMİK FLORİD ALIMININ ETKİLERİ

Çiğdem ELBEK ÇUBUKÇU

Pediatric Dental Clinic Uludag University, Faculty of Medicine Gorukle Campus 16059 BURSA-TURKEY

Anahtar kelimeler : Sistemik Florid Alımı, Rat Gastrik Mukozası

Key words: Systemic Fluoride Intake, Rat Gastric Mucosa

ABSTRACT

This paper presents a study that was carried out to determine the adverse effects of graded doses of fluoride on rat gastric mucosa. Fifty Swiss Albino rats were used. Experimental groups received a solution of 0.5, 5, 50, and 500 ppm fluoride. Control group had distilled water. These solutions administered to the experimental animals during 30 days. In Group V experiment duration was 12 h. In all experimental groups, the rat stomachs were prepared for stereomicroscopic and light microscopic investigation to identify the morphologic and histologic changes. H&E and PAS stains were used for cellular detail. The most specific finding in high fluoride concentrations was mucus layer loss. The fluoride injury was limited in the luminal one-third of the mucosa. Fluoride damaged histological structure in gastric mucosa without causing any injury macroscopically.

ÖZET

Bu makale, kademeli florid dozlarının rat gastrik mukozası üzerindeki yan etkilerini belirlemek için yapılmış bir çalışmayı sunmaktadır. Çalışmada elli adet Swiss Albino ratı kullanıldı. Deneysel gruplara, 0.5, 5, 50 ve, 500 ppm florid solüsyonları uygulandı. Kontrol grubu için distile su kullanıldı. Solüsyonlar, Grup V'e 12 saat olmak üzere, diğer deneysel gruplara 30 gün süresince uygulandı. Tüm deney gruplarında, rat mideleri, morfolojik ve histolojik değişikliklerin incelenmesi amacıyla stereomikroskop ve ışık mikroskobu için hazırlandı. Hücresel detaylandırmada, H&E ve PAS boya ları kullanıldı. Yüksek florid konsantrasyonlarındaki en spesifik bulgu mukus tabakası kaybı olmuştur. Floride bağlı hasar mukozanın üçte biriyle sınırlı kalmıştır. Florid gastrik mukozada makroskopik hasara neden olmaksızın histolojik yapıya zarar vermiştir.

INTRODUCTION

Fluoride is incorporated in a number of preparations which are used to prevent dental caries and promote mineralization of teeth and bones, especially when ingested frequently in small quantities over a long period of time. Adverse effects of topical fluoride preparations on gastrointestinal tract were demonstrated in several studies (1-6). When fluoride is topically applied to the teeth, any fluoride not removed from the mouth either during or at the conclusion of the treatment, will almost certainly be swallowed. It will then come into contact with the gastric mucosa, a glandular epithelial tissue different from the squamous epithelium of the oral cavity (2).

This paper presents a study that was carried out to determine the adverse effects of graded doses of systemic fluoride on rat gastric mucosa and to discuss the clinical implications of the study from a clinical standpoint.

MATERIAL and METHODS

Fifty Swiss Albino rats weighing between 40-50 g were randomly assigned to five groups of ten rats each. Experimental groups received a freshly prepared solution of 0.5, 5, 50, and 500 ppm fluoride as sodium fluoride (NaF). Control group had distilled water (Table 1).

Experimental solutions were prepared by mixing NaF in powder form (GmbH&Co. KG.D-30926, Seelze, Ridel-de Haen 01148) with distilled water. These solutions administered to the experimental animals in plastic bottles as drinking water during 30 days except the animals of Group V. In Group V, the rats were deprived of regular food and water for 24 h to investigate the effect of 500 ppm fluoride on empty stomach. Straw lair within animal cages was removed with pebble to provide complete starviness.

Yazışma adresi: Çiğdem ELBEK ÇUBUKÇU, , Pediatric Dental Clinic
Uludag University, Faculty of Medicine Gorukle Campus 16059 BURSA-
TURKEY

Makalenin geliş tarihi : 23.10.2003 ; kabul tarihi : 01.03.2005

Table 1. Experimental Design

Experimental Groups	Fluoride Concentrations	Duration
Group I (Control Group)	0 ppm (Distilled water)	30 days
Group II	0.5 ppm	30 days
Group III	5 ppm	30 days
Group IV	50 ppm	30 days
Group V	500 ppm	12 hours

After 24 hours, a gastric feeding tube attached to a 2.5 ml syringe was introduced to the stomach lumen via the mouth and esophagus with anesthesia, and 1.5 ml of test solution was deposited. The animals were returned to their cages and allowed free access to food and water for 12 hours (3). During the experiment, general health of the rats was observed two times a week. Experimental solutions in plastic bottles were checked periodically and the necessary amount of the solution was added to the bottles. The plastic bottles carrying NaF solutions were disinfected periodically to prevent any contamination. At the end of the experiment each animal was anesthetized with cetamine and decapitated in the direction of Ethical Board of Faculty of Medicine. The rat abdomens were quickly opened, the stomachs excised, opened along the greater curvature, rinsed in tap water and then stretched on styrofoam for stereomicroscopic investigation. Stereomicroscope was used to identify the morphological changes such as discoloration, hyperemia, erosion, bleeding, or ulceration especially in oxyntic glandular mucosa area of gross stomach specimens.

After the completion of stereomicroscopic investigations the gross stomachs were trimmed. As previous studies have shown, the histological evident fluoride-induced damage was limited to the glandular portion of the rat stomachs (1,3). Sections taken from the random areas of oxyntic glandular mucosa were paraffin embedded and routinely processed for light microscopy. Hematoxylin and Eosin (H&E) stain was used for cellular detail. Then the same section was re-prepared for the Periodic acid-Schiff (PAS) diastase to visualize of the mucus layer and mucus-containing cells.

RESULTS

Stereomicroscopic Findings:

On gross inspection, when group V (500 ppm F-) was compared with the Group I (distilled water, 0 ppm F-); oxyntic glandular areas of the mucosa had a hyperaemic appearance (Figure 1).

Light microscopic Findings:

H&E Stain:

The control specimens showed the fullness of surface mucous cells and their rounded profiles. Most of the mucous epithelial cells were columnar in shape. The gastric pits (foveolae) are lined with surface mucous epithelial cells. The gastric glands and gastric pits were structurally intact. Gastric mucosa sections of Group II

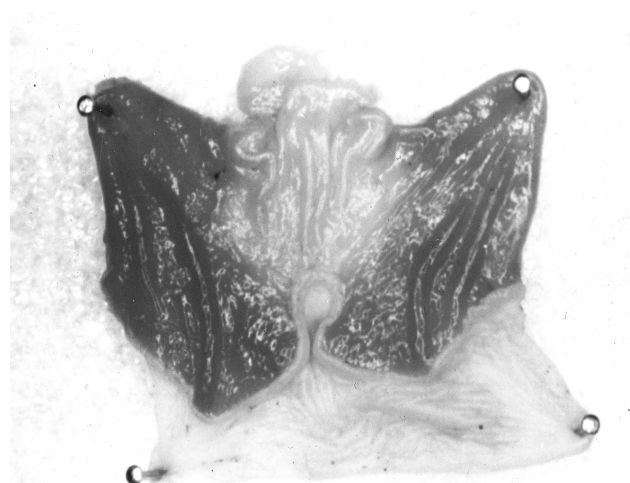


Figure 1. Stereomicroscopic appearance of hyperaemic oxyntic glandular area from 500 ppm F⁻ treated gastric mucosa (x16). (h: hyperaemia ogm: oxyntic glandular mucosa)

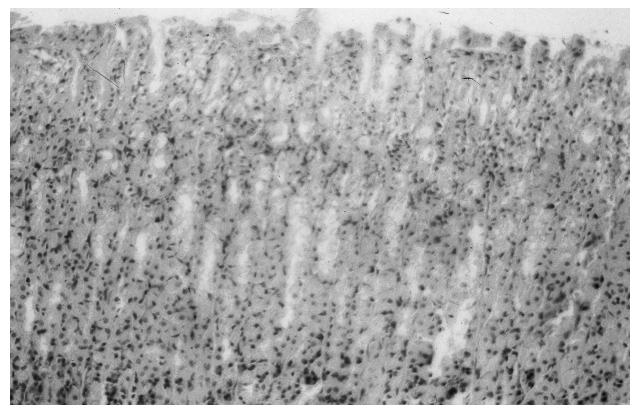


Figure 2. Gastric mucosa 30 days after exposure to 0.5 ppm F⁻ (H&E) (x200). (smc: surface mucous cells f: foveolae)

Macroscopic appearance of gross gastric specimens of 0.5, 5, and 50 ppm F- groups was normal.

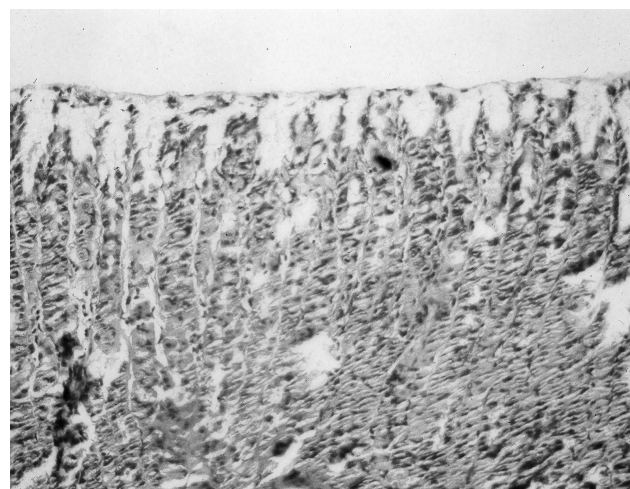


Figure 3. Gastric mucosa 30 days after exposure to 5 ppm F⁻ (H&E) (x200). (ml: mucus layer)

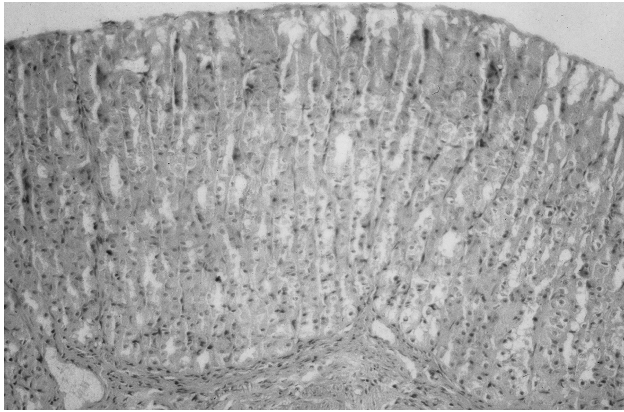


Figure 4. Gastric mucosa 30 days after exposure to 50 ppm F⁻ (H&E) (x200). (ml: mucus layer)

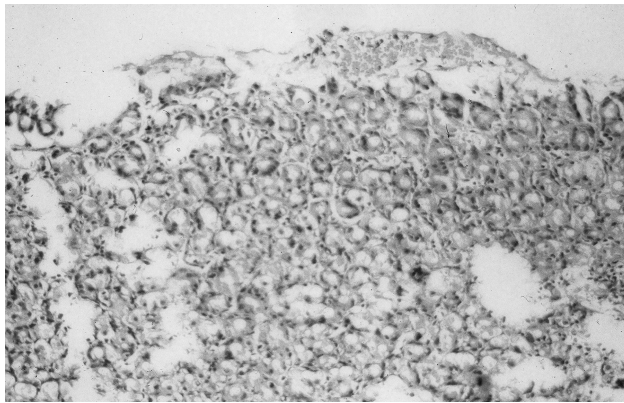


Figure 5. Gastric mucosa 12 h after exposure to 500 ppm F⁻ (H&E) (x200). (ea: erosion area h: haemorrhage)

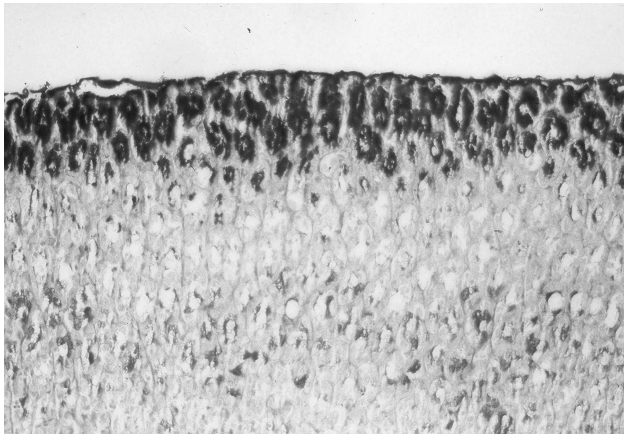


Figure 6. Control gastric mucosa (PAS) (x200). (ml: mucus layer)

(0.5 ppm F⁻) were the same with control group in light microscope (Figure 2). In Group III (5 ppm F⁻) minor changes were evident. Mucus layer loss on the luminal surface was observed. Mucous epithelial cells were columnar in shape but the gastric pits were evident (Figure 3). In group IV (50 ppm F⁻), structure of mucosa was normal and mucus layer was thicker than the sections from Group III (5 ppm F⁻) but thinner than in Group I (Figure 4). In Group V (500 ppm F⁻), in addition to loss of mucus, local erosion areas were observed in gastric mucosa sections (Figure 5).

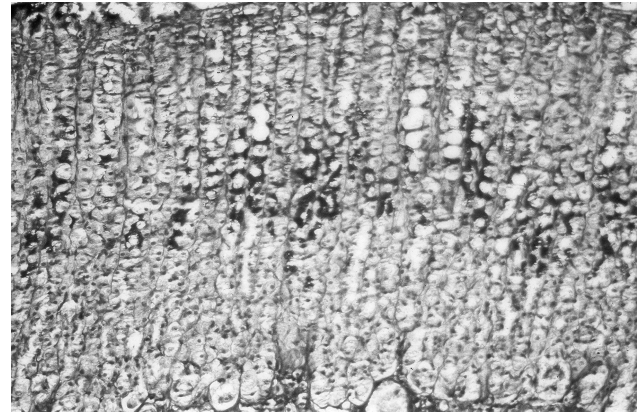


Figure 7. Gastric mucosa 12 h after exposure to 500 ppm F⁻ (PAS) (x200). (ml: mucus layer loss)

PAS Stain:

Intense PAS staining of the mucous epithelial cells on the luminal surface and around the gastric pits was observed in the sections of Group I (Figure 6). In Group II (0.5 ppm F⁻) sections corresponded to the H&E stain findings. In Group III (5 ppm F⁻) light to moderate destruction in mucous layer was seen where as in Group IV (50 ppm F⁻) mucous layer appearance was normal as in control group. In Group V (500 ppm F⁻) PAS stain demonstrated widespread loss of intracellular mucoïd material from surface mucous cells and within the gastric pits. Local cell desquamation and areas of moderate to severe hyperaemia or vascular congestion were observed (Figure 7). The most specific finding in high fluoride concentrations was mucus layer loss. The fluoride injury was limited in the luminal one-third of the mucosa. Fluoride damaged histological structure in gastric mucosa without causing any macroscopic injury.

DISCUSSION

The effects of fluoride on the structure and function of the gastric mucosa have been the subject of scientific investigations for over 30 years (1-4,6). Studies with several species of laboratory animals have shown that fluoride concentrations of only 95 ppm (5 mM/L) adversely affect the normal secretory and absorptive functions of the gastric mucosa. In studies using light and electron microscopy, the structure of the gastric mucosa of rats was found to be damaged in a dose- and time-related manner starting with fluoride concentrations as low as 190 ppm (10 mM/L). The damage ranged from vascular engorgement, haemorrhage, loss of the mucus layer, patchy desquamation of mucous cells and extensive loss of the mucosa including parietal and chief cells with exposure of the underlying lamina propria (950 ppm F or more). The threshold F concentration for effects on the structure and function of the gastric mucosa was approximately 19 ppm (6).

In the current study, the morphology of the injury in 0.5, 5, and 50 ppm F⁻ treated tissue at 30 days and 500 ppm F⁻ treated tissue at 12 h was investigated. The mucus layer injury was seen in 500 ppm F⁻ treated tissue. With young children, the amount of fluoride in dentifrices should be

reduced and the tooth brushing activity should be supervised to minimize the ingestion of fluoride to prevent any gastric stress or injury.

In 50 ppm F- treated gastric sections; the mucous loss was less than 5 ppm F- treated gastric sections. Since fluoride damage is dose-related, it was thought that mucus layer loss at that level in Group II was not fluoride-related. It thought to be caused by another factor such as contamination of the stomachs with any infectious material during the experiment. For statistical analysis, an arbitrary scale from gastric sections was designed by a pathologist. Since the scores of the sections obtained from the gastric specimens of the Groups were the same, correlation test among the Groups could not be performed.

Spak et al. used gastroscopic photography to report localized areas of haemorrhage in the gastric mucosa of their human subjects after they swallowed 10 ml of water containing 10 mg F (1000 ppm) (5). This study confirms data that fairly low fluoride concentrations of fluoride can damage the surface of the gastric mucosa.

The results of a study suggest that 19 ppm F- was without effect while 190 ppm F- caused exfoliation of surface mucous cells and 950 ppm F- produced extensive disruption of the mucosa with exposure of the basal lamina and lamina propria in some areas of rat gastric mucosa (2).

Fluoride is absorbed across cell membranes as hydrofluoric acid (HF), a weak acid. The stomach lumen is the most acidic environment in the body, secreting a fluid of approximately 0.1 N HCl. Thus, following fluoride ingestion the highest concentration of HF in the body is found in the stomach. The susceptibility of the surface mucous cells of the gastric mucosa may simply be due to their proximity to the lumen and resultant exposure to higher concentrations of fluoride (1). The present study was demonstrated by PAS staining that the mucus layer reduction was occurred and the mucous epithelial cells closest to the ingested fluoride were injured. Injury did not extend to the parietal cells and chief cells in the gastric glands. According to Easman et al., application of physiological concentrations of HCl results in some degeneration and desquamation of the interfoveolar surface mucous cells. This suggests that digestion constitutes a mild form of stress or injury. The fluoride

application produced a much greater degree of damage and cell loss (3). This study was designed of the application of fluoride without HCl resembling normal digestion conditions.

To be effective in reducing tooth decay, the level of natural fluoride in water in a temperate climate needs to be at or near 1 ppm. In addition to fluoride in drinking water, however, people also can ingest fluoride in toothpaste, mouth rinse, and dietary fluoride supplements or in beverages and foods prepared with fluoridated water. As a result, people might ingest more incidental fluoride than was anticipated (7). In 1994, World Health Organization (WHO) Expert Committee on the Use of Fluoride concluded that the optimum fluoride concentration will normally be within range 0.5-1.0 ppm to prevent cumulative effects of fluoride (8). According to the report of the WHO Subcommittee on Health Effects of Ingested Fluoride in 1993, the concentrations of fluoride in drinking water (0.7 ppm) in USA, are not likely to produce adverse effects on the GIS. But they noted that there have been few studies of the GIS effects of fluoride at low concentrations (9). In our study, therefore, the gastric effects of 0.5 ppm fluoride were investigated in Group I. Professionally applied fluorides like fluoride gels contain high concentrations of fluoride. Even small 5 mL volumes of 2 % NaF, 8 % SnF₂ and APF have 46, 98 and 62 mg fluoride, respectively, which exceed safely tolerated amounts in young children (10). Care usually is not taken by the dental practitioners to ensure these agents are handled properly especially among youngsters. Moreover, practitioners usually think that ingesting any fluoride not removed from the mouth during the application contributes to systemic effects of fluoride for having healthy teeth. Since the subsequent gastric injury is a risk we suggest that care should be taken by the dental practitioner when dental products which contain high concentrations of fluoride are used. We believed that it is essential to mark the ion in its compound form to state changes observed in soft tissues are specific for fluorine.

ACKNOWLEDGEMENT

The author thank to Murat Bülent ALKANAT, DDS, Ph.D., who passed away, for their kind assistance in review of the manuscript and data communications.

REFERENCES

1. Pashley DH, Allison NB, Easman RP, McKinney RV, Horner JA, Whitford GM. The effects of fluoride on the gastric mucosa of the rat. *J Oral Pathol* 1984; 13: 535-545.
2. Easman RP, Steiflik DE, Pashley DH, McKinney RV, Whitford GM. Surface changes in rat gastric mucosa induced by sodium fluoride: a scanning electron microscopic study. *J Oral Pathol* 1984; 13: 255-264.
3. Easman RP, Pashley DH, Birdsong NL, McKinney RV, Whitford GM. Recovery of rat gastric mucosa following single fluoride dosing. *J Oral Pathol* 1985; 14: 779-792.
4. Spak CJ, Sjöstedts G, Eleborg L, et al. Studies of human gastric mucosa after application of 0,42 % fluoride gel. *J Dent Res* 1990; 69: 426-429.
5. Spak CJ, Sjöstedts G, Eleborg L, et al. Tissue response of gastric mucosa after ingestion of fluoride. *Br Med J* 1989; 298: 1686-1687.

6. Whitford GM, Pashley DH, Garman RH. Effects of fluoride on structure and function of canine gastric mucosa. *Digestive Diseases and Sciences* 1997; 42: 2146-2155.
7. Health effects of ingested fluoride. Committee on Toxicology Board on Environmental Studies and Toxicology Commission on Life Sciences National Research Council National Academy press Washington DC 1993, p 87.
8. WHO Technical report series: fluorides and oral health. 1994; 16-19, Geneva .
9. European Commission-funded conference on the promotion of dental health at the European Parliament a discussion document 'Dental health in europe: A problem for disadvantaged groups' 1998; 27 19-2724, Brussels.
10. Whitford GM. Fluoride toxicology and health effects. In: Fejerskov O, Ekstrand J, Burt BA. *Fluoride in dentistry* Munksgaard: Boisen Print, 1996: 181-182.