

Ectopic thoracic kidney: a case report

Ektopik torasik böbrek: olgu sunumu

Yazıcı B Akgün A

Ege University Medical Faculty Department Of Nuclear Medicine

Summary

Thoracic ectopic kidney is a very rare developmental anomaly and the rarest form of all ectopic kidneys. We report a thoracic ectopic kidney in a 20 years old male.

Ultrasound examination and intravenous pyelography (IVP) revealed that no kidney was situated in the left renal region and pelvis. However, a left thoracic ectopic kidney was detected by renal scintigraphy easily.

Although it is extremely rare, the possible intrathoracic location of a kidney should be remembered when there is failure to demonstrate a kidney in the abdomen or pelvis.

Key words: *ectopic thoracic kidney, scintigraphy, Tc- 99m DMSA, Tc- 99m DTPA*

Özet

Torasik ektopik böbrek nadir görülen bir gelişimsel anomali olup tüm ektopik böbrekler içinde en az görülen formdur. 20 yaşında erkek hastada ultrasonografi ve intravenöz pyelografi ile sol renal lojda ve pelviste böbrek görülmedi.

Ancak, renal sintigrafiler ile solda ektopik torasik böbrek tespit edildi.

Çok nadir bir durum olmasına karşın batın ve pelviste böbrek görülmediğinde böbreğin intratorasik lokalizasyonda olabileceği hatırlanmalıdır.

Anahtar Kelimeler: *ektopik torasik böbrek, sintigrifi, Tc- 99m DMSA, Tc- 99m DTPA*

Introduction

Congenital thoracic ectopic kidney is a very rare developmental anomaly and the rarest form of all ectopic kidneys (1). It represents <5% of all patients of renal ectopia (2). It is usually asymptomatic and discovered incidentally on routine chest radiography. The most common differential diagnoses are: neoplasms of the lung and chest wall; mediastinal, subdiaphragmatic, and retroperitoneal tumors; infectious diseases; and diaphragmatic hernias and eventration of the diaphragm(3).

We present a patient with a left thoracic ectopic kidney and we hereby discuss the features of congenital thoracic ectopic kidney and review the literature. A 20 years old male, admitted to hospital with only a mild left lumbar pain.

Case Report

A subsequent ultrasound examination and intravenous pyelography (IVP) revealed that no kidney was situated in the left renal region and pelvis. Therefore, left renal agenesis was suspected because he has no history of nephrectomy. Technetium-99m dimercaptosuccinic acid (Tc- 99m DMSA) scintigraphy was obtained at the 3rd hour after intravenous injection of 5 mCi. Tc- 99m DMSA scintigraphy demonstrated that right kidney was in normal size and morphology. Static renal imaging showed thoracic ectopic kidney with normal renal parenchymal function (Figure 1). For the assessment of function and drainage of the thoracic ectopic left kidney, renal dynamic scintigraphy was performed after intravenous injection of 8 mCi of Tc- 99m diethylenetriaminepenta- acetic acid (DTPA).

Dynamic renal imaging showed adequate perfusion and normal function of the thoracic ectopic left kidney. No obstruction was observed (Figure 2).

Yazışma adresi: Bülent YAZICI, Ege Üniversitesi Tıp Fakültesi, Nükleer Tıp Anabilim Dalı, İZMİR
Makalenin geliş tarihi: 27.11.2006; kabul tarihi: 19.02.2007

Discussion

Unilateral thoracic (superior) renal ectopia is a rare anomaly. It denotes either a partial or complete protrusion of the kidney above the level of the diaphragm into the posterior mediastinum and it occurs more commonly in males and on the left side (4). In a series of 13000 autopsies, it represents < % 5 of all renal ectopies.

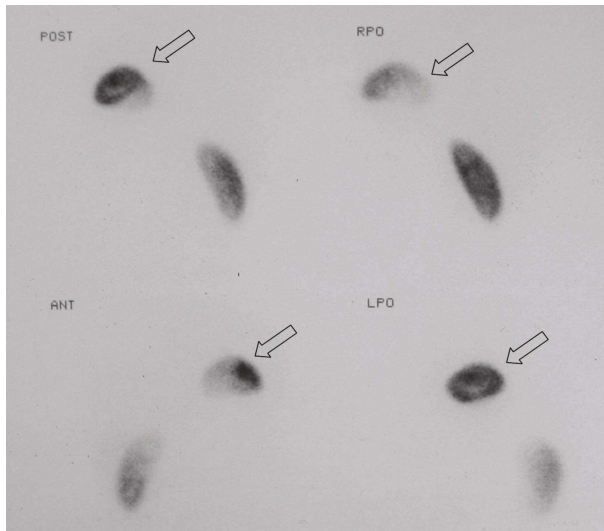


Figure 1. Tc-99m DMSA scintigraphy shows normal radiotracer uptake with smooth contours of the left intrathoracic kidney.

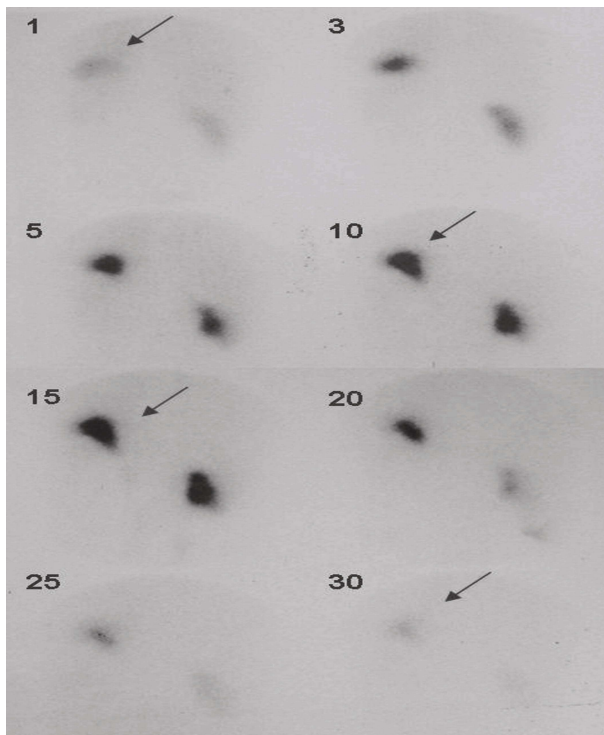


Figure 2. Dynamic Tc-99m DTPA imaging in the posterior position shows normal function and drainage of the left intrathoracic kidney.

On the other hand renal ectopy is a relatively common entity (1 of 900 patients) (2). Unlike pelvic ectopic kidneys, which sometimes are obstructed, have calculi or are infected, thoracic ectopic kidneys are usually normal and asymptomatic otherwise. Except for a few cases in which thoracic ectopic kidney was thought to be caused by traumatic diaphragmatic disruption, most thoracic renal ectopies are assumed to be congenital (5). In some cases anomalously superior origin of renal vessels had been found, whereas in some other cases renal vessels are longer than normal. The contour and collecting system of the thoracic kidneys are usually normal. The ureter is elongated. The renal arteries arise from either the normal or a more cranial portion of aorta. The protruding portion of the kidney is surrounded by a flimsy membrane, which separates the kidney from the pleural space. The adrenal gland is usually seen in its normal location, below the ectopic kidney (2).

Most cases are asymptomatic and discovered incidentally on routine chest radiography. But it may present as a thoracic mass on a routine chest roentgenogram. So it can be confused with other causes of thoracic mass like neoplasms of the lung - chest wall; mediastinal, subdiaphragmatic, and retroperitoneal tumors (3).

This problem can be solved by nuclear medicine methods easily.

Our patient with mild left lumbar pain underwent IVP and abdominal ultrasonography. These modalities reported a single kidney on the right side. Tc99m DMSA scintigraphy also demonstrated a normal right kidney however, a superior activity accumulation suggesting to be a left thoracic kidney was also observed. Tc-99m DTPA scintigraphy showed that the function of the thoracic ectopic left kidney was normal. No findings of obstruction were observed. The symptom of the patient may not be related to urinary system pathology according to the scintigraphic findings. There were not any pulmonary symptoms. Most intrathoracic kidneys remain asymptomatic and have a benign course. However, diagnosis of an intrathoracic kidney is important to prevent further unnecessary invasive investigations to diagnose an unknown intrapulmonary mass. These patients with ectopic thoracic kidney are usually followed in an out-patient clinic until a respiratory or a urinary complication is generated.

Tc- 99m DMSA is avidly taken up by cells of the proximal tubule, with about % 35 of the injected activity being localized in the renal cortex by one our. Renal uptake continues to rise about 6 hours, by which time about % 50 of the injected dose can be account for. On the other hand Tc-99m DTPA is a physiologically inert compound that diffuses rapidly into the extravascular space following intravenous injection. Then it is cleared from the plasma purely by glomerular filtration (6).

An ectopic thoracic kidney can be distinguished from other tissues easily by Tc- 99m DMSA and Tc- 99m DTPA scintigraphy as they are specific renal radiopharmaceuticals. So, the possible intrathoracic

location of a kidney should be remembered when there is failure to demonstrate a kidney in the abdomen-pelvis and renal scintigraphy must be performed.

References

1. Aydin HI, Sarici SU, Alpay F, Gokcay E. Thoracic ectopic kidney in a child: a case report. Turk J Pediatr. 2000 Jul - Sep; 42 (3): 253 - 5.
2. Stuart B. Bauer. Anomalies of the kidney and uretero-pelvic junction. Campbell's Urology, 7th Ed. 1998:1719 - 1720.
3. Yusuf K. Yalcinbas, Haluk Sasmaz, Suat Canbaz. Thoracic left kidney: a differential diagnostic dilemma for thoracic surgeons. Ann Thorac Surg 2001; 72 : 281 - 2835.
4. Panossian DH, Thomas RD, Anholm JD. Asymptomatic mediastinal mass in an elderly man. Chest 1995;107:1165-1166.
5. Lai CF, Chiang WC, Yang JY et al. Thoracic kidney and contralateral ureteral duplication- a case report and review of the literature. Nephrol Dial Transplant 2006; 21: 799 - 801.
6. Peter F. Sharp, Howard G. Gemmell, Alison D. Murray. Practical Nuclear Medicine, 3th Ed. 2005: 209 - 210.