

Successful bleeding control with intermittent injection of factor VIII in a patient with hemophilia A during coronary artery bypass grafting surgery

Hemofili A Tanılı hastada koroner arter By-pass operasyonunda aralıklı faktör VIII uygulaması ile başarılı kanama kontrolü

Şahin F¹ Engin Ç² Yağdı T² Saydam G¹

¹Ege Üniversitesi, İç Hastalıkları Anabilim Dalı-Hematoloji Bilim Dalı, İzmir, Türkiye

²Ege Üniversitesi, Kalp ve Damar Cerrahisi Anabilim Dalı, İzmir, Türkiye

Summary

Coronary surgery in patients with hemophilia is a challenging issue since it requires specific and a careful medical approach before, during and after the operation. Although several studies have shown the effectiveness of either intermittent or continuous infusion of factor VIII concentrates, there are no standardized schedules for the replacement therapy in these kinds of patients. We hereby present a case of severe hemophilia A and coronary event which was successfully managed by surgical approach supported by intermittent high dose factor VIII infusion. The patient underwent a surgical by-pass operation without any hemorrhagic and thrombotic complications..

Key Words: factor replacement, coronary surgery, hemophilia.

Özet

Hemofili hastalarında koroner cerrahi, operasyon öncesi, operasyon sırası ve sonrasında özel ve dikkatli tıbbi yaklaşım gerektirmektedir. Aralıklı veya sürekli faktör VIII infüzyonu uygulamalarının etkinlikleri açısından birkaç çalışma olmakla birlikte bu konuda net protokoller ortaya konabilmiş değildir. Burada ağır hemofili A tanısı ve koroner hastalığı olan ve aralıklı yüksek doz faktör VIII infüzyonları ile başarılı bir operasyon geçiren bir hastayı sunmaktayız. By-pass operasyonu geçiren hastada kanama ve trombotik komplikasyon izlenmemiştir..

Anahtar Sözcükler: Faktör replasmanı, koroner cerrahi, hemofili.

Introduction

Haemophilia A is a sex-linked recessive inherited disease. The incidence of haemophilia A is 1 per 10,000-20,000 males. Females are involved as carriers. Spontaneous bleeding may occur mainly at the joints resulting in haemophilic arthropathy in severe and moderate patients (1). Factor replacement treatment has allowed haemophilia patients to live longer in the last decades. Co-morbid events, such as coronary artery disease (CAD), cancer, diabetes, hypertension (HT), increase with age in haemophilic patients as in the non haemophilic population (2).

Although it is rare, it is possible to detect coronary artery stenosis in hemophilic patients and some of these conditions may require surgical intervention. However there is limited published experience about usage of factor replacement in haemophilia patients requiring coronary bypass surgery. We here in report a 50-year-old male haemophilia A patient with CAD, HT and hyperlipidemia who underwent successful coronary artery bypass graft (CABG) surgery with intermittent high purity factor VIII replacement throughout the pre-operative, and post-operative period.

Case Report

A 50 year-old male hemophilic patient had complaints of angina pectoris for three months. In his childhood severe Haemophilia A (Factor VIII <1%) was diagnosed

Yazışma Adresi: Fahri ŞAHİN

Ege Üniversitesi, İç Hastalıkları Anabilim Dalı-Hematoloji Bilim Dalı, İzmir, Türkiye

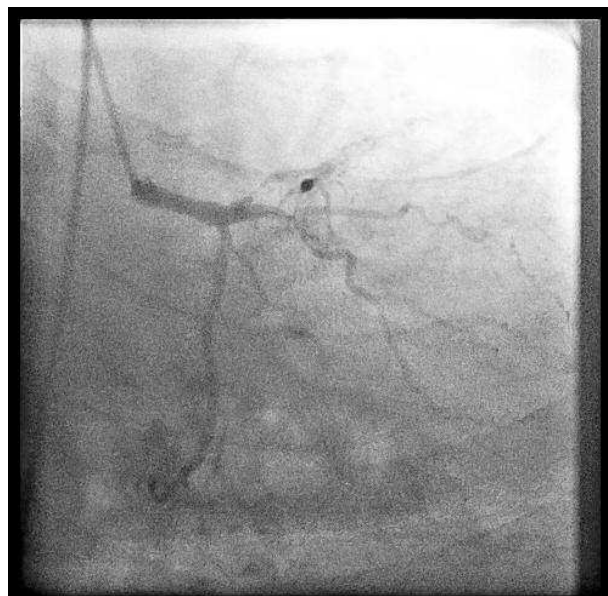Makalenin Geliş Tarihi: 03.03.2010 Kabul Tarihi: 13.04.2010

after a circumcision operation and ever since he experienced regular bleeding with haemophiliac arthropathy. He was additionally diagnosed with hypertension, hyperlipidemia and penicillin allergy. He smoked heavily for 20 years. The patient had complaints of increased fatigue and chest pain for 3 months, increased coughing or orthophnea, and angina pectoris.

He was hospitalized in the cardiology department. Laboratory studies showed that an activated partial thromboplastin time (aPTT) of 59 seconds and inhibitor of factor VIII was negative. Coronary angiography was performed after high purity factor VIII replacement. One hour prior to cardiac catheterization, the patient received 3000U of factor VIII.

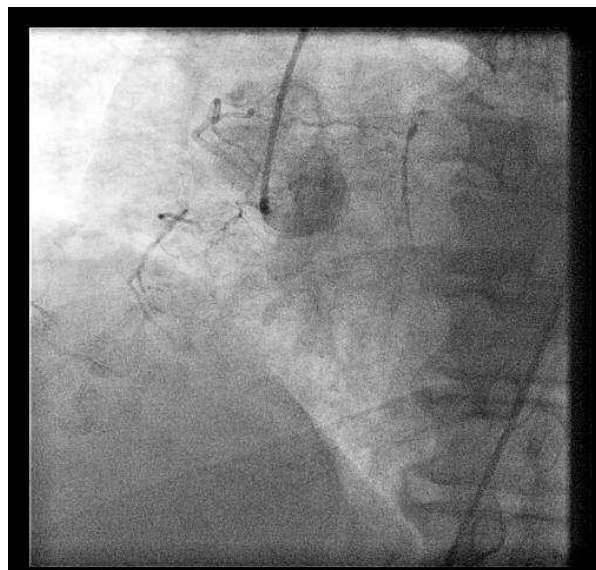
Angiography revealed a moderate left ventricular ejection fraction (LVEF: 60%) with two occluded coronary arteries. The mid segment of left anterior descending artery (LAD) was critically stenotic up to 90% (Figure-1). The proximal segment of the right coronary artery was totally stenotic (Figure-2).

Figure 1. The mid segment of the left anterior descending artery (LAD) was critically stenotic up to 90%.



Surgery was scheduled and off-pump procedure was performed to prevent excessive bleeding and avoid cardiopulmonary bypass induced coagulation disorders. In the morning one hour prior to surgery 3000U of high purity factor VIII were given as bolus infusion and aPTT was measured 23.3 sec (22.5-31.3) after replacement. Before connecting the patient to the cardiopulmonary pump machine a bolus of 3000 U of factor VIII was given. The operation procedures were performed as are in a non-haemophiliac patient.

Figure 2. Total stenosis at the proximal segment of right coronary artery.



Standard heparinization was performed during cardiac by-pass and reversal with protamine sulphate. When detaching the patient from the cardiopulmonary pump machine, 2000 U of factor VIII was given as bolus. After the operation, 3000 U of factor VIII was given every 12 hours for two days in the follow up period. After the second day, 2000 U of factor VIII was given every 12 hours for 4 days. In this way we aimed to keep aPTT below 30 sec. At the post operative 7th day, we decreased the dosage of factor VIII from 2000 U to 1000 U twice a day. At the post operative 13th day we dropped factor VIII dosage to half; 500 U twice a day (Table-1).

Table 1. Daily total dosage of factor VIII and evaluation of aPTT during the postoperative period.

Day	aPTT	FVIII dosage (daily)
Post-op 0	25	6000 U
1	151	6000 U
2	32	4000 U
3	30	4000 U
4		4000 U
5	34	4000 U
6	24	4000 U
7		2000 U
8	22	2000 U
9	18	2000 U
10		2000 U
11		2000 U
12		2000 U
13	24,7	1000 U
14		1000 U

(aPTT: activated partial thromboplastine time, U: unit)

Aspirin was given as secondary prophylaxis against ischemic coronary events. Indeed the literature emphasizes the dangers of aspirin therapy in patients with severe hemophilia (3-5), there was no bleeding complication. The patient was discharged on the 14th postoperative day with a healthy status without any hemorrhagic or thrombotic complications.

Discussion

Coronary heart disease is a prominent cause of morbidity and mortality in our country as in the rest of the world. The relationship between coagulation factors and coronary heart disease, in particular ischaemic heart disease has also been studied. The prevalence and mortality of ischaemic heart disease in hemophilic patients is lower than in the normal population. Elevated factor VIII levels may cause ischaemic heart disease (6-8).

Bleeding problems are controlled more effectively with advancements in the technology of factor VIII, IX and after a high purity factor and recombinant factor came into use. Additionally, degenerative cardiac disease and coronary heart disease increased in the haemophilic population due to life expectancy currently estimated to be between 60 and 70 years (5). The current literature contains a number of case report, relating a variety of cardiac surgical procedures in haemophilia A and B (2, 9-12). One describes 12 procedures performed in seven patients (6 of Haemophilia A and 1 of haemophilia B)

reporting successful cardiac catheterization and surgical experience in patients with haemophilia (5).

There are some articles reporting effective coronary surgery both after bolus injection and continuous infusion. Most studies claimed that cost benefits for continuous infusion were based on historical controls. A few studies claim no difference in factor VIII consumption between continuous infusion and intermittent bolus infusion (13). Batorova and Martinowitz pointed out that continuous infusion is more safe and cost effective in surgical procedures. (14). However, there are no standards for the protocol of factor substitution. We preferred intermittent bolus infusion of Factor VIII since we have more experience with this protocol. We followed the effectiveness of therapy with aPTT and we did not encounter any bleeding complications before or after surgery.

Our case demonstrates that major cardiac surgery can be performed with intermittent injection of factor safely in patients with haemophilia. Major cardiac surgery is more dangerous in haemophilic patients because of a high risk of perioperative complications and haemorrhagic situation and there is limited solid data. But it is possible to have successful outcomes in hemophilic patients with careful monitoring and adequate factor replacement. It should be emphasized that the number of hemophilic patients with coronary events eventually needing a surgical approach will grow effective with replacement therapy. For this reason, standardized procedures based on further prospective trials are necessary.

References

1. Friedman KD and Rodgers GM. Coagulation disorders. In: Greer JP, Foerster J, Lukens JN, Rodgers GM, Paraskevas F, Glader B (eds) *Wintrobe's Clinical Hematology*, Lippincott Williams & Wilkins, Philadelphia, 2004: 1619–1667.
2. Stine KC, Becton DL: Use of factor VIII replacement during open heart surgery in a patient with haemophilia A. *Haemophilia*. 2006; 12(4):435-6.
3. Quick AJ: No aspirin for Haemophiliacs. *NEJM* 1971; 284(4):218.
4. Mielke CH & Britten AFH. Use of aspirin or acetaminophen in Haemophilia. *NEJM* 1970; 282 (22):1270.
5. MacKinlay N, Taper J, Renisson F, Rickard K. Cardiac surgery and catheterization in patients with haemophilia. *Haemophilia*. 2000;6(2):84-8.
6. Sramek A, Kriek M, Rosendaal FR. Decreased mortality of ischaemic heart disease among carriers of haemophilia. *Lancet* 2003;362:351-4.
7. Rosendaal FR, Vrekeamp I, Smit C, Bröcker-Vriends AH, van Dijck H, Vandenbroucke JP, Hermans J, Suurmeijer TP, Briët E. Mortality and causes of death in Dutch haemophiliacs, 1973-86. *Br J Haematol* 1989;71:71-6.
8. Meade TW, Cooper JA, Stirling Y, Howarth DJ, Ruddock V, Miller GJ. Factor VIII, ABO blood group and the incidence of ischaemic heart disease. *Br J Haematol* 1994; 88:601-7.
9. Eren A, Friedl R, Hannekum A, Gulbins H. Cardiac surgery in a patient with haemophilia A. *Thorac Cardiovasc Surg*. 2006;54(3):212-4.
10. Grandmougin D, Delolme MC, Reynaud J, Barral X. Off-pump myocardial revascularization in a diabetic patient with severe haemophilia B and impaired left ventricular function: hematological and operative strategies. *J Card Surg*. 2005;20(4):366-9.
11. Leggett PL, Doyle D, Smith WB, Culpepper W 3rd, Cooper S, Ochsner JL. Elective cardiac operation in a patient with severe haemophilia and acquired factor VIII antibodies. *J Thorac Cardiovasc Surg*. 1984;87(4):556-60.
12. Palanzo DA, Sadr FS. Coronary artery bypass grafting in a patient with haemophilia B. *Perfusion*. 1995;10(4):265-70.
13. Ferrario C, Renders F, Cairoli A, Vuffray A, Spertini O, Angelillo-Scherrer A. Management of an acute coronary syndrome in a patient with severe haemophilia A. *Haemophilia* 2007; 13: 763–765.
14. Batorova A, Martinowitz U. Intermittent injections vs. continuous infusion of factor VIII in haemophilia patients undergoing major surgery. *Br J Haematol*. 2000;110(3):715-20.