

A case of hemophagocytic syndrome that presented as fulminant hepatic failure

Fulminan hepatik yetmezlikle başvuran hemofagositik sendromlu bir olgu

Gülen H¹ Aslan Ş² Şimşek A² Ayhan S³ Moumin N² Kasırğa E⁴

¹Celal Bayar Üniversitesi Tıp Fakültesi, Pediatrik Hematoloji Bilim Dalı, Manisa, Türkiye

²Celal Bayar Üniversitesi Tıp Fakültesi, Çocuk Sağlığı ve Hastalıkları Anabilim Dalı, Manisa, Türkiye

³Celal Bayar Üniversitesi Tıp Fakültesi, Patoloji Anabilim Dalı, Manisa, Türkiye

⁴Celal Bayar Üniversitesi Tıp Fakültesi, Pediatrik Gastroenteroloji Bilim Dalı, Manisa, Türkiye

Summary

Hemophagocytic lymphohistiocytosis (HLH) is an uncommon clinical entity characterized by fever, pancytopenia, hepatosplenomegaly and hemophagocytosis in bone marrow, liver or lymph nodes. Fulminant hepatic failure (FHF) is a clinical syndrome resulting from massive necrosis of hepatocytes or severe functional impairment of hepatocytes in a patient who does not have a pre-existing liver disease. Hepatic manifestations are common in hemophagocytic lymphohistiocytosis and overt hepatic failure may occur, but initial presentation as fulminant hepatic failure is not well recognized. We report the case of a 9 year old girl presented with fulminant hepatic failure and "Hemophagocytic lymphohistiocytosis" should be considered in the differential diagnosis of fulminant hepatic failure in children.

Key words: Hemophagocytic lymphohistiocytosis; fulminant hepatic failure, child.

Özet

Hemofagositik lenfositosis, ateş, pansitopeni, hepatosplenomegali ve kemik iliği, karaciğer ya da lenf nodları gibi doku ve organlarda hemofagositizmle karakterize nadir görülen bir klinik tablodur. Ağır karaciğer yetmezliği ise önceden bilinen karaciğer hastalığı olmayan kişilerde hepatositlerin masif nekrozu ya da ağır fonksiyon kaybına bağlı gelişen klinik bir hastalık tablosudur. Hemofagositik lenfositisizmde karaciğer tutulumuna ait bulgular yaygın olarak görülmekte ve hastalığın seyrinde karaciğer yetmezliği tablosu da olabilmektedir. Ancak hastalığın ağır karaciğer yetmezliği tablosuyla başlaması çok iyi tanımlanmamıştır. Burada ağır karaciğer yetmezliği tablosuyla başvuran 9 yaşında bir kız olgu sunulmakta ve çocuklarda ağır karaciğer yetmezliğinin ayırıcı tanısında hemofagositik lenfositisizminin da düşünülmesi gerektiği vurgulanmaktadır.

Anahtar kelimeler: Hemofagositik lenfositisizm; fulminan karaciğer yetmezliği, çocuk.

Introduction

Hemophagocytic lymphohistiocytosis (HLH) is an uncommon clinical entity characterized by fever, pancytopenia, hepatosplenomegaly and hemophagocytosis in the bone marrow, liver or lymph nodes (1). A major factor causing the manifestations of HLH might be an acquired dysregulation of T lymphocytes and natural killer cells resulting in excessive activation of hemophagocytic monocytes (1-3).

The clinical course of HLH is usually severe and life-threatening and immediate initiation of therapy is mandatory (4). Awareness of the clinical symptoms and diagnostic criteria of HLH is important to start life-saving therapy with immunosuppressive/immunomodulatory agents in time (5). Fulminant hepatic failure (FHF) is a clinical syndrome resulting from massive necrosis of hepatocytes or severe functional impairment of hepatocytes in a patient who does not have a pre-existing liver disease (6). Hepatic manifestations are common in HLH and overt hepatic failure may occur, but initial presentation as FHF is not well recognized (7). Here we present a case that was admitted our hospital with FHF and was diagnosed as HLH.

Yazışma Adresi: Hüseyin GÜLEN

Celal Bayar Üniversitesi Tıp Fakültesi Çocuk Sağlığı ve Hastalıkları Anabilim Dalı, Manisa, Türkiye

Makalenin Geliş Tarihi: 04.03.2010 Kabul Tarihi: 17.05.2010

Case Report

The patient, a 9-year-old girl, was previously healthy. Her complaints had begun 15 days prior to admission. She presented with fever, jaundice, abdominal pain, vomiting and melena. Physical examination revealed lethargy, jaundice of sclera and skin, massive hepatomegaly (9 cm below the costal margin). On her neurologic examination, she was oriented and cooperative but lethargic. Bilateral pupillary light reflexes were positive, bilateral pupils were isochoric. Cranial nerves were intact and deep tendon reflexes were normal. Laboratory studies revealed mild anemia with bicytopenia (hemoglobin level of 11.1 g/dl, haematocrit was 33.9%; white blood cell count of 4.000/mm³ with absolute neutrophil count 370/mm³ and platelet count of 101.000/mm³), markedly elevated serum aminotransferase activities and bilirubin levels (the serum aspartate aminotransferase (AST) level was 2275 U/L, the alanine aminotransferase (ALT) was 1281 U/L, the total bilirubin level was 5.18 mg/dl and the direct bilirubin level was 3.39 mg/dl). There were no hypoglycemia, electrolyte imbalance or acid-base disturbances. Prothrombin time (25 sec) and activated partial thromboplastin time (69.6 sec) were prolonged. Total protein (5.8 g/dl) and albumin (3.1 g/dl) values were decreased. The plasma fibrinogen level (156.5 mg/dl) was decreased, cholesterol (266 mg/dl), triglycerid (567 mg/dl), ferritin levels (>2000 ng/ml) and blood ammonia concentration (156 µg/dl) were elevated. In abdominal ultrasonography, there was hepatomegaly with decreased paranchymal echogenicity and ascitic fluid. The patient, with her clinical and laboratory findings were evaluated having FHF and supportive treatment was started immediately. In order to establish the etiology, viral serology, metabolic tests and autoantibodies were studied but they were all negative. There was no history of drug or chemical use. Since there was coexistence of hepatomegaly, bicytopenia, hypercholesterolemia, hypofibrinogenemia and markedly elevated ferritin level, bone marrow aspiration was performed to differentiate hemophagocytic syndrome. Evaluation of the bone marrow aspiration revealed hemophagocytosis with increased macrophages (Figure-1). There were neither storage cells nor blastic infiltration. In the liver biopsy, (Figure-2) a mild increase of mononuclear cells at portal areas and cholestasis were found. Molecular analyses excluded a mutation of the perforin gene (PRF 1).

With the clinical, laboratory and histopathological findings our patient was diagnosed with HLH presenting as FHF. In addition to her supportive treatment, HLH-2004 treatment protocol was started and the etoposid

dose was adjusted because of hepatic failure. In the second month of treatment, her hepatomegaly was 2 cm, complete blood count was within normal limits, the other laboratory findings were as follows; AST 120 U/L, ALT 89 U/L, total bilirubin 1.13 mg/dl, direct bilirubin 0.47mg/dl, total protein 8.0 g/dl, albumin 4.0 g/dl, GGT 71 U/L, ferritin 437.1 ng/ml. Currently, 24 months after the treatment ceased, the patient is doing well with completely normal physical examination and laboratory findings. The patient needs no more medication.

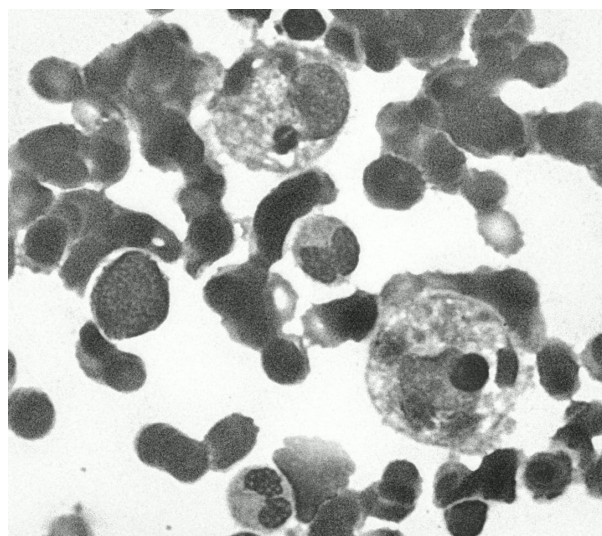


Figure-1. Bone marrow smear showing hemophagocytosis with increased macrophages (x100, Wright stain).

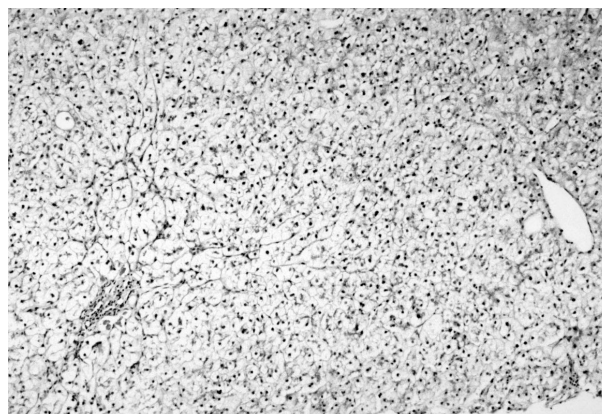


Figure-2. Liver biopsy with mild increase of mononuclear cells at portal areas and cholestasis (x10, HE).

Discussion

Hemophagocytic syndromes are reactive disorders of the mononuclear phagocytic system. They represent a spectrum of inherited and acquired conditions with disturbed immune regulation of different severities. There are two distinct forms of HLH classified as primary

and secondary. The primary form is an inherited autosomal recessive form, also termed as familial hemophagocytic lymphohistiocytosis (FHL), which usually occurs in the first years of life and is fatal when untreated. Secondary or acquired HLH is associated with a variety of underlying diseases including infections, malignancies and autoimmune diseases (2, 4, 8). Common findings include fever, hepatosplenomegaly, pancytopenia, hypertriglyceridemia, hypofibrinogenemia, elevated ferritin levels and reduced cytotoxic T- and natural killer (NK)-cell activity, as well as a widespread accumulation of T lymphocytes and macrophages, some of which may engage in hemophagocytosis (9). Histologically, an accumulation of non-malignant lymphocytes and macrophages [most typically with hemophagocytosis] is evident in the mononuclear phagocyte system (10). A hypercytokinemia, mainly involving proinflammatory cytokines, mediates the clinical and laboratory findings (9, 11). Diagnosis is made based on clinical, laboratory and histological criteria. These criterias include 1) Fever, 2) Splenomegaly, 3) Cytopenias affecting at least two of three lineages in the peripheral blood, 4) Hypertriglyceridemia and/or hypofibrinogenemia, 5) Hemophagocytosis in bone marrow, spleen, or lymph nodes, 6) Low or absent NK-cell activity, 7) Hyperferritinemia, and 8) High levels of sIL-2r. Five out of eight criteria must be fulfilled. In the present case there were fever, cytopenia, hypertriglyceridemia, hypofibrinogenemia, hemophagocytosis in bone marrow and the ferritin level was ≥ 500 .

FHL is genetically heterogenous and may result from mutations in PRF1, the gene encoding perforin, mutations in UNC13D, the gene encoding the lytic granule priming factor hMunc13-4 and STX11 on chromosome 6q24 encoding a protein, syntaxin 11, which is postulated to play a role in intracellular trafficking. The last factor is common in Turkish patients (8,12). Perforin expression in NK cells and cytotoxic lymphocytes measured by flow cytometry have proven to be of value in identifying patients with mutations in the perforin gene and should be performed in all patients (2). In our case, molecular analyses excluded a mutation of the PRF1 gene. However, UNC13D and STX11 mutations could not be tested.

FHF is a rare but highly mortal disease in childhood and characterized by progressive jaundice, hemorrhagic diathesis, neuromuscular and behavioural abnormalities and hyperammonemia. FHF implies that some agent or combination of agents has caused the sudden death of or severe injury to a large proportion of hepatocytes, leaving less parenchymal function than is needed to sustain life. The lack of preexisting liver disease is an important component of the FHF. It is most commonly a

complication of viral hepatitis, but may also be caused by autoimmune hepatitis. Various hepatotoxic drugs, chemicals and metabolic disorders may also cause fulminant hepatic failure. The liver can be involved directly, by infiltration, and indirectly--by remote effects--in the histiocytoses of childhood (13), but initial presentation as FHF is not well recognized (7, 14, 15). Commonly, HLH causes chronic hepatic dysfunction, and a histological picture similar to chronic persistent hepatitis is commonly found (8). An important diagnostic pointer in liver specimens may be portal tract infiltration by T lymphocytes and histiocytes, resembling chronic hepatitis (15).

Our case was admitted in the clinical picture of FHF and there was no evidence of chronic liver disease. Histopathologic examination of liver biopsy samples showed portal tract infiltration by mononuclear cells and cholestasis.

It is known that splenomegaly is a striking clinical feature of HLH. However, interestingly in our case, the spleen was not palpable. On the contrary, the primary targets in our case were the liver and bone marrow.

Outcomes for children with FHF vary depending upon the etiology and degree of central nervous system involvement. Management is supportive and overall mortality exceeds 70%. On the other hand, the clinical course of HLH is usually severe and life-threatening and immediate initiation of therapy is mandatory. Treatment aims to suppress the severe hyperinflammation by chemoimmunotherapy including corticosteroids, cyclosporine A and/or etoposide (2, 4, 8). In 1994, the Histiocyte Society developed a treatment strategy (HLH-94) that combines (rather than randomizes between) two previously reported regimens: chemotherapy and immunotherapy. HLH-94 is based on VP-16, corticosteroids, CSA, and, in selected patients, IT MTX, prior to intended BMT (9). Our case was treated with HLH-2004 protocol. Currently, she is completely normal and needs no more medication.

Conclusion

In conclusion, HLH should be considered in differential diagnosis of FHF. It is important to remember that hemophagocytic syndromes can lead to severe liver damage. And awareness of the clinical symptoms and diagnostic criteria of HLH is also important to start life-saving therapy with immunosuppressive/immunomodulatory agents in time.

Acknowledgments

We are grateful to Prof. Dr. Aytemiz Gürgey [Department of Pediatric Hematology, Hacettepe University, Ankara] for molecular analyses of perforin mutation.

References

1. Fisman DN. Hemophagocytic syndromes and infection. *Emerg Infect Dis* 2000;6: 601-608.
2. Janka GE, Schneider EM. Modern management of children with haemophagocytic lymphohistiocytosis. *Br J Haematol* 2004; 124: 4-14.
3. Schneider EM, Lorenz I, Walther P, Janka GE. Natural killer deficiency: a minor or major factor in the manifestation of hemophagocytic lymphohistiocytosis? *J Pediatr Hematol Oncol* 2003; 25: 680-683.
4. Lackner H, Urban C, Sovinz P, Benesch M, Moser A, Schwinger W. Hemophagocytic lymphohistiocytosis as severe adverse event of antineoplastic treatment in children. *Haematologica* 2008; 93[2]: 291-294.
5. Janka GE. Hemophagocytic syndromes. *Blood Rev* 2007; 21(5): 245-253.
6. Lee WM, Squires RH Jr, Nyberg SL, Doo E, Hoofnagle JH. Acute liver failure: Summary of a workshop. *Hepatology* 2008; 47(4): 1401-15.
7. Parizhskaya M, Reyes J, Jaffe R. Hemophagocytic syndrome presenting as acute hepatic failure in two infants: clinical overlap with neonatal hemochromatosis. *Pediatr Dev Pathol* 1999; 2(4): 360-366.
8. Henter JI, Horne A, Aricó M, Egeler RM, Filipovich AH, Imashuku S, Ladisch S, McClain K, Webb D, Winiarski J, Janka G. HLH-2004: Diagnostic and therapeutic guidelines for hemophagocytic lymphohistiocytosis. *Pediatr Blood Cancer* 2007; 48: 124-31.
9. Henter JI, Samuelsson-Horne A, Aricó M, Egeler RM, Elinder G, Filipovich AH, Gadner H, Imashuku S, Komp D, Ladisch S, Webb D, Janka G; Histocyte Society. Treatment of hemophagocytic lymphohistiocytosis with HLH-94 immunochemotherapy and bone marrow transplantation. *Blood* 2002; 100: 2367-2373
10. Henter JI, Elinder G, Soder O, Hansson M, Andersson B, Andersson U. Hypercytokinemia in familial hemophagocytic lymphohistiocytosis. *Blood* 1991; 78: 2918-2922.
11. Arico M, Danesino C, Pende D, Moretta L. Pathogenesis of haemophagocytic lymphohistiocytosis. *Br J Haematol* 2001; 114: 761-769
12. Horne A, Ramme KG, Rudd E, Zheng C, Wali Y, al-Lamki Z, Gurgey A, Yalman N, Nordenskjöld M, Henter JI. Characterization of PRF1, STX11 and UNC13D genotype-phenotype correlations in familial hemophagocytic lymphohistiocytosis. *Br J Haematol* 2008 ;143(1):75-83.
13. Jaffe R. Liver involvement in the histiocytic disorders of childhood. *Pediatr Dev Pathol* 2004; 7(3): 214-25.
14. Favara BE. Histopathology of the liver in histiocytosis syndromes. *Pediatr Pathol Lab Med* 1996;16:413-433.
15. Kapelari K, Fruehwirth M, Heitger A, Königsrainer A, Margreiter R, Simma B, Offner FA. Loss of intrahepatic bile ducts: an important feature of familial hemophagocytic lymphohistiocytosis. *Virchows Arch* 2005; 446: 619-625