

Scintigraphic evaluation of hepatic hydrothorax

Hepatik hidrotoraksta sintigrafik değerlendirme

Cengiz A Şakı H Yürekli Y

Adnan Menderes University, Faculty of Medicine, Department of Nuclear Medicine, Aydın, Turkey

Summary

Hepatic hydrothorax is defined as the accumulation of significant pleural effusion (usually >500 ml) in a cirrhotic patient without primary pulmonary or cardiac disease. Hepatic hydrothorax affects 4%-10% of patients with cirrhosis. The pleural effusion is usually right sided, but may be bilateral or left sided. Direct migration of ascitic fluid via a diaphragmatic defect or lymphatic channels can cause leakage of fluid into the pleural space. Imaging of the chest and diagnostic thoracentesis should be performed in patients with cirrhosis and pleural effusion. Demonstration of communication between the peritoneal and pleural space can be made by intraperitoneal injection of air, dyes and radionuclides. Noninvasive peritoneal scintigraphy should be preferred for its simplicity and high diagnostic sensitivity. Here, we present a case with cirrhosis and pleural effusion which had been evaluated by peritoneal scintigraphy for the evaluation of peritoneopleural communication.

Key Words: Hydrothorax, radionuclide imaging, pleural effusion.

Özet

Hepatik hidrotoraks, primer kardiyak veya pulmoner hastalık olmaksızın sirozlu bir hastada önemli miktarda (genellikle 500 ml'den fazla) plöral sıvı birikmesidir. Hepatik hidrotoraks, sirozlu hastaların %4-%10'unu etkiler. Plöral efüzyon genellikle sağda olmakla birlikte solda veya bilateral olabilir. Asit sıvısının diafragmadaki defektler veya lenfatikler yoluyla geçişi, plöral alanda sıvı birikimine neden olabilir. Plöral efüzyonu olan sirozlu bir hastada göğüs bölgesinin görüntülenmesi ve diagnostik torasentez yapılmalıdır. Peritoneal ve plöral boşluklar arasındaki geçişin gösterilmesi, boyalar, hava ve radyonüklitlerin intraperitoneal enjeksiyonu ile yapılabilir. İnvaziv olmayan peritoneal sintigrafi, kolaylığı ve yüksek tanısal duyarlılığı nedeniyle tercih edilmelidir. Burada, peritoneaoplöral geçişi peritoneal sintigrafi ile değerlendirilen, sirozu ve plöral efüzyonu olan bir hastayı sunuyoruz.

Anahtar Sözcükler: Hidrotoraks, radyonüklid görüntüleme, plevral efüzyon.

Introduction

Hepatic hydrothorax is defined as the collection of fluid (usually >500 ml) in the pleural space in a cirrhotic patient without primary pulmonary or cardiac disease (1). Hepatic hydrothorax is diagnosed in 4%-10% of patients with cirrhosis (2). The pleural fluid accumulation associated with cirrhosis is usually right sided (66%), but may be bilateral (17%) or left sided (17%). Passage of ascitic fluid from the peritoneal cavity to the pleural space via lymphatic channels in the diaphragm or through congenital/acquired diaphragmatic defects have been reported to cause pleural effusion (2).

Patients with hepatic hydrothorax may present with different pulmonary symptoms ranging from mild exercise intolerance to severe respiratory failure. The development of spontaneous bacterial peritonitis is a frequent complication in cirrhotic patients and communication between the abdominal ascitic fluid and pleural space may lead to thoracic bacterial pleuritis or spontaneous bacterial empyema (3)

Many diagnostic methods, including biochemical analysis, conventional radiography, thoracoscopy, ultrasonography and magnetic resonance imaging have been suggested for diagnosis of hepatic hydrothorax. Scintigraphy has also been reported to be a simple and safe technique to demonstrate the transdiaphragmatic passage of ascitic fluid (4,5). Here, we present a case of a patient with cirrhosis and pleural effusion who had been evaluated with peritoneal scintigraphy to demonstrate the peritoneo-pleural communication.

Corresponding Author: Arzu CENGİZ

Adnan Menderes University, Faculty of Medicine, Department of Nuclear Medicine, Aydın, Turkey

Received: November 26, 2012 Accepted: February 1, 2013

Case Report

An 81-year-old female patient who suffered from dyspnea was referred to our hospital. She had a history of hepatitis B for 25 years and cirrhosis for eight years. The patient had a history of a diagnosis of hepatic hydrothorax and two pleurodesis for treatment. Chest radiography and computerized tomography showed pleural effusion on the right hemithorax. A high volume of liquid (2000 cc/day) was drained from pleural space after insertion of a small-calibre catheter. The patient was diagnosed as having recurrent hepatic hydrothorax with incomplete pleurodesis with talc. Peritoneal scintigraphy was performed to view the transition pattern of ascitic fluid to the right hemithorax. Peritoneal scintigraphy was performed after an intra-peritoneal injection of 5 mCi Tc99m DTPA and posterior serial 5-minute planar images were obtained over a 30-minute period. Lateral planar images of thorax and the upper part of the abdomen were also acquired. Accumulation of activity in the right pleural space was observed on the early images (within first 10 minutes of the study (Figure-1). Because of pleurodesis, distribution of a radiotracer was not concordant with normal pleural anatomy. A subsequent scintigraphy, and operation were planned and diaphragmoplasty was performed.

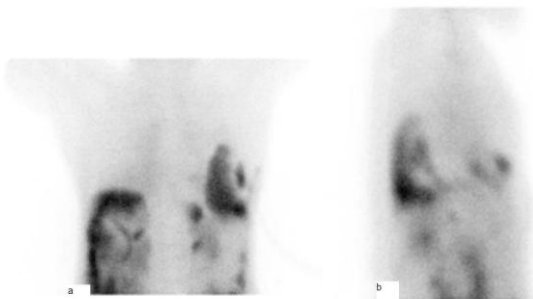


Figure-1. Peritoneal scintigraphy: Posterior (a) and right lateral (b) thorax views showing migration of radioactivity into the right pleural cavity.

Discussion

Hepatic hydrothorax is pleural effusion observed in a cirrhotic patient free of cardiac or pulmonary disease (1). Hydrothorax may develop in all patients with cirrhosis, irrespective of the etiology (2,6). Alcoholic cirrhosis has largely predominated with only a few cases of post-hepatitis cirrhosis (7). Our case had a diagnosis of ascites and pleural effusion due to post-hepatitis cirrhosis. Generally, the volume of effusion in hepatic hydrothorax is not correlated with the volume of associated ascitic fluid. Hydrothorax can occur without ascites (2,7).

A number of different mechanisms have been proposed to explain the development of pleural effusion in patients with cirrhosis. Hypoalbuminemia, increased flow and elevated pressure in the thoracic duct and azygos veins are common in cirrhotic patients and can cause leakage of fluid into the pleural space (1). Passage of ascitic fluid from the peritoneal cavity to the pleural space via lymphatic channels in the diaphragm has also been suggested as a possible mechanism. Because lymphatics are more abundant in the right than in the left diaphragm, this mechanism may explain the higher frequency of hepatic hydrothorax on the right side (8). Alternatively, since microscopic or macroscopic diaphragmatic defects may be congenital or acquired, it has been proposed that peritoneal fluid passes into the pleural space (2). Autopsy studies confirmed the presence of microscopic right centrum tendineum diaphragmatic defects in patients with hepatic hydrothorax (9). Because the left diaphragm is thicker and more muscular than right, this mechanism might also play a role in peritoneal fluid passing into the pleural space less frequently in the left diaphragm.

Patients with cirrhosis and pleural effusion should be assessed with diagnostic thoracentesis, paracentesis, imaging of the chest with chest radiography, tomography and magnetic resonance. However, diagnosis can be difficult in the event of subclinical ascites or if the patient has an associated pulmonary disease known to induce pleural effusions. Demonstration of a peritoneo-pleural communication is especially important for diagnosis in these patients. Dyes, air and radioisotopes have all been used to demonstrate the transdiaphragmatic passage of ascitic fluid into the pleural space (4,5). Non-invasive peritoneal scintigraphy is a simple technique with high diagnostic sensitivity. Tc99m-sulfur colloid and Tc99m-macroaggregated albumin have been used as intraperitoneal tracers to demonstrate the presence of peritoneo-pleural communications (10). We performed peritoneal scintigraphy by using Tc99m DTPA and demonstrated the transdiaphragmatic passage. Generally, radioactivity is detected usually within one hour after the injection if there is a diaphragmatic defect. Longer delays of up to 24 hours have however, been reported (5). The speed of the radioisotope migrating from the peritoneal to pleural space may be a clue for pathophysiologic mechanism. Transit of activity through lymphatic channels usually requires several hours, and activity appears in the pleural space within minutes of injection when a diaphragmatic defect is present. Such a differentiation may influence the patient's treatment. If transit time is slow, only medical treatment can be considered. If transit time is rapid, a macroscopic diaphragmatic defect and its surgical treatment can be

suggested, including shunt procedures and primary repair of the diaphragmatic defects (1,8). We observed the radioactivity in the pleural space within minutes of injection and considered a diaphragmatic defect as the underlying pathology. Furthermore, peritoneal scintigraphy can guide the surgery in patients whose pleural anatomy is distorted by previous therapeutical procedures. The presence of high pressure in the pleural space, inhibiting inflow of abdominal radioactivity, is the

principal cause of false negative peritoneal scintigraphy. To avoid this problem, the pleural cavity must be emptied before intraperitoneal injection (10).

In conclusion, peritoneal scintigraphy is a simple, quick, safe and non-invasive method to diagnose hepatic hydrothorax. In addition, peritoneal scintigraphy can suggest the pathophysiologic mechanism and can guide surgical therapy by determining the pattern and location of inflow to the pleura through the diaphragm.

References

1. Gur C, Ilan Y, Shibolet O. Hepatic hydrothorax--pathophysiology, diagnosis and treatment--review of the literature. *Liver Int* 2004;24(4):281-4.
2. Alberts WM, Salem AH, Solomon DA, Boyce G. Hepatic hydrothorax: Cause and management. *Arch Intern Med* 1991;151(12):2383-8.
3. Streifler J, Dux S, Garty M, Rosenfeld JB. Spontaneous bacterial pleuritis in a patient with cirrhosis. *Respiration* 1984;46(4):382-5.
4. Zenda T, Miyamoto S, Murata S, Mabuchi H. Detection of diaphragmatic defect as the cause of severe hepatic hydrothorax with magnetic resonance imaging. *Am J Gastroenterol* 1998;93(11):2288-9.
5. Mittal BR, Maini A, Das BK. Peritoneopleural communication associated with cirrhotic ascites: Scintigraphic demonstration. *Abdom Imaging* 1996;21(1):69-70.
6. Lazaridis KN, Frank JW, Krowka MJ, Kamath PS. Hepatic hydrothorax: Pathogenesis, diagnosis, diagnosis and management. *Am J Med* 1999;107(3):262-7.
7. Kakizaki S, Katakai K, Yoshinaga T et al. Hepatic hydrothorax in the absence of ascites. *Liver* 1998;18(3):216-20.
8. Bhattacharya A, Mittal BR, Biswas T, et al. Radioisotope scintigraphy in the diagnosis of hepatic hydrothorax. *J Gastroenterol Hepatol* 2001;16(3):317-21.
9. Chen A, Yat-Sen H, Yen-Chang T, et al. Diaphragmatic defects as a cause of massive hydrothorax in cirrhosis of the liver. *J Clin Gastroenterol* 1988;10(6):663-6.
10. Schuster DM, Mukundan S Jr, Small W, Fajman WA. The use of the diagnostic radionuclide ascites scan to facilitate treatment decisions for hepatic hydrothorax. *Clin Nucl Med* 1998;23(1):16-8.