

Left pulmonary artery obstruction due to a large congenital thymic cyst: A rare cause of pulmonary stenosis

Geniş konjenital timik kiste bağlı sol pulmoner arter obstrüksiyonu: Nadir bir pulmoner stenoz nedeni

Isık O Akyuz M Ayık M F Atay Y

Ege University Faculty of Medicine, Department of Cardiovascular Surgery, Izmir, Turkey

Summary

Thymic cysts occur relatively rarely and account for only about 3% of all anterior mediastinal masses. They may be either congenital or acquired. They usually present in the first decade after the age of 2 years, possibly because the thymus attains its greatest development before puberty. Mediastinal thymic cysts are usually asymptomatic and are incidentally found on routine chest roentgenograms. They may rarely cause symptoms of vascular obstruction. This study presents an unusual case of a unilocular thymic cyst that caused pulmonary artery obstruction, cyst imaging and surgical treatment.

Key Words: Mediastinal cyst, thymus gland, pulmonary artery.

Özet

Timik kistler nadir olup ön mediastende sadece %3 oranında görülürler. Konjenital ya da akkiz olabilirler. Timik kistler muhtemelen puberte öncesi en büyük gelişime ulaştığından dolayı çoğunlukla 2 yaşından sonra birinci dekatta ortaya çıkarlar. Mediastinal timik kistler genellikle asemptomatiktir ve tesadüfen rutin akciğer grafisinde bulunurlar. Nadiren vasküler obstrüksiyon belirtilerine neden olabilirler. Bu çalışmada pulmoner arter obstrüksiyonuna neden olan, nadir bir uniloküler timik kistin görüntülenmesi ve cerrahi tedavisi sunuldu.

Anahtar Sözcükler: Mediastinal cyst, thymus gland, pulmonary artery.

Introduction

Thymic cysts occur relatively rarely and account for only about 3% of all anterior mediastinal masses (1). Mediastinal thymic cysts are usually asymptomatic and are incidentally found on routine chest roentgenograms. They may rarely cause symptoms of vascular obstruction. This study presents a case of thymic cyst that caused pulmonary artery obstruction and respiratory symptoms.

Case Report

A 9-year-old boy was admitted to our hospital with shortness of breath on exercise that had been ongoing for one month. On admission, his physical examination and routine blood tests were within normal limits. The chest x-ray showed a large round-shaped opacity of left perihilar localization (Figure-1).

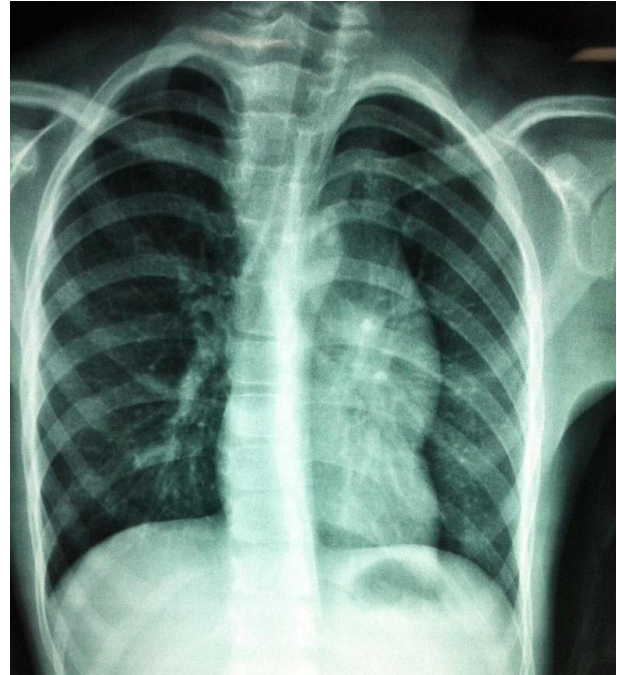


Figure-1. Chest X-ray.

Corresponding Author: Muhammet AKYUZ
Ege University Faculty of Medicine, Department of
Cardiovascular Surgery, Izmir, Turkey

Received: 07.10.2013 Accepted: 11.11.2013

Transthoracic echocardiography revealed a solid-cystic mass obstructing the left pulmonary artery with a 20 mmHg systolic pressure gradient (Figure-2). Computed tomography of the thorax revealed a round shaped, smooth boundary cystic tumor, in close proximity to the main and left pulmonary artery in the anterior mediastinum (Figure-3). Surgical exploration by median sternotomy revealed an encapsulated multilocular cyst arising from the left lobe of the thymus. The cyst was localized posterior of the left phrenic nerve and in close proximity to the main and left pulmonary artery (Figure-4). It was completely removed by a resection of the thymus. After an uneventful recovery, the patient was discharged on postoperative day 3. He was doing well at the second month follow-up visit.

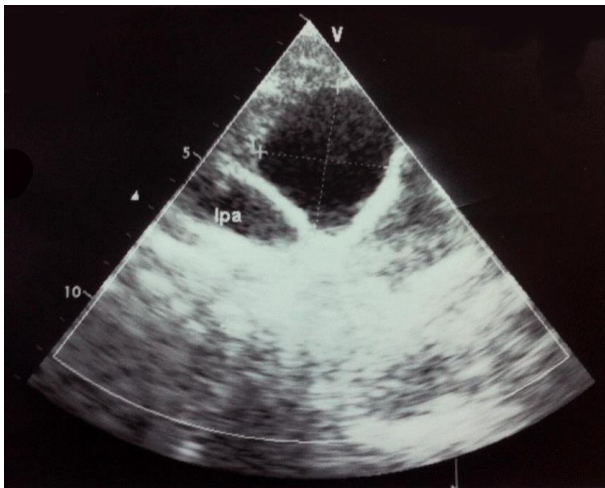


Figure-2. Transthoracic echocardiography.

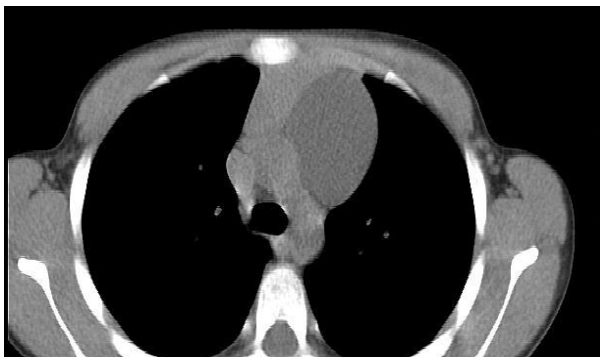


Figure-3. Computed tomography.

The gross macroscopic examination revealed a unilocular cyst, measuring 80x65x15 mm with a cyst wall thickness of approximately 3 mm. The posterior wall of the cyst was thickened with granulation (Figure-5). The histological and cytological examination revealed cuboidal epithelium and lymphocytes, which were on benign pattern. The pathological diagnosis was congenital thymic cyst.

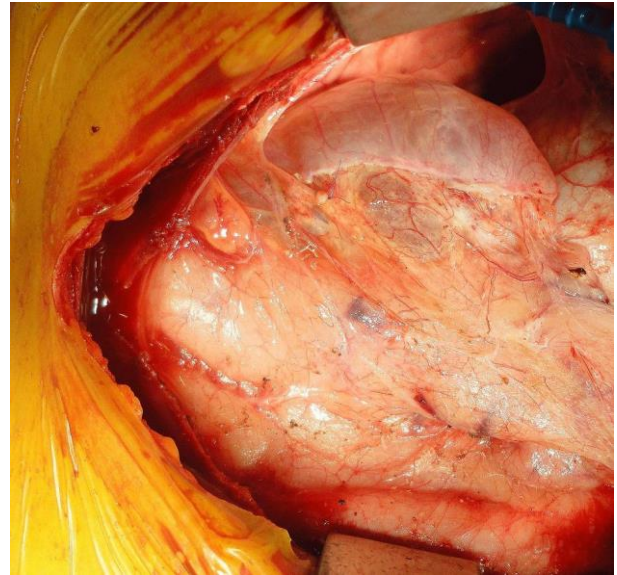


Figure-4. Intraoperative view.

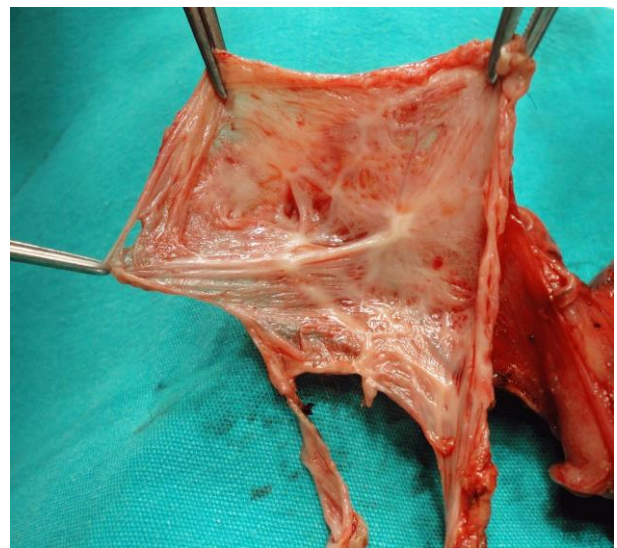


Figure-5. Specimen view.

Discussion

Thymic cysts are uncommon lesions that account for approximately 3% of all anterior mediastinal masses (1). Frequently, they are asymptomatic and the actual identification of the tumor is generally made after surgery and histological examination.

Congenital cysts are likely derived from remnants of the fetal thymopharyngeal duct, and their walls are lined with epithelium with non-inflammatory tissue. Histologically, these cysts are composed of a thin capsule lined with cuboidal, squamous, or columnar epithelium. They may be unilocular or multilocular and frequently contain clear serous fluid.

This case consisted of a unilocular thin walled cyst lined with small cuboidal epithelium including yellowish clear fluid. Cyst walls also had a normal thymic tissue without

inflammation. From these pathological findings this patient was diagnosed with a congenital thymic cyst.

Thymic cysts are usually asymptomatic and discovered incidentally through a chest X-ray. Radiographically, lesions appear as smooth, homogenous, well circumscribed tumors in the anterior mediastinum (2). Although these cysts are usually asymptomatic, they may cause a large variety of symptoms. Symptomatic thymic cysts resulting in chest pain, cough, hoarseness, dyspnea and dysphagia, innominate vein-superior vena cava obstruction have been reported (3, 4). This is a case of a large, benign congenital thymic cyst causing

obstruction of the pulmonary artery due to the fact that cyst compression was unique and unusual.

Although thymic cysts are benign lesions, there are more malign lesions with cystic changes including thymoma, teratoma, lymphoma or seminoma. For that reason, most authors agree that surgical resection remains the curative treatment of choice, and histological examination is the only definitive means of diagnosis (5).

In summary, this is the first report of a congenial thymic cyst in which pulmonary artery compression related symptoms and relieved of symptoms after surgical treatment were shown.

References

1. Davis RD, Oldham HN, Sabiston DC. Primary cysts and neoplasms of the mediastinum: recent changes in clinical presentation, methods of diagnosis, management and results. *Ann Thorac Surg* 1987;44(3):229-37.
2. Schnyder P, Gasmu G. Computed tomography and magnetic imaging. In: Givel JC (ed). *Surgery of the Thymus*. Vol. 4, 1st ed. Berlin: Springer-Verlag; 1990:217-25.
3. Davis JW, Florendo FT. Symptomatic mediastinal thymic cysts. *Ann Thorac Surg* 1998;46(7):693-4.
4. McCafferty MH, Bahnson HT. Thymic cyst extending into the pericardium: A case report and review of thymic cysts. *Ann Thorac Surg* 1982;33(5):503-6.
5. Yamashita S, Yamazaki H, Kato T, Yokota T, Matsumoto N, Matsukura S. Thymic carcinoma which developed in a thymic cyst. *Intern Med* 1996;35(3):215-8.