

Successful treatment of chronic disseminated candidiasis in acute myeloid leukemia patient

Akut myeloid lösemi hastasında kronik dissemine kandidiyazisin başarılı tedavisi

Ozturk E K¹ Soyer N² Bayraktaroglu S³ Hekimgil M⁴ Tobu M² Arda B⁵

¹Ege University Faculty of Medicine, Department of Internal Diseases, Izmir, Turkey

²Ege University Faculty of Medicine, Department of Hematology, Izmir, Turkey

³Ege University Faculty of Medicine, Department of Radiology, Izmir, Turkey

⁴Ege University Faculty of Medicine, Department of Pathology, Izmir, Turkey

⁵Ege University Faculty of Medicine, Department of Infection Diseases, Izmir, Turkey

Summary

Chronic disseminated candidiasis (CDC) is a type of systemic disseminated candida infection and affects neutropenic patients. In this case report, a patient with acute myeloid leukemia (AML) who was diagnosed with CDC during remission induction chemotherapy and treated with amphotericin B and fluconazole respectively is reported. After chemotherapy, a fever that was unresponsive to broad spectrum antibiotic treatment occurred in the patient. Liposomal amphotericin B (lip-amp-B) treatment was started. Serum galactomannan (GM) screening and blood cultures were negative. High resolution computed tomography (CT) was normal. Lip-amp-B treatment was stopped after an afebrile, non-neutropenic period was documented. After all treatment was stopped, the patient became febrile again and abdominal pain occurred. The serum alkaline phosphatase (ALP) level was increased. Blood cultures and GM test were negative and an abdominal CT showed multiple nodular lesions in the spleen. CDC was considered. The patient was treated successfully with amphotericin B. This should be kept in mind in cases of CDC in AML patients who were treated with chemotherapy especially if the fever cannot be controlled although broad spectrum antibiotics.

Key Words: Acute myeloid leukemia, amphotericin B, chronic disseminated candidiasis.

Özet

Kronik dissemine kandidiyazisin (KDK) sistemik yaygın bir kandida enfeksiyonu çeşididir ve nötrojenik hastaları etkiler. Bu vaka sunumunda remisyon indüksiyon kemoterapisi sırasında KDK tanısı alan ve sırasıyla amfoterisin B ve flukonazol ile tedavi edilen bir akut myeloid lösemi olgusu sunulmuştur. Kemoterapi sonrası geniş spektrumlu antibiyotiklere yanıtız ateş ortaya çıktı. Lipozomal amfoterisin B (Lip-Amf-B) tedavisi başlandı. Serum galaktomannan (GM) testi ve kan kültürleri negatifti. Yüksek rezolüsyonlu bilgisayarlı tomografi (BT) normaldi. Hasta nötrojeniden çıkınca ve ateşi kontrol edilince Lip-Amf-B tedavisi kesildi. Tüm tedavisi kesildikten sonra hastanın tekrar ateşi yükseldi ve karın ağrısı ortaya çıktı. Serum alkalen fosfataz seviyesi yükseldi. Kan kültürleri ve serum GM testi negatif olan hastada abdominal BT'de dalakta multipl nodüler lezyonlar görüldü. KDK tanısı düşünöldü. Hastamız amfoterisin B ile başarılı bir şekilde tedavi edildi. Geniş spektrumlu antibiyotiklere yanıt vermeyen ateşi olan, kemoterapi yapılmış akut myeloid lösemi olgularında KDK akla getirilmelidir.

Anahtar Sözcükler: Akut myeloid lösemi, amfoterisin B, kronik dissemine kandidiyazisin.

Introduction

Chronic disseminated candidiasis (CDC) or hepatosplenic candidiasis is a very specific syndrome in patients with malignant diseases. The disease has been recently considered to be an inflammatory immune reconstitution syndrome (1).

Although the treatment of CDC mostly consists of echinocandins and new generation azole groups, and there are no randomized clinical trials that document the optimal treatment for CDC infections (2). There is still a delay in diagnosis and starting the treatment of CDC infections in the era of sophisticated diagnostic tools.

In this case report, we present CDC in acute myeloid leukemia (AML) patients who were treated with remission induction chemotherapy. If the fever cannot be controlled although broad spectrum antibiotics in an acute leukemia patient, CDC should be considered.

Corresponding Author: Ejder Kamil OZTURK

Ege University Faculty of Medicine, Department of Internal Diseases, Izmir, Turkey

Received: 18.11.2013

Accepted: 21.11.2013

Case Report

A 44-year-old male patient was admitted to our hospital with weakness, fever and cough. The physical examination was normal except for paleness in his mucous membranes and fever. The complete blood count test revealed a leukocytosis ($14800/\text{mm}^3$), anemia (Hb: 6.94 gr/dL) and thrombocytopenia ($127000/\text{mm}^3$). The peripheral blood smear demonstrated 60% of blastic cells. A biochemical analysis panel and hepatic function tests were normal but high serum lactate dehydrogenase and C-reactive protein levels were observed. The bone marrow biopsy showed an infiltration of 92% blastic cells which mostly had Auer rods. Flow cytometric analysis and bone marrow biopsy revealed AML-M2 subtype.

A broad spectrum antibiotic (piperacillin/tazobactam) was started on the patient with neutropenic fever. Remission induction chemotherapy (cytosine arabinoside: 1-7 and idarubicin: 1-3 days) was administered. Since the fever could not be brought under control, vancomycin was added to treatment on the second day of the chemotherapy. On the fourth day, piperacillin/tazobactam was changed to meropenem and lip-amp-B (3 mg/kg) was started while the patient was still febrile. Serum GM screening and blood cultures were negative. There was no sign of fungal pneumonia in the high resolution CT.

At the 23th day, the fever was brought under control and lip-amp-B treatment was stopped. Neutropenia was recovered and the bone marrow biopsy performed on the 26th day of chemotherapy revealed remission.

On the 27th day, the patient became febrile again and lip-amp-B was restarted. We suspected CDC because of abdominal pain, high ALP level and fever without any positive culture. Hypodense nodular lesions in the spleen which were compatible with CDC infection and were seen on the abdominal CT. All the antibiotics were stopped and caspofungin acetate (70 mg/day as a loading dose than 50 mg/day as maintenance) was added to the treatment of the patient.

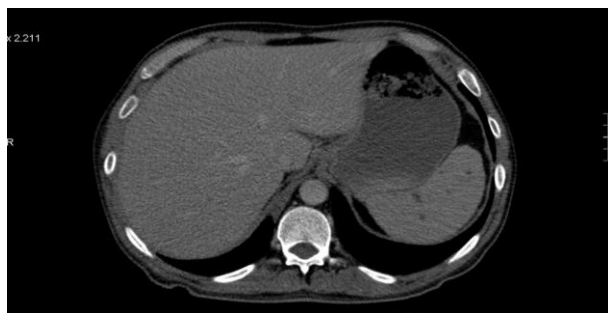

Figure-1a. Hypodense lesions in the spleen in abdominal CT.

On the 61th day, the control abdominal CT revealed an increase in hypodense lesions in the spleen under caspofungin treatment (Figure-1a). So we switched the

caspofungin treatment to lip-amp-B (3 mg/kg/day). During the follow up, the patient was afebrile for 33 days and he was discharged from the hospital with oral fluconazole 300 mg/day. The control abdominal magnetic resonance imaging (MRI) revealed stable nodular lesions in the spleen (Figure-1b).

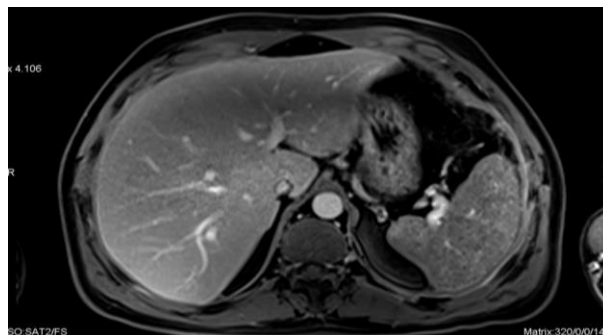


Figure-1b. Hypodense stable nodular lesions in the spleen at follow up period in abdominal MR.

Discussion

CDC is a major cause of mortality and morbidity in patients with hematologic malignancies. Risk factors are acute leukemia, long period (more than ten days) of neutropenia, the presence of intravascular catheters, the breakdown of the mucosal barriers, treatment with broad spectrum antibiotics, total parenteral nutrition (2). CDC mostly infects the spleen and liver. A fever that fails to respond to broad spectrum antibiotics, abdominal pain and hepatomegaly are the signs and symptoms of a CDC infection (3). This clinical picture is mostly seen during the neutropenic period or recovery phase of the neutropenia. Increased serum ALP levels are remarkable (3). In our case, the risk factors for CDC infection were long neutropenic period, diagnosis of acute leukemia, treatment with broad spectrum antibiotics.

The diagnosis is difficult because the blood cultures are often negative. The positive cultures in the tissue specimens are higher than blood cultures. Liver biopsy is required for histopathological and/or microbiological confirmation. The most common species is *Candida albicans* (2). The radiologic techniques are mostly used for diagnosis and response to treatment. Ultrasonography (USG) is mostly used since it is cheap and can be used at bedside. Another technique is CT which is better in documenting the hepatic fungal lesions (2). The sensitivity of MRI is higher than both CT and USG (4). In our case, the diagnosis is supported by the hypodense lesions in the abdominal CT.

The serum levels of beta-D glucan (BDG) are helpful for the early diagnosis of the infection and the response to the treatment (5). Mannan / anti mannan tests have a

higher sensitivity and specificity than BDG tests. These tests are suggested as mycological criteria for the diagnosis of CDC infections (6). We could not perform a biopsy since there were only millimetric lesions in our case and the serologic tests were negative.

There is no randomized study about the optimal type and duration of the treatment in CDC infections. Treatment options are fluconazole, classical amphotericin B, lip-amp-B, voriconazole and caspofungin (7). The duration of treatment is about 3-6 months. It has been suggested that CDC could be an invasive fungal disease related immune reconstitution inflammatory syndrome (8). The use of anti-inflammatory therapy with cox-2 inhibitor may help with symptomatic improvement and immune modulation of inflammatory response (9). In this case, empiric amphotericin B treatment was initiated and then switched to caspofungin

due to possible diagnosis of CDC infection. Fever can be brought under control with this treatment but there was progression in radiologic appearance so caspofungin was switched to lip-amp- B due to partial response. After lip-amp-B for 42 days, the patient was discharged from the hospital with fluconazole treatment.

The clinical response will be observed in about 2-8 weeks under the optimal treatment. Fever can persist for weeks despite optimal antifungal treatment (2). Progression at radiologic appearance despite fever response can be accepted as partial response (10).

In conclusion, the diagnosis of a CDC infection is still difficult despite sophisticated radiological and laboratory tests. The optimal treatment is not well documented. The most important point is that the clinician should be aware of a CDC infection and the necessary tests should be performed without any delay.

References

1. Gupta AO, Singh N. Immune reconstitution syndrome and fungal infections. *Curr Opin Infect Dis* 2011;24(6):527-33.
2. Rammaert B, Desjardins A, Lortholary O. New insights into hepatosplenic candidosis, a manifestation of chronic disseminated candidosis. *Mycoses* 2012;55(3):e74-84.
3. Sallah S, Semelka RC, Wehbie R, Sallah W, Nguyen NP, Vos P. Hepatosplenic candidiasis in patients with acute leukaemia. *Br J Haematol* 1999;106(3):697-701.
4. Anttila VJ, Lamminen AE, Bondestam S, et al. Magnetic resonance imaging is superior to computed tomography and ultrasonography in imaging infectious liver foci in acute leukaemia. *Eur J Haematol* 1996;56(1-2):82-7.
5. Lamoth F, Cruciani M, Mengoli C, et al. b-Glucan antigenemia assay for the diagnosis of invasive fungal infections in patients with hematological malignancies: a systematic review and meta-analysis of cohort studies from the Third European Conference on Infections in Leukemia (ECIL-3). *Clin Infect Dis* 2012; 54(5):633-43.
6. Mikulska M, Calandra T, Sanguinetti M, Poulain D, Viscoli C. The use of mannan antigen and anti-mannan antibodies in the diagnosis of invasive candidiasis: recommendations from the Third European Conference on Infections in Leukemia. *Crit Care* 2010;14(6): R222.
7. Ullmann AJ, Akova M, Herbrecht R, et al. ESCMID guideline for the diagnosis and management of *Candida* diseases 2012: Adults with haematological malignancies and after haematopoietic stem cell transplantation (HCT). *Clin Microbiol Infect* 2012;18(Suppl 7):53-67.
8. Legrand F, Lecuit M, Dupont B, et al. Adjuvant corticosteroid therapy for chronic disseminated candidiasis. *Clin Infect Dis* 2008;46(5):696-702.
9. Poon LM, Chia HY, Tan LK, Liu TC, Koh LP. Successful intensive chemotherapy followed by autologous hematopoietic cell transplantation in a patient with acute myeloid leukemia and hepatosplenic candidiasis: case report and review of literature. *Transpl Infect Dis*. 2009; 11: 160-6.
10. Segal BH, Herbrecht R, Stevens DA, et al. Defining responses to therapy and study outcomes in clinical trials of invasive fungal diseases: Mycoses Study Group and European Organization for Research and Treatment of Cancer consensus criteria. *Clin Infect Dis* 2008;47(5):674-83.