



DIETHYLSTİLBESTROL KULLANIM ÖYKÜSÜ OLMAYAN 40 YAŞINDAKİ OLGUDA SPONTAN VAGİNAL ADENOZİS: OLGU SUNUMU

ASYMPTOMATIC VAGİNAL ADENOSIS IN A NON-DIETHYLSTİLBESTROL-EXPOSED 40-YEAR - OLD PATIENT: A CASE REPORT

Murat ULUKUŞ¹ Nedim KARADADAŞ¹ Fuat AKERCAN¹ Mustafa ULUKUŞ¹ Coşan TEREK¹
Osman ZEKİOĞLU²

¹Ege Üniversitesi Tıp Fakültesi Kadın Hastalıkları ve Doğum Anabilim Dalı, Bornova, İzmir

²Ege Üniversitesi Tıp Fakültesi Patoloji Anabilim Dalı, Bornova, İzmir

Anahtar Sözcükler: vaginal adenozis

Key Words: vaginal adenosis

SUMMARY

Adenosis of the vagina is defined as the presence of the metaplastic cervical or endometrial epithelium within the vaginal wall. This definition has been expanded to embrace the presence of any Mullerian type glandular epithelium in the vagina. As it may arise in up to 90% of women prenatally exposed to diethylstilbestrol (DES), it may also arise spontaneously. We report a 40-year-old case of spontaneously induced vaginal adenosis.

ÖZET

Vaginal adenozis, metaplastik servikal ya da endometriyal bezlerin vagina duvarları içerisinde bulunması olarak tanımlanmaktadır. Bu tanımlama vaginadaki tüm Mülleryan tipteki glandüler epiteli kapsamaktadır. Prenatal olarak diethylstilbestrole (DES) maruz kalan kadınların %90'ından fazlasında görülebilmekle beraber, spontan olarak da oluşabilmektedir. Bu çalışmada 40 yaşında spontan olarak gelişmiş bir vaginal adenozis vakası sunulmuştur.

INTRODUCTION

Since the withdrawal of diethylstilbestrol (DES) from the market, vaginal adenosis became a rarely described condition in the literature. On the other hand, spontaneously induced vaginal adenosis became most popular in the last two decades and its reported incidence is about 10% in adult women (1). The histological features of both forms are identical (2). Although in DES exposed women vaginal adenosis may be rarely associated with the development of vaginal clear cell adenocarcinoma (3), now it is well-known that the same risk also exists for women who did not expose to DES (4,5). Currently

Yazışma adresi: Murat Ulukuş, Ege Üniversitesi Tıp Fakültesi Kadın Hastalıkları ve Doğum Anabilim Dalı, Bornova, İzmir
Makalenin geliş tarihi: 07. 06. 2002 ; Kabul tarihi: 10. 09. 2002

colposcopic assessments and repeated biopsies are the most available management method for this disorder. We report a 40-year-old case of spontaneously induced vaginal adenosis.

CASE REPORT

A 40-year-old gravida 2 para 2 woman was admitted to our clinic complaining of irregular heavy menstrual bleedings for three months. There was no special feature on her gynecological history. Inspection of the vagina and cervix showed multiple, white-colored, non-tender cystic lesions on the vaginal wall and on the cervix. These cystic lesions were 2-3 mm in diameter and were localized especially on the anterior and posterior walls of the vagina

(Figure 1). The patient was not complaining of any mucous vaginal discharge or dyspareunia. Uterus and both adnexa were normal at gynecological examination. Hematocrite level (27%) decreased due to irregular menstrual bleeding. Other laboratory studies were in normal range. On the first step, a fractional curettage was performed and multiple colposcopy-directed biopsies were obtained from the cystic vaginal wall lesions. Histopathological examination of the fractional curettage revealed chronic cervicitis, squamous metaplasia and irregular proliferative endometrium. Histopathological examination of the vaginal biopsies revealed vaginal adenosis and squamous metaplastic epithelium (Figure 2 and 3). There were no malignant cells in association with the adenosis on histopathological sections. The patient preferred surgical treatment rather than medical treatment for her excess menstrual bleeding and then, a total abdominal hysterectomy (excluding adnexa) was performed. Adenomyosis was found on the histopathological examination of the uterus.

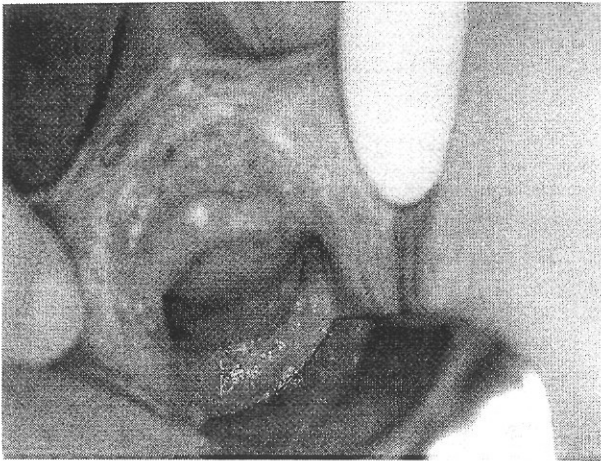


Figure 1. On the macroscopic examination of the vagina, multiple, 2-3 mm of diameter cystic lesions are seen on the anterior and posterior wall.

The patient's history was obtained both from herself and her mother. There was no in utero DES exposure and the patient stated that she had never used oral contraceptives. She was extubated on the fifth postoperative day and she has been told that she has to be examined regularly for the vaginal lesions. Colposcopy-directed vaginal biopsies were planned for six months later.

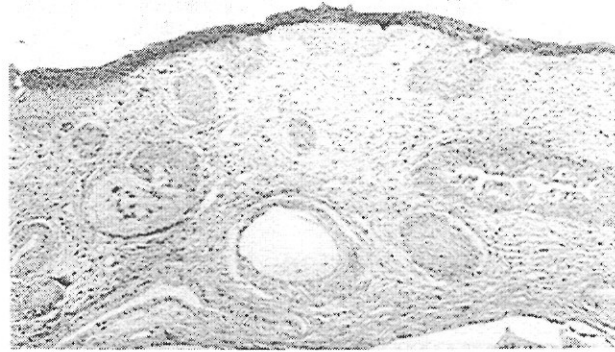


Figure 2. Histopathological examination of the vaginal biopsies revealed vaginal adenosis and squamous metaplastic epithelium.

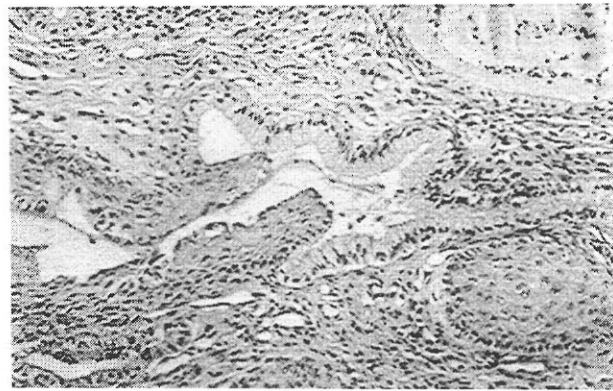


Figure 3. The mucinous columnar cells that resemble those of the normal endocervical mucosa, line the glands in the lamina propria.

DISCUSSION

Vaginal adenosis is a poorly understood condition and our knowledge is inadequate about its etiology, pathogenesis and the management. As documented in many reports the well-known etiological factor is DES exposure in utero (6-8). Some authors suggested that vaginal adenosis may arise on a congenital basis but that steroid hormones may play a stimulatory role in their development (9). A relation between vaginal adenosis and polycystic ovaries was also postulated (10). Protracted oral contraceptive intake is also one of the speculated etiological factors (11). However in some patients, it is demonstrated that severe vaginitis causing mucosal injury or Mullerian anomalies such as imperforate hymen can precipitate in the development of vaginal adenosis (12,13). It also exists in some patients who developed vaginal adenosis following 5-fluorouracil treatment for diffuse vaginal condylomatosis and vaginal intraepithelial neoplasia (14,15). We thought that in our patient vaginal adenosis is induced spontaneously because none of these predisposing factors could be demonstrated in her gynecological history.

Three histological forms of vaginal adenosis have been described: mucinous (endocervical), tuboendometrial and an extremely rare form, intestinal metaplasia (16). There is a strong relationship between the clear cell carcinoma and the tuboendometrial forms of the adenosis. In a report, 95% of the adenosis associated with clear cell carcinoma was in tuboendometrial form (17). In most biopsy specimens, metaplastic squamous cells replace adenosis to some degree, indicating the manner by which adenosis regresses. Follow-up studies in which the same subjects have been examined repeatedly over a period of several years have indicated that adenosis and vaginal epithelial changes may regress spontaneously (18,19).

Excess mucous discharge is the main symptom of vaginal adenosis, although many patients may be asymptomatic like our patient. Whatever the etiology, the essential problem with this disorder is the probability of association with clear cell adenocarcinoma. The risk of carcinoma in the DES exposed women has been estimated to be 1/1000 (20), however the risk for the non-exposed group is unknown to the best of our knowledge. As we stated above, some cases of vaginal adenosis with adenocarcinoma without any recognized antecedent factors have been described previously (4,5). Colposcopic examinations and if needed, repeated biopsies are the most accurate approach for the management of women with vaginal adenosis to prevent malignancy.

REFERENCES

1. Chattopadhyay I, Cruickshank DJ, Packer M. Non diethylstilbesterol induced vaginal adenosis, a case series and review of the literature. *Eur J Gynaecol Oncol* 2001; 22: 260-262
2. Robboy SJ, Hill EC, Sandberg EC, Czernobilsky B. Vaginal adenosis women born prior to diethylstilbesterol era. *Hum Pathol* 1986; 17:488-492
3. Ghosh TK, Cera PJ. Transition of benign vaginal adenosis. to clear cell adenocarcinoma. *Obstet Gynecol* 1983; 61:126-130
4. Chariton A, Kirker JA, Robertson AK, Jones RW. Vaginal adenosis with adenocarcinoma in situ in a woman with no recognised antecedent factors. *Aust N Z J Obstet Gynaecol* 2001 Feb;41: 97-99
5. Maassen V, Lampe B, Untch M, et al. Geburtshilfe Frauenheilkd 1993 ;53: 308-313
6. Herbst AL, Kurman RJ, Skully RE. Vaginal and cervical abnormalities after exposure to stilbesterol in utero. *Obstet Gynecol* 1972; 40: 287-298.
7. Antonioli DA, Burke L. Vaginal adenosis: analysis of 325 biopsy specimens from 100 patients. *Am J Clin Pathol* 1975; 64: 625-638.
8. Kaufman RH, Korhonen MO, Strama T, Adam E, Kaplan A. Development of clear cell adenocarcinoma in DES-exposed offspring under observation. *Obstet Gynecol* 1982; 59(suppl): 68S-72S.
9. Kurman RJ, Scully RE. The incidence and histogenesis of vaginal adenosis. *Hum Pathol* 1974; 5:265-276.
10. Doshi N, Fujikara T, Kanbour A. Vaginal adenosis and polycystic ovaries during infancy and childhood. *Am J Obstet Gynecol* 1977; 129:374-378.
11. Kranl C, Zelger B, Kofler H, et al. Vulval and vaginal adenosis. *Br J Dermatol* 1998; 139: 128-131.
12. Marquette GP, Su B, Woodruff JD. Introital adenosis associated with Stevens-Johnson syndrome. *Obstet Gynecol* 1985; 66: 143-145.
13. Hansen K, Egholm M. Diffuse vaginal adenosis: Three cases with imperforate hymen and haematocolpos. *Açta Obstet Gynecol scand* 1975; 54: 287-292.
14. Goodman A, Zukerberg LR, Nikrui N, Scully RE. Vaginal adenosis and clear cell carcinoma after 5-fluorouracil treatment for condylomas. *Cancer* 1991; 68: 1628-1632.
15. Dunger CF, Wilkinson EJ. Vaginal columnar cell metaplasia. An acquired adenosis associated with topical 5-fluorouracil therapy. *J Reprod Med* 1995 ; 40: 361-366.
16. Merchant WJ, Gale J. Intestinal metaplasia in stilbesterol induced vaginal adenosis. *Histopathology* 1993; 23: 373-376.
17. Robboy SJ, Welch WR, Young RH, et al. Topographic relation of cervical ectropion and vaginal adenosis to clear cell adenocarcinoma. *Obstet Gynecol* 1982; 60: 546-551.
18. Antonioli DA, Burke L, Friedman EA. Natural history of diethylstilbestrol-associated genital lesions: Cervical ectopy and cervicovaginal loid. *Am J Obstet Gynecol* 1980; 137:847
19. Robboy SJ, Szyfelbein WM, Goellner JR, et al. Displasia and cytologic findings in 4589 young vromen enrolled in diethylstilbestrol-adenosis (DESAD) project. *Am J Obstet Gynecol* 1981; 140:579
20. Melnick S, Cole P, Anderson D, Herbst A. Rates and risks of diethylstilbestrol related clear cell adenocarcinoma of the vagina and the cervix. *N Engl J Med* 1987; 316: 514-516.