


## Our clinical experience with labia majoroplasty

### Labia majoroplasti ile ilgili klinik deneyimimiz

Savas Ozgur Aglamis<sup>1</sup> 

Eda Adeviye Sahin<sup>2</sup> 

Hanifi Sahin<sup>3</sup> 

Turan Sahin<sup>4</sup> 

<sup>1</sup> Private Ozgur Aglamis Clinic Department of Obstetrics and Gynecology, Istanbul, Türkiye

<sup>2</sup> Private Eda Adeviye Sahin Clinic Department of Obstetrics and Gynecology, Istanbul, Türkiye

<sup>3</sup> Private Hanifi Sahin Clinic Department of Obstetrics and Gynecology, Istanbul, Türkiye

<sup>4</sup> Dr İlhan Varank training research hospital, Department of Obstetrics and Gynecology, Istanbul, Türkiye

### ABSTRACT

**Aim:** To share our experiences and surgical results of our labia majoroplasty technique and its complications

**Material and Methods:** Sixty-three patients who applied with complaints of sagging labium majus, decreased adipose tissue, excessive wrinkling, folding of the skin were included in the study. The appearance of the labia majora after the procedure was evaluated with photographs and patient satisfaction questionnaires including the female genital self-image scale (FGSIS).

**Results:** There were no life-threatening complications or serious sequelae after the procedure. So, post-op had better results for genital beauty since a higher FGSIS score indicated a more positive genital self-image and significantly correlates with a woman's sexual function, sexual behavior, and sexual and genital health-care behaviors. At 6 months of follow-up, the mean total FGSIS score was  $20.4 \pm 1.2$  in the pre-op and  $22.4 \pm 1.4$  in the post-op, indicating a statistically significant difference ( $p = 0.026$ )

**Conclusion:** Labia majoroplasty is a surgical procedure that contributes positively to functions, hygiene, and aesthetic appearance. There is a lack of major complications, that leave life-threatening permanent sequelae after the current surgical technique and minor complications can be controlled in a short time, all of which suggest that that the technique applied in the present study is easily applicable. At the same time, a positive significant improvement was observed in FGSIS results and was correlated with an increase in self-confidence in patients.

**Keywords:** Complication, FGSIS, labia majoroplasty, sexual health.

### ÖZ

**Giriş:** Bu çalışmanın arka planı, labia majoroplasti tekniğimiz ve komplikasyonları ile ilgili deneyimlerimizi ve cerrahi sonuçlarımızı paylaşmaktır.

**Gereç ve Yöntem:** Çalışmaya labium majus sarkması, yağ dokusunda azalma, ciltte aşırı kırışıklık ve katlanma şikayeti ile başvuran 63 hasta dahil edildi. İşlem sonrası labia majora'nın görünümü fotoğraflarla ve kadın genital benlik imajı ölçeğini (FGSIS) içeren hasta memnuniyet anketleriyle değerlendirildi.

**Bulgular:** İşlemden sonra hayatı tehdit eden herhangi bir komplikasyon veya ciddi sekeller görülmedi. Dolayısıyla, daha yüksek FGSIS puanı daha olumlu bir genital benlik imajına işaret ettiğinden ve kadının cinsel işlevi, cinsel davranışı ve cinsel davranışı ile önemli ölçüde ilişkili olduğundan, ameliyat sonrası genital güzellik açısından daha iyi sonuçlar elde edildi.

Corresponding author: Savas Ozgur Aglamis  
Private Ozgur Aglamis Clinic Department of Obstetric and  
Gynecology, Istanbul, Türkiye  
E-mail: [ozgurztb@gmail.com](mailto:ozgurztb@gmail.com)  
Application date: 03.06.2024 Accepted: 20.08.2024

*Cinsel ve genital sađlık bakım davranışları 6 aylık takipte ortalama toplam FGSIS skoru ameliyat öncesi 20,4 ± 1,2 ve ameliyat sonrası 22,4 ± 1,4 olup istatistiksel olarak anlamlı bir farka işaret etmektedir (p = 0,026).*

**Sonuç:** *Labium minus estetiđi, fonksiyonlara, hijyene ve estetik görünümüne olumlu katkı sađlayan bir cerrahi işlemdir. Mevcut cerrahi teknikte yaşamı tehdit eden kalıcı sekel bırakan majör komplikasyonların görülmemesi ve minör komplikasyonların kısa sürede kontrol altına alınabilmesi bu çalışmada uygulanan tekniđin rahatlıkla uygulanabilir olduğunu göstermektedir. Aynı zamanda FGSIS sonuçlarında da olumlu yönde anlamlı bir iyileşme gözlemlendi ve hastalarda özgüven artışıyla ilişkilendirildi.*

**Anahtar Sözcükler:** *Cinsel sađlık, FGSIS, komplikasyon, labia majoroplasti.*

## INTRODUCTION

The awareness and the demand of genital plastic surgery applications are increasing day by day. According to the International Society of Aesthetic Plastic Surgery, an increase of 73% from 2015 to 2020 of labiaplasty cases. (1). The prediction in the market of genital rejuvenation shows 34% growth until 2026 (2). The most important motivation that leads people to surgery is concerns about appearance. This is followed by physical discomfort, self-confidence problems and critical comments from sexual partners (3). The reason for the increase in interest in cosmetic gynecology is associated with the development of such procedures as waxing and other epilation methods, also the ease of access to indecent photographs and movies, the increased awareness of differences in the genital area, and the increased search for the ideal appearance (4). The available evidence suggests that as human beings, we are subconsciously obsessed with our genitals (5).

Due to aging, rapid weight gain and loss, decrease in the amount of collagen, slowing of hyaluronic acid production, acceleration of hyaluronic acid destruction, volume reduction in adipose tissue, sagging and wrinkling of the skin begin to be seen in the labium majus. With the increasing interest in genital aesthetic applications, the frequency of rejuvenation surgery for labium majus hypotrophy is increasing. The present study aims to share our experiences and surgical results of our labia majoroplasty technique.

## MATERIALS and METHODS

This study was approved by the Institutional Review Board of Sancaktepe Şehit Prof. Dr. İlhan Varank Training and Research Hospital, Sancaktepe, Istanbul (Institutional Review Board

Approval Number: E-46059653-050.99-243919737)

Sixty-three patients who applied to our clinic with complaints of sagging labium majus, decreased adipose tissue, excessive wrinkling and folding of the skin were included in the study. The ages of the patients ranged between 37 years and 56 years. Written informed consent was obtained from all participants. This study was conducted according to the standards of Good Clinical Practice (ICH-E6) and the principles of the Declaration of Helsinki. None of the patients had undergone labia majora surgery before. In addition, none of the patients had ever undergone autologous fat filling or hyaluronic acid filling for labia majora augmentation. And none of the participants had undergone any non-surgical cosmetic gynecology procedure such as high-intensity focused ultrasound or radiofrequency procedure for labia tissue tightening. Of the 23 patients, 5 smoked less than 10 cigarettes and 8 smoked more than 10 cigarettes per day. The remaining 10 patients were non-smokers. None of the patients had a history of chronic disease or chronic drug use that might affect wound healing. In addition, supplementary food consumption such as herbal tea and multivitamins was stopped at least 2 weeks before the procedure because it may affect wound healing. This diet was continued for one month after the procedure. The appearance of the labia majora after the procedure was evaluated with photographs and patient satisfaction questionnaires including the female genital self-image scale (FGSIS).

## Surgical technique

Before the procedure, 15 cc infiltration anesthesia was applied to both labium majora. For infiltration anesthesia, 2 ml of local anesthetic (Jetocaine) containing 20 mg Lidocaine Hydrochloride and 0.0125 mg Epinephrine base

per ml and 3 ml bupivacaine were added into 25 cc ringer lactate. A total of 30 cc of infiltration anesthesia solution was obtained. After infiltration anesthesia was applied to both labium majora, the anesthesia was allowed to reach maximum efficacy for 7 minutes. Afterward, the excess skin to be removed from both labium majora was marked with a sterile skin pen in the form of a semi-balloon starting from the interlabial sulcus between the labium majus and labium minus to the lateral surface of the labium majus. Although the amount of tissue to be removed varies according to the surface area of the labium majus tissue and the level of sagging, it is planned to remove an average of 8-10 cm of skin and subcutaneous tissue vertically and 2.5-3 cm of skin and subcutaneous tissue horizontally. Then, a marked area incision was made with a No. 15 scalpel, and the skin, subcutaneous fascia, connective tissue, and adipose tissue were removed in the coagulation mode of the cautery at a power setting of 30 W for tissue excision up to a total depth of 0.5 cm. Bleeding control was performed after the procedure. The defects identified in the adipose sac were sutured separately with 3.0 Vicryl sutures to maintain the integrity of the adipose sac. After ensuring the integrity of the adipose sac, the adipose tissue that had herniated was removed with a fine cautery tip at 30 w even though it was minimal between the sutures. Plication of the fascia and connective tissue on the adipose tissue was again achieved with 3.0 vicryl sutures, leaving a 0.5 cm gap from top to bottom. After plication, 4.0 Vicryl was used to approximate the skin. A sub-

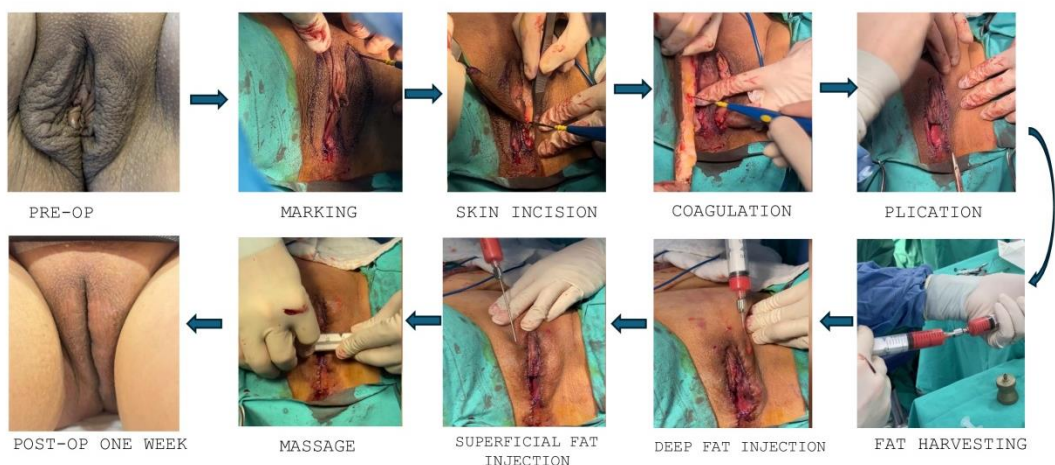
cuticular suture was applied to the skin with 5.0 Rapid Vicryl (Figure-1).

After the patients were taken to their rooms after the procedure, ice application was performed as 30 min on and 30 min off for the first 4 hours. Patients were discharged from the hospital 12 hours after the procedure. Wound care training was given at the time of discharge. At discharge, the patients were prescribed metronidazole 500 gr twice a day for 1 week and paracetamol 500 mg twice a day for 3 days.

#### Postoperative Follow-Up

For post-procedure control, the patients were called on the 3<sup>rd</sup>, 5<sup>th</sup>, and 7<sup>th</sup> days in the early period, on the 15<sup>th</sup> and 30<sup>th</sup> days, and in the 3<sup>rd</sup>, 6<sup>th</sup> months in the last period. The effect of surgery on the labia majora after the procedure was evaluated with photographs and patient satisfaction questionnaires including the female genital self-image scale (FGSIS). The FGSIS is a 7-item questionnaire that has respondents rate each question on a 4-point response scale (strongly disagree [1 point], disagree [2 points], agree [3 points], or strongly agree [4 points]). An individual's total score is obtained by adding the scores of individual questions and can range from 7 to 28. A higher score indicates a more positive genital self-image and significantly correlates with a women's sexual function, sexual behavior, and their sexual and genital health-care behaviors. Since patients' satisfaction was questioned in our study, there may be a possible response bias. FGSIS, an international, (6). valid and validated scoring system was used to reduce this.

## DIAGRAM OF SURGICAL PROCEDURE



**Figure-1.** Diagram of the surgical procedure.

## RESULTS

A total of 63 patients were included in the study. The mean age was  $33.8 \pm 5.2$  years, and the mean body mass index (BMI) was  $24.1 \pm 3.6$  kg/m<sup>2</sup>. There were no life-threatening complications or serious sequelae after the procedure. There were 5 complications in 4 patients. Three of the four patients were smokers, and one was a non-smoker. The first complication (patient A) was a subcuticular skin suture dehiscence that occurred in the first week. There was a 2-cm dehiscence in the left labium majus subcuticular suture. As soon as it was detected, a single suture was applied with 4.0 vicryl under local anesthesia. Another one (patient B) was a subcutaneous hematoma of about 3 cm in the midline of the right labium majus, which was detected on the 3rd day. The patient was referred to radiology and the superficial ultrasound report was consistent with a hematoma covering an area of 3.5 cm at a depth of 1 cm into the skin. The hematoma was followed up. The hematoma did not grow the next day and was absorbed and disappeared spontaneously during follow-up.

Another complication (Patient C) was a superficial skin infection of the patient, who came for the control on the 5<sup>th</sup> day, in which the incision line opened spontaneously up to 0.3 cm and purulent fluid came from the inside. The culture was taken and sent to the laboratory. In our interrogation, we realized that the patient did not use the antibiotic we prescribed. Antibiotic treatment was started quickly after the culture. Rifamycin (Rif 250) was started to be applied morning and evening to the 0.3 cm defective area from which purulent fluid was coming. The antibiotic administered according to the culture result was not changed and it was continued. The defective area was secondarily closed without the need for any surgical suturing. In another patient (Patient D), on the 5th day of control, a seroma covering an area of 1.8 cm in the left labium majus was confirmed by superficial ultrasound and a severe superficial hematoma-like ecchymosis covering the right labium majus was observed at the same time. While the ecchymosis disappeared on spontaneous follow-up with mucopolysaccharide polysulphate gel, the 1.8 cm seroma was aspirated with a superficial ultrasound and sent to the laboratory. No growth was observed. Repeat superficial ultrasound performed one week later showed no

seroma. Information about the complications for patients is shown in Table-1.

The mean preoperative FGSIS scores were similar between the pre-op and post-op periods ( $p = 0.532$ ). The mean total FGSIS score was  $18.6 \pm 1.2$  in the pre-op and  $18.5 \pm 1.4$  in the post-op. However, the mean FGSIS scores at 1, 3, and 6 months were significantly higher in the post-op than the pre-op ( $p = 0.03$ ,  $p = 0.01$ , and  $p = 0.008$ , respectively). So, post-op had better results for genital appearance since a higher FGSIS score indicated a more positive genital self-image and significantly correlates with a women's sexual function, sexual behavior, and genital health-care behaviors. At 6 months of follow-up, the mean total FGSIS score was  $20.4 \pm 1.2$  in the pre-op and  $22.4 \pm 1.4$  in the post-op, indicating a statistically significant difference ( $p = 0.026$ ) (Table-1). The mean FGSIS score results of the two groups were also shown as a line graphic

**Table-1.** Complications after labia majoroplasty

Patient A	Skin suture opening (Post-op 1st week) <b>(Smoker)</b>
Patient B	Hematoma (Post-op 3rd.day) <b>(Smoker)</b>
Patient C	Skin infection (Post-op 5th. day) <b>(Non-Smoker)</b>
Patient D	Seroma & ecchymosis (Post-op 5th. day) <b>(Smoker)</b>

## DISCUSSION

When the literature is reviewed, there is no agreed labium majus measurement or ideal ratio that defines how the ideal labium majus should be. In the literature, the ideal vulva is described as a symmetrical and full labium majus appearance and invisible labium minora when the patient is standing. However, there is no measurement-based classification in the literature (7). As a contribution to the literature, the presentation of both the technique and the management of complications shows the importance of the present study.

The most commonly used method for labiaplasty is a surgical removal of excess skin and adipose tissue (8). Another method is autologous micro and nano fat transfer for Labia majora rejuvenation (9). However, since the sagging skin tissue is not excised in this method, the problem of sagging skin reappears when the adipose tissue transferred starts to melt. In addition, it may cause the formation of lipoma under the skin

after fat transfer (10). In the current study, the resection of excess skin tissue and correction of defects in the subcutaneous connective and adipose tissue were prioritized. In contrast to adipose tissue transfer, some of the adipose tissue with increased amount and volume was resected. Thus, no complications such as lipoma were encountered, and no extra procedure was added to the surgical process by eliminating the fat harvesting process that should be performed before fat transfer. Moreover, if we had done the fat harvesting process, we would have to use materials that would create additional costs specific to this process. However, in the current study, the surgical technique can be performed with the materials available in the operating room routinely. This can be considered as an advantage of the technique in terms of easier applicability. In addition, the absence of using extra equipment also reduces the cost of the procedure.

In a study on labia majoroplasty, suturing was performed directly on the midline of labia majora from top to bottom after excess skin was removed (11). It does not seem from an aesthetic point of view that the scar area that will remain after the procedure is present in a visible place. In the current study, the suture in the interlabial sulcus between the labium minus and labium majus is concealed so that the scar area is not visible from the outside. This can be considered as an advantage of the technique. In addition, in another study of labia majoroplasty, the scar line remained visibly in the inguinal canal in the postoperative period as the incision was made very close to the inguinal canal (12). This seems to be an advantage of the technique in the present study when compared to the other technique.

Similar to the technique in the present study, in their study, Alter et al., aimed to provide a more aesthetic wound healing and appearance by leaving the incision line in the interlabial sulcus (13). Our similarity to the study can be considered as an advantage of our study. Labia minora reduction and labia majoroplasty surgeries can be performed simultaneously (14). In the present study, it was aimed to perform isolated labia majoroplasty surgery to evaluate both the healing process and the complications that may occur only in terms of labia majoroplasty. Thus, it was possible to follow the results in terms of a single surgical technique without adding surgery.

Ostrzenski defined labioplexy as a new surgical intervention that reduces the size of the Colles' fascia and the size of the labium majus without excising the adipose tissue (15). This technique consists of the reconstruction of site-specific defects of the adipose sac and excision of the cutis just above the adipose sac tissue. The difference from this technique, which is very similar to the present study, is that routine tightening plication for the Colles' fascia was performed after labioplexy. In addition, the adipose tissues which were located between the correction suture during the correction of the adipose sac and minimally herniated were excised via cautery, so that the contour would have a flatter appearance.

In the study described by Ostrzenski, it was stated that the tension of the labium majus tissue was provided by three parameters. These are skin tightness, intact adipose sac tissue, and intact and tense Colles' fascia, respectively. In the present study, a standard plication was applied for the repair of all these adipose sacs and Colles defects and additionally, for tightening. Thus, it was intended to provide more tension in the labium majus tissue. In the traditional concept of labia majoroplasty, only excess skin and subcutaneous adipose tissue are excised followed by primary suturing (16). The present study may be seen advantageously than other techniques as it includes the correction of the integrity of the adipose sac, which was discovered in 2016, and plication of the Colles' fascia for standard tightening, apart from traditional applications. In another study, a de-epithelized fasciocutaneous flap for labia majora augmentation during thigh lift technique was applied in a surgical technique for correction and rejuvenation of labia majora appearance (17). This technique is not easy to apply and involves a different discipline, which makes it more difficult than our technique. In another study, a dermal fat graft was used in the surgical technique performed for the correction and rejuvenation of the labia majora appearance, but this technique seems to be more difficult compared to our technique because it is not easily applicable and practicable (18).

The technique in the present study is easy to apply and the tissue used as a graft does not lose volume over time since there is no graft application in our technique, all of which seem to be the advantages of the technique in terms of permanence and easy applicability.

## CONCLUSION

Labia majoroplasty is a surgical procedure that contributes positively to functions, hygiene, and aesthetic appearance. There is a lack of major complications, that leave life-threatening permanent sequelae after the current surgical technique and minor complications can be controlled in a short time, all of which suggest that the technique applied in the present study is easily applicable. With the increasing interest in cosmetic gynecology every passing

day, it is foreseen that the number of labia majoroplasty surgeries and the number of techniques to be defined will increase. At the same time, a positive significant improvement was observed in FGSIS results and was correlated with an increase in self-confidence in patients. Further studies with a larger number of patients should be conducted to confirm the data of the present study.

**Conflict of interest:** The authors declared no conflict of interest.

## References

1. Isaps.org [homepage on the Internet]. International Society of Aesthetic Plastic Surgery. International Survey on Aesthetic/Cosmetic Procedures Performed in 2019. [updated 02 May 2024; cited 28 May 2024]. Available from [www.isaps.org/discover/about-isaps/global-statistics](http://www.isaps.org/discover/about-isaps/global-statistics).
2. Gminsights.com [homepage on the Internet]. Vaginal Rejuvenation Market Size By Treatment (Labioplasty, Vaginoplasty, Hymenoplasty, Perineoplasty, Hoodectomy, g-spot Amplification), By End-use (Hospitals, Plastic Surgery Centers), Industry Analysis Report, Regional Outlook, Application Potential, Price Trends, Competitive Market Share & Forecast, 2020 – 2026 [updated 04 May 2024; cited 28 May 2024]. Available from [www.gminsights.com/industry-analysis/vaginal-rejuvenation-market](http://www.gminsights.com/industry-analysis/vaginal-rejuvenation-market).
3. Özer M, Mortimore I, Jansma EP, Mullender MG. Labioplasty: motivation, techniques, and ethics. *Nat Rev Urol* 2018;15(3):175-89.
4. Alter GJ. Aesthetic labia minora and clitoral hood reduction using extended central wedge resection. *Plast Reconstr Surg* 2008;122(6):1780-9
5. Cassell WA. Body awareness and somatic delusions involving sexual organs. *Am J Psychoanal* 1980;40(2):125-35
6. Herbenick D, Reece M. Development and validation of the female genital self-image scale. *J Sex Med* 2010;7(5):1822-30
7. Clerico C, Lari A, Mojallal A, Boucher F. Anatomy and Aesthetics of the Labia Minora: The Ideal Vulva? [published correction appears in *Aesthetic Plast Surg* 2017;41(3):714-9.
8. Alter GJ. Pubic contouring after massive weight loss in men and women: correction of hidden penis, mons ptosis, and labia majora enlargement. *Plast Reconstr Surg* 2012;130(4):936-47
9. Menkes S, SidAhmed-Mezi M, Meningaud JP, Benadiba L, Magalon G, Hersant B. Microfat and Nanofat Grafting in Genital Rejuvenation. *Aesthet Surg J* 2021;41(9):1060-7.
10. Jabbour S, Kechichian E, Hersant B, Levan P, El Hachem L, Noel W, Nasr M. Labia Majora Augmentation: A Systematic Review of the Literature. *Aesthet Surg J* 2017;37(10):1157-64.
11. Felicio Yde A. Labial surgery. *Aesthet Surg J* 2007;27(3):322-8.
12. Mottura AA. Labia majora hypertrophy. *Aesthetic Plast Surg* 2009;33(6):859-63
13. Alter GJ. Management of the mons pubis and labia majora in the massive weight loss patient. *Aesthet Surg J* 2009;29(5):432-42.
14. Miklos JR, Moore RD. Simultaneous labia minora and majora reduction: a case report. *J Minim Invasive Gynecol* 2011;18(3):378-80.
15. Ostrzenski A. Labiopexy and labioplasty for labium majus rejuvenation in light of a newly discovered anatomic structure. *Aesthetic Plast Surg* 2014;38(3):554-60.
16. Di Saia JP. An unusual staged labial rejuvenation. *J Sex Med* 2008;5(5):1263-7.
17. El Danaf AAH. Deepithelized fasciocutaneous flap for labia majora augmentation during thigh lift. *Eur J Plast Surg* 2010;33(6):373-6.
18. Salgado CJ, Tang JC, Desrosiers AE. Use of dermal fat graft for augmentation of the labia majora. *J Plast Reconstr Aesthet Surg* 2012;65(2):267-70.