

Atrial flutter in an adolescent glue sniffer

Uçucu madde bağımlısı bir gençte görülen atrial flutter

Sibel Bozabalı

Zülal Ülger

Ertürk Levent

Arif Ruhi Özyürek

Ege University Faculty of Medicine, Department of Pediatric Cardiology, İzmir, Turkey

Abstract

Inhalant abuse is a global social problem which especially affects the younger generation. Glue sniffing is a very common form of inhalant abuse because it is so cheap and readily available. A previously healthy 16-year-old boy was referred to the hospital with abdominal and chest pain. During observation, symptomatic atrial flutter was observed which needed intensive care management. It was learned that the patient was a heavy glue sniffer. The most serious consequence of glue sniffing is sudden death, and cardiac arrhythmias, especially ventricular ones, are the most common causes of death. This is the first documented case report of atrial flutter due to glue sniffing. Adolescents with arrhythmias and myocardial damage should be questioned specifically about inhalant abuse.

Keywords: Glue sniffing, arrhythmia, atrial flutter, adolescent.

Öz

İnhalan bağımlılığı, dünya genelinde özellikle genç jenerasyonu ilgilendiren önemli bir sosyal problemdir. Ucuz ve kolay erişilebilmeleri nedeniyle yapıştırıcı maddelerin keyif verici madde olarak inhale edilmelerine oldukça sık rastlanır. Daha önce sağlıklı olan 16 yaşındaki erkek çocuk, karın ve göğüs ağrısı nedeniyle acil servise başvurdu. İzlemi sırasında yoğun bakım ihtiyacı gerektiren semptomatik atriyal flutter gözlemlendi. Olgunun yoğun miktarda uçucu madde kullandığı öğrenildi. Yapıştırıcı madde bağımlılığının en korkulan sonucu özellikle ventriküler aritmilere bağlı olarak ortaya çıkan ani ölümdür. Burada yapıştırıcı madde inhalasyonuna bağlı olarak ortaya çıkan ve ilk kez yayınlandığı düşünülen atriyal flutterlu bir olgu sunulmuştur. Farklı aritmiler ve myokard hasarı gözlenen genç erişkinlerde inhaled madde kullanımı özellikle sorgulanmalıdır.

Anahtar Sözcükler: Yapıştırıcı koklama, aritmi, atriyal flutter, genç.

Introduction

Inhalant abuse is a social problem all around the world and especially affects the younger generation. Glue sniffing is a very common form of inhalant abuse because it is cheap and available in various household products (1-3). Glue sniffing may cause sudden death due to the arrhythmogenic effects of components such as toluene and 1,1,1-trichloroethane. Ventricular dysrhythmias are most common, resulting from the sensitization of the myocardium to catecholamines. Sinus bradycardia or hypoxia-induced heart block may also occur (1,2,4), though atrial arrhythmias are rarely seen. With the informed consent of the patient, we report here a very rare type of dysrhythmia, atrial flutter, due to glue sniffing in an adolescent. To our knowledge, this is the first reported case of atrial flutter due to glue sniffing.

Case Report

A previously healthy 16-year-old boy was referred to the hospital with fever, diarrhea, and abdominal pain for the last 3 days. He also developed chest pain which was more pronounced during inspiration. His physical examination was normal at admission. Creatine kinase (CK), CK-MB, and troponin-T levels were also normal, while electrocardiogram (ECG) showed a minimal ST segment elevation (1 mm) in the left precordial derivations. Six hours after hospitalization, his chest pain became the main complaint. He seemed to be anxious, painful, and sweaty. His cardiac enzymes levels had increased to CK: 1406 IU/dL, CK-MB: 121 IU/dL, and troponin-T: 2.45 ng/mL. ST segments at V4-V5-V6 derivations were elevated 6 mm (Figure-1A). Echocardiographic examination showed left ventricular dilatation, 45% ejection fraction, and minimal mitral regurgitation. Ten hours after hospitalization, symptomatic atrial flutter followed by supraventricular tachycardia (SVT) was observed and required intensive care management (Figure-1B). Acetyl salicylic acid, isosorbide dinitrate, aldactazide, enalapril, digoxin, and

Corresponding Author: Sibel Bozabalı

Ege University Faculty of Medicine, Department of Pediatric Cardiology, İzmir, Turkey

Received: 15.03.2016

Accepted: 04.04.2016

metoprolol were given as medication. Cardiac magnetic resonance imaging (MRI) revealed linear contrast enhancement of the left ventricular lateral wall and inferior side, indicating myocarditis. Coronary arteries appeared normal on computed tomograph (CT) angiography.

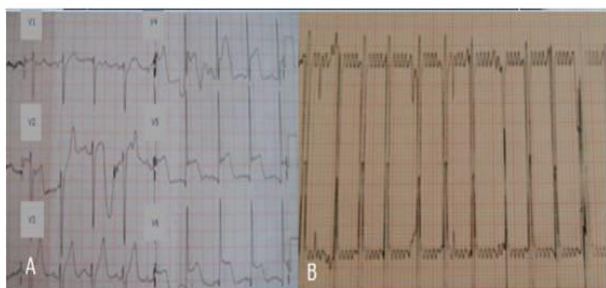


Figure-1.ECG views in the acute stage of the case. **A)** ST segment elevation in V4-V5-V6 derivations showing the acute coronary ischemia, **B)** Atrial flutter

The lipid profile was also normal. Because there was no reason for this scenario, the patient was repeatedly asked about inhalant abuse and the reason for this clinical status was determined. He reported being a heavy glue sniffer for the last 4 years, sniffing 3-4 packets of glue (40 g/packet) per day. There were no other clinical findings related to other systems (respiratory, gastrointestinal or neurological) which would be expected to be affected by glue. Four days after the administration, both the cardiac enzyme levels and the ECG became normal. The left ventricular ejection fraction was measured 65% in control echocardiographic examination.

Written informed consent was obtained from the patient's legal custodian for publishing the individual medical records.

Discussion

In this article, we report a glue-sniffing adolescent with various cardiac complications like myocarditis, arrhythmia and coronary vasospasm. Although the dysrhythmias seen in glue sniffers are usually ventricular, we observed atrial flutter, which has not been previously reported. Asking young patients with symptoms of coronary heart disease about substance abuse is very important in order to solve the clinical and social problem of inhalant abuse.

Adhesive glues as well as correction fluids, paint thinners, and aerosol paints contain toluene, n-hexane,

methyl ketones, chlorohydrocarbons, and benzene. These substances can be found very easily and used as pleasure-giving inhalants, usually among individuals in low socioeconomic areas. A study from our country reported that the prevalence of paint thinner and adhesive abuse was 73% among homeless children and 5% among students in their second year of high school (3). In the West (e.g. the United Kingdom and United States), 5-20% of children have experimented with inhalants (1-4).

The most common substance in inhalants is toluene. In Turkey, different types of paint thinners and adhesives contain 50-70% and 35-40% toluene (3). It is very difficult to identify inhalant users. Most of the symptoms are nonspecific like dizziness, irritability, tiredness, loss of appetite, headache, photophobia, or cough and can be seen in other illnesses or syndromes (2). Our patient also demonstrated nonspecific complaints at admission. However, during observation the clinical and laboratory findings pointed to myocardial infarction, which is not seen frequently in pediatric patients and led us to suspect substance abuse as a factor.

Cardiac arrhythmias are the most common causes of sudden sniffing death due to the sensitization of the myocardium to catecholamines. Ventricular arrhythmias in particular are attributed to this sensitization (5). In animal studies, some volatile compounds act directly on the heart to reduce sinoatrial node automaticity, prolong PR interval, and induce atrioventricular block (4). Very few cases reported atrial arrhythmia as atrial fibrillation (6). In our patient, we observed atrial flutter which was not reported before.

Although sudden death may be due to its arrhythmogenic effects, glue may also damage the heart by causing chronic myocarditis, which is detected as myocardial edema, irreversible myocarditis, fibrosis, and congestive heart failure in autopsies (1,7,8). In our patient, myocarditis and cardiac failure were reported at admission but the left ventricular ejection fraction returned to normal within a week. Therefore, we thought that myocardial dysfunction, demonstrated by a 45% left ventricular ejection fraction, was due to the acute arrhythmogenic effect and acute coronary vasoconstriction on the basis of chronic myocardial damage.

In conclusion, adolescent patients exhibiting different arrhythmias and myocardial damage should be specifically questioned about substance abuse.

References

1. Meadows R, Verghese A. Medical complications of glue sniffing. *South Med J* 1996;89(5):455-62.
2. Anderson CE, Loomis GA. Recognition and prevention of inhalant abuse. *Am Fam Physician* 2003;68(5):869-74.
3. Vural M, Ögel K. Uçucu maddelerin kalp üzerine etkileri. *Bağışıklık Dergisi* 2005;6(3):142-6.

4. Ghuran A, Nolan J. Recreational drug misuse: Issues for the cardiologist. *Heart (British Cardiac Society)*. 2000;83(6):627-33.
5. Cunningham SR, Dalzell GW, McGirr P, Khan MM. Myocardial infarction and primary ventricular fibrillation after glue sniffing. *Br Med J* 1987;294(6574):739-40.
6. Kaufman JD, Silverstein MA, Moure-Eraso R. Atrial fibrillation and sudden death related to occupational solvent exposure. *Am J Ind Med* 1994;25(5):731-5.
7. Wiseman MN, Banim S. "Glue sniffer's" heart? *Br Med J* 1987;294(6574):739.
8. Mee AS, Wright PL. Congestive (dilated) cardiomyopathy in association with solvent abuse. *J R Soc Med* 1980;73(9):671-2.