






## Peritoneal carcinomatosis of the cutaneous malignant melanoma: A report of very unusual case and review of the literature

*Kutanöz malign melanomanın peritoneal karsinomatozisi: Çok nadir görülen bir olgu sunumu ve literatür taraması*

Özge Kömürcü Karuserci<sup>1</sup>  Seyhun Sucu<sup>1</sup>  Betül Ögüt<sup>2</sup>   
Suna Erkiç<sup>2</sup>  Özcan Balat<sup>1</sup> 

<sup>1</sup> Gaziantep University Faculty of Medicine, Department of Obstetrics and Gynecology, Gaziantep, Turkey

<sup>2</sup> Gaziantep University Faculty of Medicine, Department of Pathology, Gaziantep, Turkey

### Abstract

Peritoneal carcinomatosis of the cutaneous malignant melanoma is an extremely rare condition. This is the fourth such case of the metastatic cutaneous malignant melanoma mimicking peritoneal carcinomatosis of the ovary.

**Keywords:** Peritoneal carcinomatosis, cutaneous malignant melanoma, ovary.

### Öz

*Kutanöz malign melanomanın sebep olduğu peritoneal karsinomatozis nadir bir durumdur. Bu yazıda metastatik kutanöz malign melanomanın ileri evre over kanserine bağlı peritoneal karsinomatozis gibi klinik bulgu verdiği bir olgu sunulmuştur ve literatürdeki dördüncü vakadır.*

**Anahtar Sözcükler:** Peritoneal karsinomatozis, kutanöz malign melanoma, over

### Introduction

Cutaneous malignant melanoma is a destructive malignancy initiating from melanocytes of the skin with has a wide metastasis profile. It accounts for approximately 3% of all malignancies reported in Europe. The tumor generally spreads from skin to the lymph nodes (42-59%), lungs (18-36%), liver (14-20%), brain (12-20%), and skeletal bones (11-17%) (1, 2). Less frequent sites include the eye, dura, pleura, duodenum, uterine cervix, and vagina. Nevertheless, peritoneal carcinomatosis of a malignant melanoma has been reported limited edition.

We report an exceptional case of peritoneal carcinomatosis originating from malignant cutaneous melanoma metastasis to the adnex, omentum, and uterus that was initially considered to be ovarian carcinoma. A review of the recent literature is also provided.

### Case Report

A 43-year-old woman was referred to our clinic with lower abdominal pain and distension with weight loss over six months and reduced appetite. Examination revealed tenderness and fullness in the abdomen and pelvis. Transvaginal ultrasonography revealed a 125x78 mm solid mass, indistinguishable from the uterus and common ascites in the pelvis. Computerized tomography (CT) revealed solid lesions, the largest 10 cm in size, in front of the uterus and in the left paracervical space, together with peritoneal implants, ascites and bilateral multiple inguinal lymph nodes. No abnormal findings were determined at colonoscopy or upper endoscopy.

Frozen section biopsy of the ovaries was reported as malignant, but it was not clear whether this was primary or metastasis. Total abdominal hysterectomy, bilateral salpingo-oophorectomy, omentectomy, and peritonectomy was performed.

Corresponding author: Özge Kömürcü Karuserci  
Gaziantep University Faculty of Medicine, Department of  
Obstetrics and Gynecology, Gaziantep, Turkey  
E-mail: ozgekomurcu@hotmail.com

Received: 29.08.2018 Accepted: 03.10.2018

Macroscopically, the right salpingo-oophorectomy specimen was the largest tumor nodule at 15 cm in diameter. Histological examination revealed a malignant tumor within the peritoneum, myometrium, bilateral ovaries, and fallopian tubes, but not the endometrium or uterine cervix. Immunohistochemically, tumor cells stained with S100, HMB45, MART-1, and SOX10 and no reaction was determined with cytokeratin, CD34, desmin, actin, calretinin, ER, PR or inhibin-A. The histopathological diagnosis was melanoma (Figure-1). Ascites fluid cytopathology was also reported as malignant.

Physical examination revealed a suspected, irregular nevus-like lesion in her back. The patient was transferred to the department of plastic surgery for skin excisional biopsy. Histopathological diagnosis was superficial spreading melanoma and V600 mutations in the serine–threonine protein kinase B-RAF (BRAF) were observed in the tumor cells. The patient was afterwards transferred to the department of oncology for Vemurafenib (PLX4032) treatment

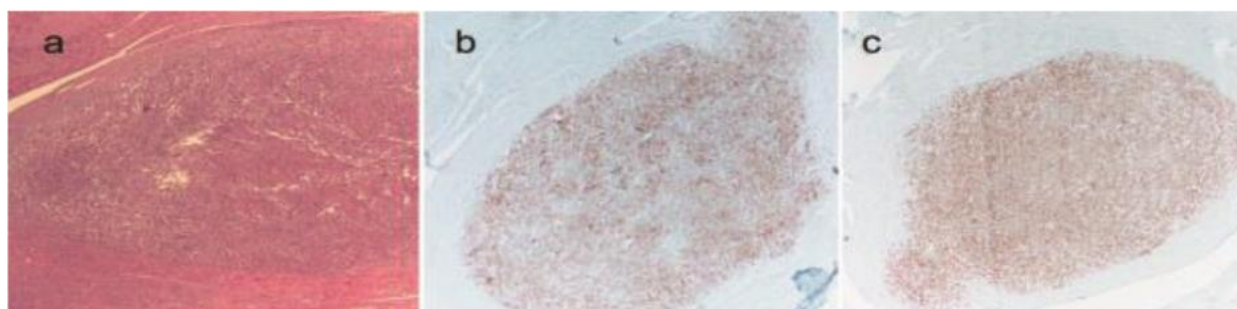
which frequently provides tumor regression in patients with BRAF V600–mutation and improved survival time (3).

## Discussion

Cutaneous malignant melanoma metastasis to the peritoneum is a rare condition, only three cases of which have previously been reported (4-6).

To the best of our knowledge, this is the fourth case of a malignant melanoma with peritoneal carcinomatosis mimicking advanced ovarian cancer. Clinical characteristics, age ranges and origins were very similar in all cases, but two (4, 6) were reported as recurrence of malignant melanoma, and one (5) was identified after exploratory laparotomy for peritoneal carcinomatosis, as our case.

In conclusion, although very rare, metastatic malignant melanomas may cause pelvic spread and peritoneal carcinomatosis, mimicking advanced stage ovarian cancer, especially in young women.



**Figure-1. a)** Melanoma in the myometrium, H&E staining x40.

**b-c)** Tumor cells stained with SOX-10 and MART-1, respectively, x40.

## References

- 1- Luckraz H, Morgan M, Gibbs AR, Butchart EG. Pseudomesothelioma resulting from metastatic malignant melanoma. *Eur J Cardiothorac Surg* 2005; 28 (4): 655-6.
- 2- Loewenthal B, Shiau MC, Garcia R. Metastatic melanoma: an unusual diagnosis for a large anterior mediastinal mass. *Radiographics* 2004; 24 (6): 1714-8.
- 3- Sosman JA, Kim KB, Schuchter L, Gonzales R, Pavlick AC, Weber JS, et al. Survival in BRAF V600–mutant advanced melanoma treated with vemurafenib. *N Engl J Med* 2012; 366 (8): 707-14.
- 4- Lee EY, Heiken JP, Huettner PC. Late recurrence of malignant melanoma presenting as peritoneal “carcinomatosis”. *Abdom Imaging* 2003; 28 (2): 0284-6.
- 5- Lee ES, Ahn JH, Lee TS, Jeon HW. Metastatic malignant melanoma with peritoneal seeding in a young woman: A case report. *Obstet Gynecol Sci* 2014; 57 (3): 240-3.
- 6- Sano M, Hashiguchi Y, Yasui T, Sumi T, Wakasa K, Ishiko O. Late recurrence of malignant melanoma mimicking primary peritoneal cancer. *Eur J Gynaecol Oncol* 2013; 34 (3): 265-8.