

## Intestinal obstruction caused by internal herniation as a complication of Meckel's diverticulum

### *Meckel divertikülünün bir komplikasyonu olarak internal herniasyona bağlı bağırsak tıkanması*

Osman Erdoğan<sup>1</sup>  Ahmet Gökhan Sarıtaş<sup>2</sup>  Zafer Teke<sup>1</sup>   
Levent Bolat<sup>2</sup>  İshak Aydın<sup>2</sup> 

<sup>1</sup> Cukurova University, Faculty of Medicine, Department of Surgical Oncology, Adana, Turkey

<sup>2</sup> Cukurova University, Faculty of Medicine, Department of General Surgery, Adana, Turkey

### Abstract

Meckel's diverticulum is a prevalent congenital anomaly of the digestive system, with an incidence of approximately 1-3% in the population. Intestinal obstruction is a widespread complication in adults. Patients are often operated on with a preliminary diagnosis of acute abdomen, and Meckel's diverticulum are usually diagnosed during the operation. The surgical technique should be planned according to the condition of the patient. In this article, we aimed to present a case of 68-year-old female with mechanical bowel obstruction caused by internal herniation of small intestine as a complication of Meckel's diverticulum.

**Statement:** Oral presentation at V. International Congress on Natural and Health Sciences (ICNHS-2019), Adana, Turkey, December 13 to December 15, 2019.

**Keywords:** Meckel's diverticulum, complication, internal herniation, mechanical bowel obstruction, intestinal obstruction.

### Öz

Meckel divertikülü gastrointestinal sistemin en sık rastlanan doğumsal anomalisi olup genel nüfusta yaklaşık %1-3'lük bir oranda görülmektedir. Bağırsak tıkanıklığı yetişkin hastalarda en sık görülen komplikasyondur. Hastalar sıklıkla akut karın ön tanısı ile ameliyat edilir ve Meckel divertikülü genellikle ameliyat sırasında teşhis edilir. Cerrahi teknik hastanın durumuna göre planlanmalıdır. Bu çalışmada Meckel divertikülünün bir komplikasyonu olarak ince bağırsağın internal herniasyonuna bağlı mekanik bağırsak tıkanıklığı olan 68 yaşında bir kadın olguyu sunmayı amaçladık.

**Açıklama:** 13-15 Aralık 2019 tarihlerinde Adana'da düzenlenen V. Uluslararası Doğa ve Sağlık Bilimleri Kongresi'nde (ICNHS-2019) sözlü bildiri olarak sunulmuştur.

**Anahtar Sözcükler:** Meckel divertikülü, komplikasyon, internal herniasyon, mekanik bağırsak tıkanıklığı, bağırsak tıkanıklığı.

### Introduction

Meckel's diverticulum is a prevalent congenital anomaly of the digestive system, seen in 2% to 3% of the population (1). Most of the cases with Meckel's diverticulum are usually asymptomatic.

Meckel's diverticula produce symptoms in only 16% of patients (2). This pathologic lesion may lead to bleeding and intestinal obstruction during childhood, and is incidentally diagnosed in adulthood.

Corresponding author: Osman Erdoğan  
Cukurova University, Faculty of Medicine, Department of  
Surgical Oncology, Adana, Turkey  
E-mail: osman\_erdogan85@hotmail.com  
Application date: 28.02.2020 Accepted: 08.06.2020

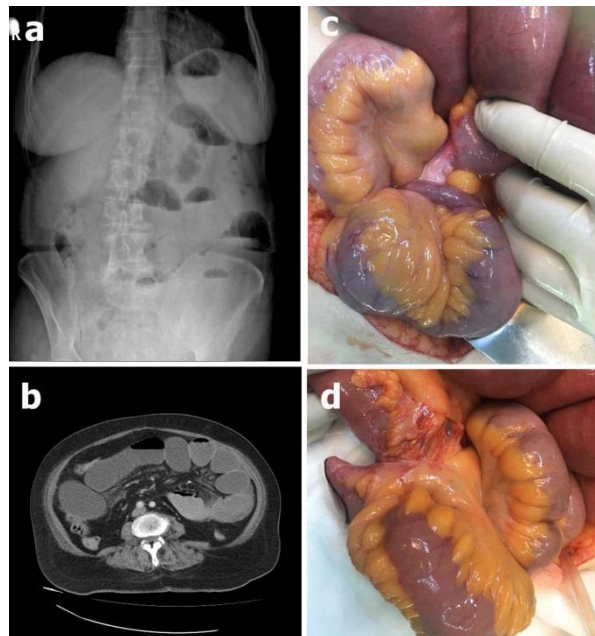
It may present with life-threatening complications. Meckel's diverticulum often presents itself with mechanical bowel obstruction in adults, and intestinal obstruction is usually caused by intussusception due to Meckel's diverticulum. Less common causes of bowel obstruction resulting from Meckel's diverticulum are fibrous bands, Littre's hernia, loop formation, strictures, and volvulus.

Here we present a case of 68-year-old female with mechanical bowel obstruction due to internal herniation of small intestine resulting from Meckel's diverticulum.

### Case Report

A 68-year-old female patient presented to emergency room with abdominal pain, nausea and vomiting, inability to discharge gas and stools for two days. Her past medical history included type 2 diabetes mellitus. Her previous surgical history included appendectomy and cholecystectomy. The patient had no important family history, and denied alcohol usage or smoking tobacco. Physical examination showed an obvious distention in the abdomen, and a rebound tenderness was detected in the lower quadrants of the abdomen upon palpation. Groin examination revealed no hernia on both sides. Digital rectal examination revealed an empty rectal ampulla. Her bowel sounds were hypoactive. White blood cell count was  $15.6 \times 10^3/\mu\text{L}$  (normal range  $3.5 \times 10^3/\mu\text{L}$  -  $9.5 \times 10^3/\mu\text{L}$ ) and a C-reactive protein of 19 mg/L (normal range 0-3 mg/L). Multiple air-fluid levels were seen on the upright abdominal X-ray (Figure-1a). Abdominal and pelvic computed tomography (CT) was performed after the intravenous injection of non-ionic contrast material; no oral contrast material was administered. There were multiple dilated low-attenuation fluid-filled loops of the small bowel (Figure-1b). The patient underwent an emergent median laparotomy because of acute abdomen due to mechanical bowel obstruction. At surgery, a 6-cm length of Meckel's diverticulum was seen on the anti-mesenteric side of the ileal segment located proximally 80 cm away from the ileo-cecal region, which rotated around its axis and adhered to the right lateral abdominal wall (Figure-1c). Because of this rotation, there was a stenosis within the lumen of ileal loop and a partial ischemia was

noticed in the distal part of the diverticulum. Internal herniation of small intestine was observed. The connection between Meckel's diverticulum and lateral abdominal wall was separated by sharp dissection. Internally herniated small bowel loops were reduced and the Meckel's diverticulum was fully exposed (Figure-1d). There was an anomaly of the diverticular mesentery, and a fibrous stenosis of the small intestine just proximal to the diverticulum was noticed. The small bowel segment with margins of at least 5 cm proximally and distally containing Meckel's diverticulum was transected by linear staplers, and then a side-to-side small intestinal anastomosis was done. The patient recovered uneventfully and is doing well at a 3-month follow-up. The histologic examination confirmed the Meckel's diverticulum. No heterotopic tissue was detected in pathologic examination of our patient's resected specimen. Written informed consent was received from the patient.



**Figure-1** (a) Abdominal X-ray revealing gaseous distension of the small bowel in the left upper abdominal area with paucity of gas in the lower abdomen, (b) abdominal CT scan showing multiple dilated fluid-filled loops of small bowel, (c) operative view showing Meckel's diverticulum strangulating the small bowel, and (d) the small bowel including Meckel's diverticulum after full exposure.

## Discussion

An internal hernia is formed by the protrusion of a viscus through a peritoneal or mesenteric aperture, leading to its encapsulation within a compartment of the abdominal cavity. The hernial orifice is usually a preexisting anatomic structure, such as the foramen of Winslow or the paraduodenal fossa. However, congenital anomalies of the intestinal rotation and peritoneal attachments are important factors which predispose to internal herniation. Postsurgical or traumatic defects of the mesentery and omentum are also potential sites for herniation of intestinal loops. Congenital or acquired internal hernias account for 0.6 to 5.8 percent of small bowel obstruction (3). Most commonly, internal hernia occurs through mesentery of small intestine. Meckel's diverticulum causing internal hernia and small bowel obstruction is an extremely rare complication, and it should be considered in patients with obstructive symptoms, especially in younger people without previous abdominal surgery. Haskaraca et al. reported a case of internal hernia through mesentery of Meckel's diverticulum (4). On the other hand, occurrence of internal hernia and intestinal gangrene due to Meckel's diverticulum is rare. Zhang et al. reported a case of a 45-year old female patient who presented with intestinal obstruction and at laparotomy was found to have Meckel's diverticulum with internal hernia causing intestinal gangrene (5). Other causes of internal herniation are due to adhesion of the inflamed tip of Meckel's diverticulum to the corresponding base of mesentery, through mesodiverticular band and fibrous cord extending up to umbilical wall. In our case, Meckel's diverticulum, which rotated around its axis and adhered to the abdominal wall, caused internal herniation of ileal loops with resultant small bowel obstruction.

The symptomatic complications of Meckel's diverticulum fall into three major categories: bleeding, obstruction, and inflammation. Obstruction is the most common presentation in the adult. Intestinal obstruction (37%) is a more common complication than hemorrhage (12%) by a margin of more than 3 to 1 (1). There are various mechanisms by which Meckel's diverticulum can cause intestinal obstruction. Obstructive symptoms caused by a Meckel's diverticulum may occur when either 1) the diverticulum is attached by a fibrous band to the

umbilicus, abdominal wall or other viscera, or 2) the diverticulum is free and unattached. An attached diverticulum is more likely to obstruct than one remaining free (1). Obstruction may be caused by entanglement of the small bowel around a fibrous cord, entrapment of an ileal loop within a mesodiverticular band, intussusception, volvulus, incarceration within a hernia sac, or chronic Meckel's diverticulitis. A mesodiverticular band is a vascular cord running between the diverticulum and the base of the mesentery. It predisposes to obstruction by allowing entrapment of a loop of ileum. Intussusception develops because the diverticulum serves as a lead point following simple invagination. However, inversion of the diverticulum into the gut lumen may occur without producing any symptoms or complications. Only anatomically free diverticula can invaginate. Volvulus occurs when there is a persistent fibrous band, and is related to the shape and degree of fixation of the diverticular tip. Fixation of the tip may also allow torsion of the diverticulum around its own axis. Occasionally, Meckel's diverticula become strangulated within inguinal, or less commonly, femoral or umbilical hernias. This has been termed a Littre's hernia after the author who originally described three cases of incarceration of small bowel diverticula within femoral hernias (1). A chronically inflamed Meckel's diverticulum can cause obstruction when the inflammation extends to the adjacent small intestine, producing cicatricial narrowing. Other mechanisms involve rare causes of obstruction like tumors (lipomas, leiomyomas, carcinoid tumors etc.), impacted meconium in neonates causing inflammatory adhesions of Meckel's diverticulum to surrounding structures leading to volvulus, gallstone ileus, and obstruction secondary to phytobezoar formation in the Meckel's diverticulum (6). Meckel's diverticulum lithiasis, which is the formation of stones in Meckel's diverticulum, can cause small bowel obstruction by two mechanisms: (1) it can cause impaction in the terminal ileum after its extrusion from the diverticulum and (2) by promoting local inflammation of the diverticulum and intussusception. In our case, a 6-cm length of Meckel's diverticulum, which rotated around its axis and adhered to the abdominal wall, was the cause of obstruction. Because of this rotation, there was a stenosis in the lumen of the ileal segment and a partial ischemia was noticed in

the distal part of the diverticulum. Eventually, an internal herniation of ileal loops developed, thereby resulting in small bowel obstruction which caused symptoms.

The management of Meckel's diverticulum remains controversial. Elective surgery is not recommended for cases where the diverticulum is discovered incidentally on radiological imaging. Today, there is consensus that complicated Meckel's diverticulum is treated with surgical resection, but the optimal treatment of incidentally found Meckel's diverticulum is still a subject of debate. The diverticula attached by bands, or with palpable thickenings suggestive of ectopic tissue should be excised if the circumstances of the original laparotomy allow. A wide-mouthed, thin-walled unattached diverticulum in an adult patient can probably be quite safely left alone. Turgeon and Barnett reported additional factors necessitating surgical resection: palpable mass within the diverticulum suggesting ectopic tissue or tumor, a fibrous connection to the umbilicus that predisposes to volvulus and obstruction, presence of a vitelline vessel lacking a mesentery predisposing to incarceration, and a narrow diverticular neck predisposing to inflammation and obstruction (1). Nowadays, a set of convincing criteria that can be used to decide whether to excise or leave Meckel's diverticulum intact have been proposed. In their analysis of 1476 patients with Meckel diverticulum diagnosed and treated in the Mayo Clinic between 1950 and 2002, Park et al. found that (1) patient age younger than 50 years; (2) male sex; (3) diverticulum length greater than 2 cm; and (4) ectopic or abnormal features within a diverticulum were all associated with symptomatic diverticula (2). They recommended removing all incidental diverticula that fulfill any of these 4 criteria. The two further features that necessitate "preventive" excision of an accidentally found unaffected Meckel's diverticulum include (1) narrow-neck diverticulum, which creates a risk of food residue clogging, and (2) connection of the top of the diverticulum with the umbilicus with a connective tissue band. Additionally, pronounced thickening of the diverticulum wall is an argument for its removal. The absence of any of those features indicates a minimal risk of developing complications in the future and supports leaving the diverticulum intact. Moreover, a silent Meckel's diverticulum

may not take precedence over immediate matters of life and death. Other circumstances in which its excision may be risky include (1) local or diffuse peritonitis (e.g. gangrenous peritonitis, perforated appendix, or large bowel perforation), (2) injuries of other abdominal organs in a patient with multiorgan trauma, (3) old age, (4) patient instability and (5) presence of ascites (7). In such circumstances, it is better not to excise the diverticulum, but to record its presence in the surgery report and patient's discharge summary.

The surgical options of Meckel's diverticulum include simple diverticulectomy, wedge resection or segmental resection, done laparoscopically or with laparotomy. An unresolved question is whether a simple diverticulectomy is sufficient for removing a Meckel's diverticulum or a Meckel's diverticulum removed with a small-bowel resection is the best choice. Park et al. recommended that if a palpable mass is identified at the base of a Meckel's diverticulum, the resection margin must be free of the entire mass (2). For all other Meckel diverticula without a palpable mass, a simple diverticulectomy should be sufficient. Blouhos et al. aimed to make a decision algorithm concerning optimal treatment of symptomatic Meckel's diverticulum (8). They state that the type of surgery depends on (a) integrity of diverticulum base and adjacent ileum and (b) the presence and location of ectopic tissue. Generally, a wedge resection of the diverticulum is performed and sometimes an end-to-end anastomosis is applied following the resection of an ileum segment. Actually, the extent of resection is determined according to the intraoperative findings and any intraoperative complications. When resection is to be performed for an incidentally discovered Meckel's diverticulum, diverticulectomy can be performed for long diverticula and wedge or segmental resection for short diverticula (2). Segmental resection of the associated small bowel with end-to-end anastomosis is preferred to prevent the risk of intestinal stenosis in patients with broad-based diverticulum or if heterotopic tissue is palpated or if there are ischemic or inflammatory changes in the ileum adjoining the diverticulum, whereas simple diverticulectomy can be performed in patients with a narrow-based diverticulum or if there is no palpable mass within the lumen of the ileum. Depending on the size and location of benign tumors within the

diverticulum, simple diverticulectomy is sufficient. However, involvement of the Meckel's diverticulum by malignant tumors necessitates wider intestinal resection along with the lymphatic pathways of the mesentery. Ileal resection is also advisable if the base of diverticulum is edematous, inflamed or perforated. Diverticulectomy with segmental resection of the ileum should be preferred in bleeding Meckel's diverticulum to ensure full resection of any ectopic gastric tissue and intestinal ulcer. Peptic ulcers resulting from ectopic gastric acid production are often located in the ileum rather than the Meckel's diverticulum itself, due to peristaltic activity in the Meckel's and the resistance of the ectopic gastric tissue to the acid it produces.

The emergency surgical treatment of complicated Meckel's diverticulum depends on the type and extent of complications or intraoperative findings. It is quite difficult to diagnose in the preoperative period due to the association of many diseases and symptoms. Patients are usually operated with the diagnosis of acute abdomen and are usually diagnosed during the operation. The operation should always include resection of the diverticulum or a segment of the bowel affected by the pathology. For instance, most authors recommend a segmental small bowel resection of the invaginated part as surgical treatment of adult intussusception due to Meckel's diverticulum. Also, segmental resection should be preferred in patients operated for bleeding because the ectopic tissue in the diverticulum may continue in the neighboring bowel loops. Blouhos et al. recommended that, when the indication of surgery is complicated intestinal obstruction, the preferred surgical approach should be wedge resection or segmental resection (8). Although it is extremely rare for the Meckel's diverticulum to cause internal hernia leading to intestinal obstruction, the surgical management of internal hernia caused by Meckel diverticulum does not basically differ from the surgical treatment of other major complications of Meckel's diverticulum. Ağca et al. reported a 27-year old male patient who had internal herniation of the small bowel and subsequent ileus resulting from Meckel's diverticulum (9). They reduced small intestinal loops and then excised the diverticulum by using the 45-mm linear stapler. Narjis et al. reported a 24-year old male patient who was

found to have a 10-cm-long non-cyanotic segment of the small bowel that was strangulated by a Meckel's diverticulum (10). They reduced the small bowel and did a small bowel resection with Meckel's diverticulum. Our patient was operated on with the diagnosis of intestinal obstruction due to internally herniated loops of small bowel resulting from Meckel's diverticulum. At laparotomy, a partial ischemia was noticed in the distal part of the diverticulum and there was a fibrous stenosis of the small intestine just proximal to the diverticulum. Therefore, the entrapped intestinal loops were firstly reduced by manual traction in our case, and then resection of a short segment of the ileum with Meckel's diverticulum followed by side-to-side anastomosis was performed. No ectopic tissue was found in pathological examination of our patient's resected specimen.

Medico-legal problems regarding excised or remaining Meckel's diverticulum were not addressed in any of the papers published in the literature (7). It seems important in the time of widespread claims by patients due to the outcomes of a surgical intervention or complications that are not in line with their expectations. There are two possible scenarios for such claims: the occurrence of a postoperative complication (leakage, early adhesion and obstruction) in a patient who had an unaffected diverticulum and the occurrence of complications (bleeding, intestinal obstruction, inflammation) in a patient who, usually years before, was left with an accidentally found diverticulum and this information was noted in his or her medical records. In both situations it is possible to accuse the surgeon of incompetence or lack of due diligence. The first allegation concerns the legitimacy of excising pathologically unchanged anomaly, while the second scenario concerns the decision to leave it. It should be clearly stated that both procedures are correct and consistent with current medical knowledge. The above-mentioned indications for removing or leaving the diverticulum are, in some circumstances, relative and need not be absolutely implemented. Every surgeon can safely choose one of the two options, depending on the individual patient's situation.

In conclusion, Meckel's diverticulum and related complications should be kept in mind in cases followed with the diagnosis of acute abdomen.

Intestinal obstruction is the most common complication of Meckel's diverticulum (1, 2). A preoperative diagnosis is not usually possible in view of the non-specific nature of the clinical and radiological findings. The possibility of an internal hernia should be considered in cases of acute or intermittent small bowel obstruction, particularly

in the absence of an external hernia or the history of previous abdominal surgery. The surgical technique should be planned according to the condition of the patient.

**Conflict of interest:** The authors have not declared any conflict of interest in this study.

## References

1. Turgeon DK, Barnett JL. Meckel's diverticulum. *Am J Gastroenterol* 1990; 85 (7): 777-81.
2. Park JJ, Wolff BG, Tollefson MK, Walsh EE, Larson DR. Meckel diverticulum: the Mayo Clinic experience with 1476 patients (1950-2002). *Ann Surg* 2005; 241 (3): 529-33.
3. Newsom BD, Kukora JS. Congenital and acquired internal hernias: unusual causes of small bowel obstruction. *Am J Surg* 1986; 152 (3): 279-85.
4. Haskaraca MF, Ozsoy M, Bal A, et al. A rare complication of Meckel's diverticulum: coexistence of ileus and diverticulitis. *Kocatepe Med J* 2015; 16 (1): 95-7.
5. Zhang Y, Guo Y, Sun Y, Xu Y. An internal hernia caused by Meckel's diverticulum: a case report. *BMC Gastroenterol* 2020; 20 (1): 69.
6. Sharma RK, Jain VK. Emergency surgery for Meckel's diverticulum. *World J Emerg Surg* 2008; 3: 27.
7. Żyluk A. Management of incidentally discovered unaffected Meckel's diverticulum - a review. *Pol Przegl Chir* 2019; 91 (6): 41-6.
8. Blouhos K, Boulas KA, Tsalis K, et al. Meckel's diverticulum in adults: surgical concerns. *Front Surg* 2018; 5: 55.
9. Ağca B, Beyaz Y, Tezer H, Elmalı N, Kamalı S. A rare cause of ileus in adults: internal herniation due to Meckel's diverticulum. *Eur Arc Med Res* 2013; 29 (3): 168-71.
10. Narjis Y, Halfadl H, Agourram A, Rabbani K, Finech B. A rare internal herniation in adult: Meckel's diverticulum. *Indian J Surg* 2014; 76 (1): 5-7.