





A case of bilateral Sertoli cell adenoma in androgen insensitivity syndrome

Androjen duyarsızlık sendromunda bilateral Sertoli hücreli adenom olgusu

Zeynep Öztürk İnal¹  Nursadan Gergerlioğlu²  İlknur Küçükosmanoğlu²  Meryem İlkay Karanis² 

¹Konya Training and Research Hospital, Clinic of Obstetrics and Gynecology, Konya, Turkey

²Konya Training and Research Hospital, Clinic of Pathology, Konya, Turkey

Abstract

Androgen insensitivity syndrome, previously referred to as testicular feminization syndrome, is an X-linked recessive disorder that is characterized by a mutation in the q11-q12 region of the X chromosome, which results in a deformed androgen receptor gene. Patients with androgen insensitivity syndrome may develop testicular tumors, especially seminomas after puberty. A 35-year-old female patient presented with the complaint of primary amenorrhea and had masses of approximately 4 cm size palpated in the bilateral inguinal regions. The masses were excised and the histopathological examination was reported as bilateral Sertoli cell adenoma. Although the risk of bilateral gonadal tumor development is low in patients with androgen insensitivity syndrome, such malignancies should not be disregarded.

Keywords: Sertoli cell adenoma, androgen insensitivity syndrome.

Öz

Önceden testiküler feminizasyon sendromu olarak isimlendirilen androjen duyarsızlık sendromu androjen reseptör gen üzerinde lokalize X kromozomundaki q11-q12 mutasyonunun bulunduğu, X'e bağlı geçiş gösteren resesif bir hastalıktır. Androjen duyarsızlık sendromlu hastalarda puberteden sonra testiküler tümörler, özellikle de seminom gelişebilmektedir. Primer amenore şikayeti ile başvuran 35 yaşındaki hastamızın bilateral inguinal bölgede palpasyonla ele gelen yaklaşık 4 cm'lik kitlenin, eksizyon sonucu histopatolojik değerlendirilmesinde bilateral Sertoli hücreli adenom olarak rapor edilmiştir. Androjen duyarsızlık sendromlu hastalarda bilateral gonadal tümör gelişim riski düşük olsa da bu tür malignitelerin de görülebileceği göz ardı edilmemelidir.

Anahtar Sözcükler: Sertoli hücreli adenom, androjen duyarsızlık sendromu.

Introduction

Androgen insensitivity syndrome, previously named testicular feminization syndrome, is an X-linked recessive disorder that is characterized by a mutation in the q11-q12 region of the X chromosome, which results in a deformed androgen receptor gene (1,2). As a result of androgen resistance, patients exhibit different phenotypes according to varying degrees of feminization (3). Patients affected by this syndrome are at risk of developing gonadal tumors depending on the degree of virilization (1,2,4). Testicular tumors and particularly seminomas may be observed in these patients after puberty. Malignancies such as Sertoli cell tumor, yolk sac tumor, embryonic teratoma or non-classified sex cord stromal tumors are rare in this group of patients (3).

Many authors have reported a maternal inheritance in androgen insensitivity syndrome that have affected many members of the family (3,4). The risk of testicular neoplasia development is 3.6% before 25 years of age and 33% at 50 (3). Therefore, if androgen insensitivity syndrome is detected before puberty, gonadectomy should be performed after pubertal development in order to support the development of feminization (3). Herein, we present a case of bilateral Sertoli cell adenoma in a 35-year-old female with primary amenorrhea in the resected gonads.

Case Report

A 35-year-old married female patient presented to the gynecology clinic with the complaints of primary amenorrhea and inguinal pain. The physical and gynecological examinations of the patient revealed masses of approximately 4 cm size, palpated in the bilateral inguinal regions. The uterus and the ovaries could not be visualized on the US examination; mild

Corresponding Author: Zeynep Öztürk İnal

Konya Training and Research Hospital, Clinic of Obstetrics and Gynecology, Konya, Turkey

Received: 02.08.2016

Accepted: 31.08.2016

axillary hair growth was observed and the bilateral mammary development was accepted as normal. The vagina of the patient with a normal vulvar and perineal appearance had a dead end and the vaginal length was 6 cm. Cervix was not visualized. The masses excised from the bilateral inguinal regions were sent to the pathology department.

Macroscopic incisions were performed on the approximately 4x3x2 cm sized gonads having 4 ductus deferens on them with 4 cm length and 0.2 cm diameter. Grey nodular areas were detected on the testicular section surfaces, the largest having a size of 1 cm and the smallest having a size of 0.4 cm.

Histopathological examination of both gonadal tissues revealed adenomatous lesions formed by the nodular proliferation of immature seminiferous tubules without lumens covered by immature Sertoli cells. The extra-nodular areas included immature tubules and Leydig cells (Figure-1). The patient was diagnosed as bilateral Sertoli cell adenoma and hormone replacement therapy was begun.

Written informed consent was obtained from the patient for publishing the individual medical records.

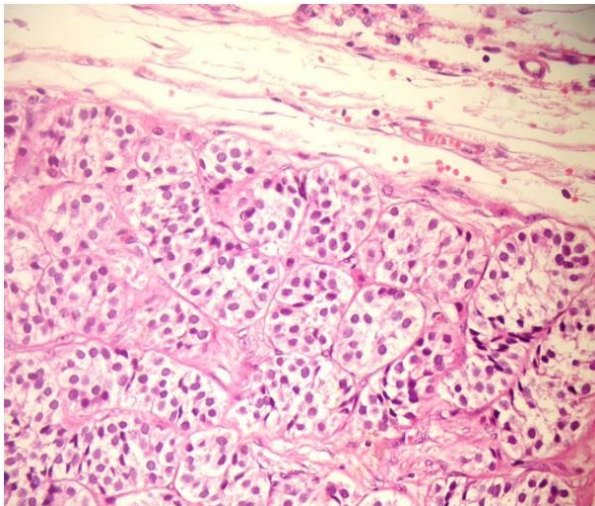


Figure-1. Adenomatous lesions formed by the nodular proliferation of immature seminiferous tubules without lumens covered by immature Sertoli cells.

Discussion

Androgen insensitivity syndrome is a rare form of male pseudo hermaphroditism. It may be classified as complete and incomplete forms. The incidence of the complete form has been reported to be 1/20.000-64.000, which is 10-folds that of the incomplete form (1,3,5). Complete androgen insensitivity syndrome (CAIS) is a condition that results in the complete inability of the cell to respond to androgens. The unresponsiveness of the cell to the presence of androgenic hormones prevents

the masculinization of male genitalia in the developing fetus, as well as the development of male secondary sexual characteristics at puberty, but does not significantly impair female genital or sexual development. Partial androgen insensitivity syndrome (PAIS) is a condition that results in the partial inability of the cell to respond to androgens. The partial unresponsiveness of the cell to the presence of androgenic hormones impairs the masculinization of male genitalia in the developing fetus, as well as the development of male secondary sexual characteristics at puberty, but does not significantly impair female genital or sexual development. Recognition that patients with complete androgen insensitivity syndrome (CAIS) have profound resistance to the action of androgen came from studies in which affected women were found to be resistant to the virilizing action of exogenous androgen. This hormone resistance was found to be due to defects in androgen receptor (AR) function as a result of studies of women with CAIS who had no detectable AR binding, qualitatively abnormal AR binding, or decreased amounts of qualitatively normal receptor binding. Similar findings were described in patients with the less severe phenotypes (1-3). The phenotype was complete female in our case.

Symptoms such as primary amenorrhea, inguinal swelling, and inguinal hernia are observed in patients with androgen insensitivity syndrome as in our case. Related to the androgen insensitivity syndrome, many types of tumors have been defined, especially in the post-pubertal patients. The origin of the tumor may be testicular germ cells, testicular stromal cells or other mesenchymal cells (1,4,6). Benign neoplastic tissue may be observed in approximately 20-23% of the cases. A form of this is multiple or bilateral well-contoured yellowish hamartomatous nodules including Sertoli cell groups and defined as Sertoli cell adenoma (1). Due to the low risk of gonadal tumor development before puberty, many clinics recommend gonadectomy after puberty or in early adulthood in patients with androgen insensitivity syndrome (1,5,7). Gonadectomy was performed in our case. Slijper et al. (8) detected feelings such as surprise, anger or guilt upon the first diagnosis in these patients and relatives; thus, the diagnosis should be carefully declared.

Bilateral Sertoli cell adenoma and concomitant serous cystadenoma or paratesticular leiomyoma have been reported in the literature, but no such co-existence was the case for our patient. However, it should be considered that different lesions may be observed on the histopathological examination (1,3,8,9).

References

1. Siminas S, Kokai G, Kenny SE. Complete androgen insensitivity syndrome associated with bilateral Sertoli cell adenomas and paratesticular leiomyomas: Case report and review of the literature. *J Pediatr Urol* 2013;9(1):31-4.
2. Hughes IA, Deeb A. Androgen resistance. *Best Pract Res Clin Endocrinol Metab* 2006;20(4):577-98
3. Baksu A, Kabukcuoglu F, Baksu B, Goker N. Bilateral Sertoli cell adenoma and serous cyst in a patient with androgen insensitivity syndrome. *Europ Jour of Obst and Gynand Reproductive Biol* 2004;114(1):104-7.
4. Cools M, Drop SLS, Wolffebuttel KP, Oosterhuis JW, Looijenga LH. Germ cell tumours in the intersex gonad: Old paths, new directions, moving frontiers. *Endocr Rev* 2006;27(5):468-84.
5. Boehmer AL, Brinkmann O, Brüggewirth H, et al. Genotype versus phenotype in families with androgen insensitivity syndrome. *J Clin Endocrinol Metab* 2001;86(9):4151-60.
6. Fallat ME, Donahoe PK. Intersex genetic anomalies with malignant potential. *Curr Opin Pediatr* 2006;18(3):305-11.
7. Bouvattier C. Androgen receptor defects: Syndromes of androgen insensitivity. Disorders of sex development: endocrine aspects. In: Gearhart, Rink, Mouriquand, editors. *Pediatric Urology*. 2nd ed. Philadelphia: Saunders Elsevier; 2010:472-3.
8. Slijper FM, Frets PG, Boehmer AL, Drop SL, Niermeijer MF. Androgen insensitivity syndrome(AIS): Emotional reactions of parents and adult patients to clinical diagnosis of AIS and its confirmation by androgen receptor gene mutation analysis. *Horm Res* 2000;53(1):9-15.
9. Vega IF, Juanes JS, Pravia CG. Bilateral Sertoli cell adenoma in gonads, associated with serous cystadenoma. *Pol J Pathol* 2014;65(2):154-6.