

Variant anatomy of sciatic nerve and their clinical implications

Siyatik sinirin varyasyon anatomisi ve klinik yansımaları

Z. Aslı Aktan İkiz^{ID} Okan Bilge^{ID} Hülya Üçerler^{ID} Servet Çelik^{ID} Erengül Boduç^{ID}

Ege University Faculty of Medicine, Department of Anatomy, İzmir, Turkey

Abstract

Aim: The aim of present study was to demonstrate the variations of piriformis muscle, sciatic nerve and its branches and discuss their clinical importance.

Materials and Methods: Fifty-two gluteal and lower limb regions of 26 formalin fixed male cadavers were evaluated in Ege University Faculty of Medicine, Department of Anatomy. The anatomical relationship between the sciatic nerve and the piriformis muscle, and division level of sciatic nerve in thigh was recorded.

Results: The sciatic nerve exited the pelvis as a single branch through the infrapiriform foramen with no variation in 84.62% of the lower limbs. The division variations of sciatic nerve were determined in 23.08%. In 8 of 12 high divisions were observed in gluteal regions (15.38%). The common peroneal nerve and the tibial nerve entered deep gluteal region via the greater sciatic foramen below piriformis muscle separately in four lower limbs (7.69%). Two separate nerve divisions passed above and through (or below) the piriformis muscle and then combined together to form common peroneal nerve while tibial nerve passing below the piriformis muscle in 4 lower limbs (7.69%). In 2 of 12, high division occurred in the 1/3 upper portion of the thigh unilaterally (3.85%). The division of sciatic nerve in the popliteal fossa was seen in two lower limbs (3.85%).

Conclusion: The clinical importance of the sciatic nerve around the piriformis muscle or in the thigh was discussed for piriformis syndrome, palsy after total hip arthroplasty, intramuscular injections in gluteal region and failed popliteal nerve block.

Keywords: Sciatic nerve, piriformis syndrome, palsy, hip replacement, anatomical variations.

Öz

Amaç: Çalışmanın amacı *musculus piriformis*, siyatik sinir ve dallarının varyasyonlarını göstermek ve klinik önemini tartışmaktır.

Gereç ve Yöntem: Ege Üniversitesi Tıp Fakültesi, Anatomi Anabilim Dalı'nda formalin ile fikse edilmiş 26 erkek kadavraya ait 52 adet gluteal bölge ve alt ekstremitede değerlendirildi. Siyatik sinir ve *musculus piriformis* arasındaki anatomik ilişki ile uylukta siyatik sinirin dallanma seviyesi kaydedildi.

Bulgular: Alt ekstremitelerin %84.62'sinde siyatik sinir pelvisten tek dal halinde, varyasyonsuz olarak çıktı. Siyatik sinirin dallanma varyasyonu %23.08 olarak tespit edildi. On iki adet olarak bulunan yüksekte ayrılmanın 8'i gluteal bölgede idi (%15.38). Dört alt ekstremitede (%7.69) *nervus peroneus communis* ve *nervus tibialis* derin gluteal bölgeye foramen *ischadicum majus* yolu ile *musculus piriformis*'in altından ayrı ayrı girdi. Dört alt ekstremitede ise (%7.69) iki ayrı dal *musculus piriformis*'in üzerinden, içinden (ya da altından) geçti ve *nervus tibialis* *musculus piriformis*'in altından geçerken bu iki dal da *nervus peroneus communis*'i oluşturmak üzere daha sonra birleşti. On iki örneğin ikisinde, yüksekte ayrılma unilateral olarak uyluğun 1/3 üst bölümünde izlendi. Siyatik sinirin fossa poplitea'da dallarına ayrılması da iki alt ekstremitede görüldü (%3.85).

Sonuç: Siyatik sinirin *musculus piriformis* çevresindeki veya uyluktaki varyasyonları; piriformis sendromu, total kalça protezi sonrası ortaya çıkan paralizi, gluteal bölgeye uygulanan intramusküler enjeksiyonlar ve başarısız popliteal sinir bloğu yönü ile tartışıldı.

Anahtar Sözcükler: Siyatik sinir, piriformis sendromu, paralizi, kalça replasmanı, anatomik varyasyonlar.

Introduction

The sciatic nerve is the thickest and the longest nerve in the human body. Classically the gluteal nerves, gluteal vessels, sciatic nerve and the posterior cutaneous nerve pass below the piriformis muscle and descend along the posterior aspect of the thigh to supply posterior aspect of the lower limb. It then separates into tibial and common peroneal nerves outside the pelvis, at the upper angle of the popliteal fossa. During this route, the anatomy of the sciatic nerve and its branches have several anatomical variations. The variations of piriformis muscle, sciatic nerve and its branches have clinical importance during surgical interventions and some other clinical approaches (1-6).

The term of 'piriformis syndrome' characterized by entrapment of the sciatic nerve was first used by Robinson in 1947 (7). It is caused by an entrapment of sciatic nerve as it exits the greater sciatic notch (6, 8). Piriformis syndrome is an often overlooked reason of buttock and leg pain. The cause of sciatica is piriformis syndrome approximately 6-8% of patients (1,5). It is still a poorly understood clinical syndrome relating to the proper diagnosis and most effective form of treatment (1,2,3,9,10). Sciatic nerve variants were considered as a possible unrecognized etiology in the piriformis syndrome by some authors (7,8,11-13).

The other clinical importance of these variants is postoperative palsy of sciatic nerve after hip joint surgery that is a poor result of the procedure. Stretching of the sciatic nerve or its branches has more risk during surgery in some variations between sciatic nerve and piriformis muscle (4). The variations of the sciatic nerve and the piriformis muscle have also significance for the posterior paratrochanteric portal (posterior portal) during arthroscopic surgery (14).

The division of the sciatic nerve may occur anywhere from the sacral plexus to the popliteal fossa. Some anatomical variations concerning its topography and division such as the division of the sciatic nerve in the popliteal fossa may be also responsible for failure of sciatic nerve popliteal blocks (10, 15, 16, 17).

The aim of this study was to present the anatomic variations of sciatic nerve divisions in that may have clinical importance for piriformis syndrome, hip arthroscopy and other clinical approaches to make surgeons be aware of these variations. Present study was undertaken to know the level of division, exit course and relationship to piriformis.

Materials and Methods

Twenty six formalin fixed adult male cadavers with no evidence of lower limb surgery or pathology were used for this study. Fifty two gluteal and lower limb regions of 26 cadavers fixed with formalin were evaluated by

means of classical anatomical dissection for tutorial purposes in Anatomy Department of Ege University Faculty of Medicine. The study conforms to the provisions of the Helsinki Declaration of 1964 and all subsequent revisions. The gluteus maximus was carefully elevated to expose the piriformis, the sciatic nerve including its division into the tibial and common peroneal nerves. The anatomical relationship between the sciatic nerve and the piriformis muscle, and division level of sciatic nerve in thigh was observed and recorded.

Results

In 44 of 52 lower limbs, the sciatic nerve exited the pelvis as a single branch through the infrapiriform foramen with no variation (84.62%).

In 12 of 52 gluteal regions or lower limbs, division variations of sciatic nerve was determined (23.08%). In 8 of 12 high divisions were observed in gluteal regions (15.38%). In one left side lower limb and three right side lower limbs, the common peroneal nerve and the tibial nerve entered deep gluteal region via the greater sciatic foramen below piriformis muscle separately (7.69%) (Figure-1).

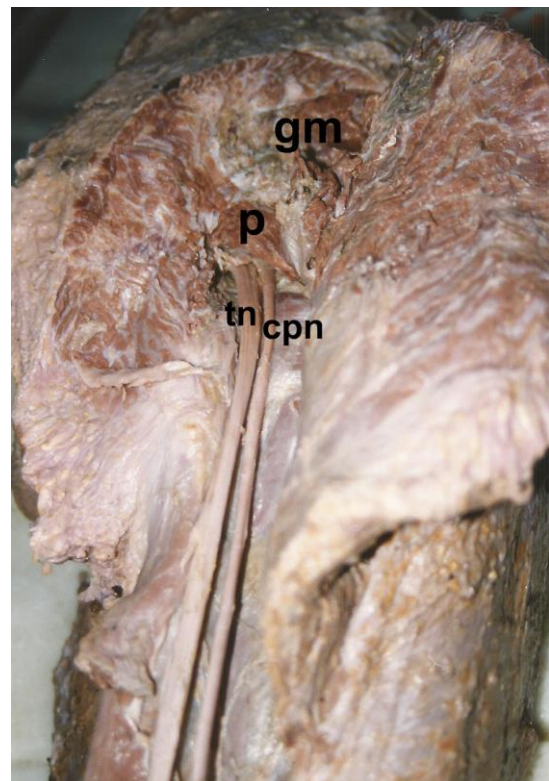


Figure-1. The common peroneal nerve and the tibial nerve entered deep gluteal region via the greater sciatic foramen below piriformis muscle separately (on the right side).
gm: Gluteus medius, p: Piriformis, cpn: Common peroneal nerve, tn: Tibial nerve.

Two separate nerve divisions passed above and through (or below) the piriformis muscle and then combined together to form common peroneal nerve while tibial nerve passing below the piriformis muscle in 4 lower limbs (7.69%). On the right side of a male cadaver, two separate nerve divisions passed above and below the piriformis muscle and then combined together to form common peroneal nerve while tibial nerve passing below the piriformis muscle (Figure-2).

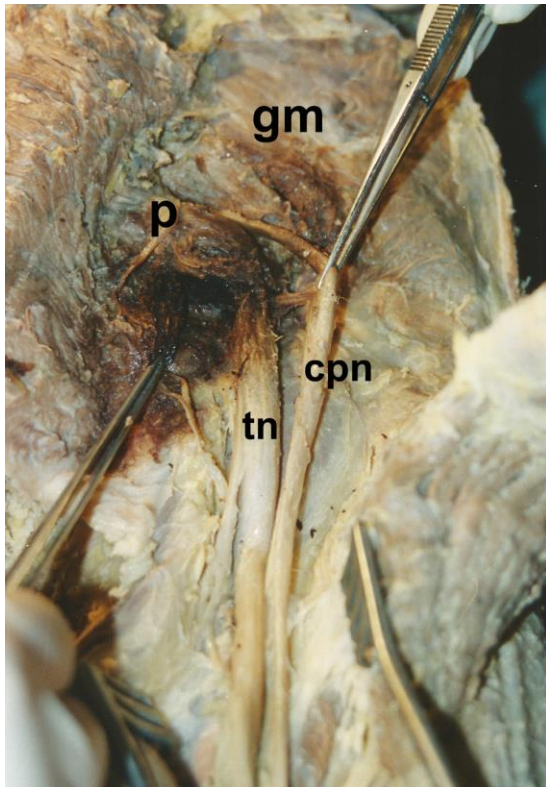


Figure-2. Two separate nerve divisions passed above and below the piriformis muscle and then combined together to form common peroneal nerve while tibial nerve passing below the piriformis muscle (on the right side).
gm: Gluteus medius, p: Piriformis, cpn: Common peroneal nerve, tn: Tibial nerve.

On the left side of this cadaver, common peroneal nerve passed through the piriformis muscle fibers and tibial nerve entered the lower limb below the piriformis muscle with an accessory piriformis muscle. The accessory piriformis had an independent tendon (Figure-3).

This variation seen on the left side was also observed as a unilateral variation on the left side of another cadaver without an accessory piriformis muscle (Figure-4).

In 2 of 12, high division occurred in the 1/3 upper portion of the thigh unilaterally (3.85%) (Figure-5). The division of sciatic nerve in the popliteal fossa was seen in two lower limbs (3.85%) (Figure-6).

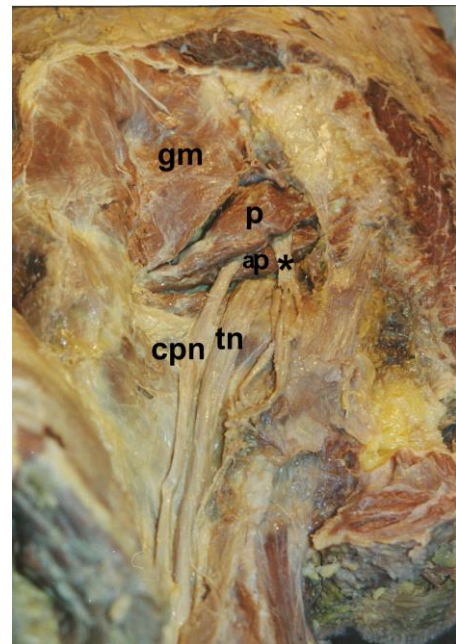


Figure-3. Common peroneal nerve passed through the piriformis muscle fibers and tibial nerve entered the lower limb below the piriformis muscle with an accessory piriformis muscle. The accessory piriformis had an independent tendon (on the left side).
gm: Gluteus medius, p: Piriformis, ap: Accessory piriformis, cpn: Common peroneal nerve, tn: Tibial nerve, *: inferior gluteal nerve.

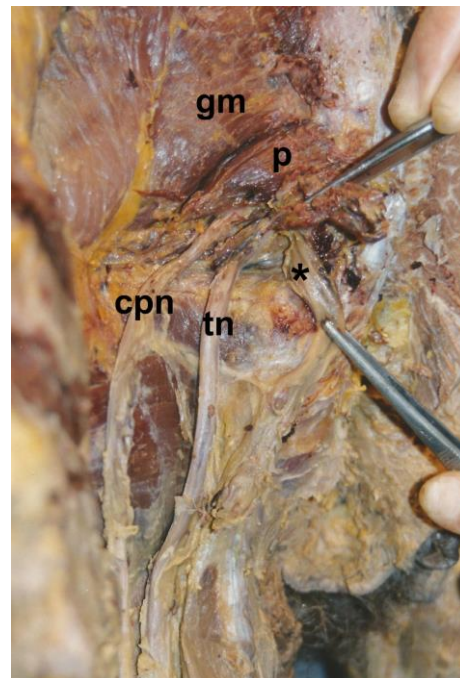


Figure-4. Common peroneal nerve passed through the piriformis muscle fibers and tibial nerve entered the lower limb below the piriformis muscle without an accessory piriformis muscle (on the left side).
gm: gluteus medius, p: piriformis, cpn: common peroneal nerve, tn: tibial nerve, *: inferior gluteal nerve.

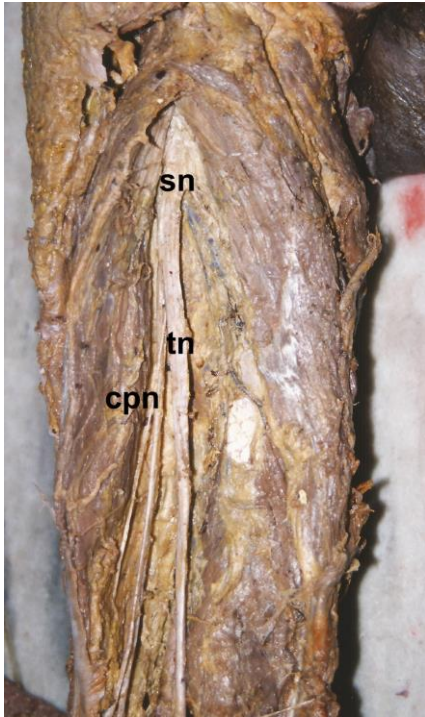


Figure-5. High division occurred in the 1/3 upper portion of the thigh (on the left side).
sn: Sciatic nerve, cpn: Common peroneal nerve, tn: Tibial nerve.

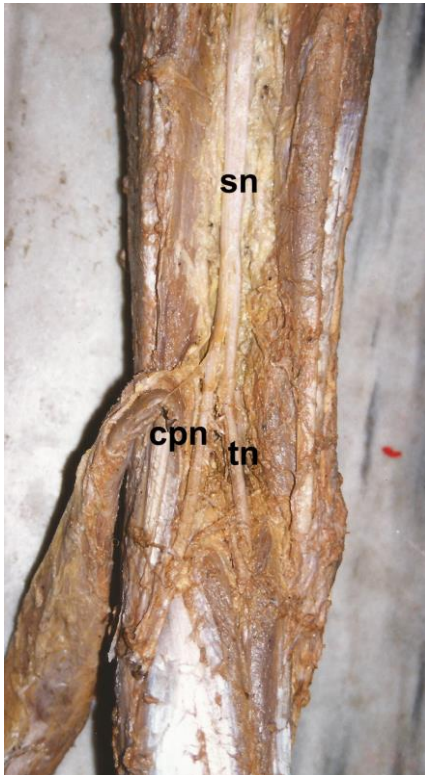


Figure-6. The division of sciatic nerve in the popliteal fossa (on the left side).
sn: Sciatic nerve, cpn: Common peroneal nerve, tn: tibial nerve.

Discussion

Beaton and Anson (18,19) described six anatomical relationships between the sciatic nerve and piriformis muscle using a six category classification system in 1938: (A) the sciatic nerve passing below the piriformis muscle, (B) a divided sciatic nerve passing through and below the piriformis muscle, (C) a divided nerve sciatic nerve passing above and below muscle, (D) an undivided sciatic nerve passing through the piriformis muscle, (E) a divided nerve passing through and above the muscle, (F) an undivided sciatic nerve passing above the piriformis muscle (2,3) (Figure-7). Smoll (5) presented the reported incidence of these six variations in over 6000 lower limbs from multiple cadaveric studies from the late 1800s until 2009. The type A, B, C, D, E and F found in 83.1, 13.7, 1.3, 0.5, 0.08 and 0.08%, respectively (2). Smoll (5) reported an interesting finding in his review that types D, E and F did not find in four largest cadaver series. Cassidy et al. (2) reported a new variation in 2012 as a subtype of B. We also observed this variation in one pelvis. In this variation the sciatic nerve passed below piriformis muscle but a smaller accessory piriformis muscle with its own separate tendon was present and this accessory piriformis muscle was between the common peroneal and tibial nerves.

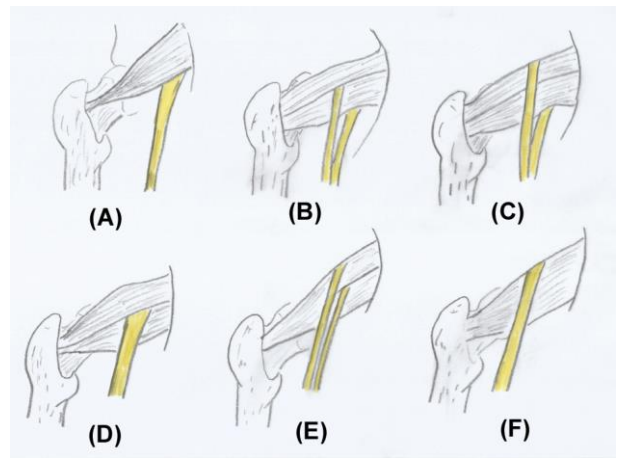


Figure-7. Classification of Beaton and Anson (posterior view).

Delabie et al. (13) studied with 104 buttocks from 52 randomly selected patients on MRI. They also described the accessory piriformis muscle as bifid and the peroneal nerve passed between two heads in 9.6% of cases.

Smoll (5) reported a systematic review about variations of the piriformis and sciatic nerve with clinical consequence. Thirty anatomical textbooks and six databases were searched to find dissection reports. According to this review, the percentage of anomalies was between 35.8% and 9.5% in gluteal region (5). In our study, division variations of sciatic nerve were determined in 15% of gluteal regions and lower limbs but

the division variation in only gluteal region was seen in 10%.

Pokorny et al. (4) determined one of the described variants bilaterally in only one cadaver of 91 cadavers. This variation was type IV. Type IV had the same anatomic features with type B of Beaton and Anson (4,5,18,19). Pais et al. (20) reported three cadavers with anatomical variants of sciatic nerve. Two of them had high division in the inferior portion of gluteal regions on both sides. We also observed a cadaver that had variations bilaterally but the type of variation on the contralateral side was not the same on this cadaver.

In attempts to explain possible causes of piriformis syndrome, studies have been conducted on cadavers to explore the anatomical variations of piriformis muscle and the sciatic nerve. The study of Beaton and Anson in 1938 involving 240 cadavers demonstrated that in 90% of specimens sciatic nerve exited below the piriformis muscle. The remaining 10% of specimens had six different types of anatomical variations (2). Although there is a widely held opinion about the relationship between piriformis syndrome and these anatomical variations, it is not clear yet. The studies of Broadhurst et al. (21) and Kirschner et al. (22) did not support this opinion. Broadhurst et al. (21) described a series of 27 patients undergoing ultrasound imaging of the buttock to see whether or not changes in the piriformis muscle in patients suffering from piriformis syndrome. They determined three variations but all of them were on the unaffected side. Kirschner et al. (22) also reported that some asymptomatic patients presented with these variations and some symptomatic patients did not.

One of the descriptions of the safe region for giving injections into the buttock is superior to a line extending from posterior superior iliac spine to the superior border of the greater trochanter (23). On the right side of a cadaver in present study, two separate nerve divisions passed above and below the piriformis muscle to form the common peroneal nerve (2.5%). The division passing superior to the muscle may be especially vulnerable to injury during intragluteal injections since the nerve was not in the safe region for injections.

The variations of sciatic nerve in gluteal region contribute to nerve palsy during the posterior approach total hip arthroplasty since this surgical approach involves detaching the piriformis tendon and the other short external rotators of the hip from the trochanter and upper thigh. Retraction of piriformis muscle may be responsible of stretching and damage to the nerve (3,24,25). Smoll (2010) mentioned that if type B, D or E variations were present, all or a part of sciatic nerve pierced the piriformis muscle and retraction can cause sciatic nerve compression as the muscle retracts medially, pulling on the nerve (5). The variation observed

in present study, passing through piriformis muscle fibers as two separate nerve divisions of common peroneal nerve, was not recorded in the literature previously. The common peroneal nerve in this variation determined in the present study may be also compressed or strangulated by the piriformis muscle fibers surrounding the nerve.

Pais et al. (20) reported in a cadaver the division of the sciatic nerve in its terminal branches inside the pelvis, tibial and common peroneal nerves, just before crossing the greater sciatic notch. The common peroneal nerve exited the pelvis above the piriformis muscle while the tibial nerve coursed deep to piriformis muscle. This variation was type C of Beaton and Anson (18,19). This variation was observed in present study in one cadaver unilaterally, but with a difference. The common peroneal nerve took a division splitting the piriformis muscle, while taking a division from above the piriformis muscle. This kind of high division can result in involvement of only one of the terminal branches in sciatica and may be a reason of atypical sciatic compressive syndrome.

Prakash et al. (9) performed a cadaveric study on 86 lower limbs. The sciatic nerve division in the lower part of the posterior compartment of the thigh was in 40.7%, while the division was in the popliteal fossa in 34.9% and proximal to its entrance in the gluteal region in 16.3%. In the series of present study, the division in the upper part of the posterior compartment of the thigh was differently observed in one lower limb.

The sciatic nerve block in the popliteal fossa is frequently administered for anesthesia and post-operative pain blockage for lower extremity surgery below the knee. The sciatic nerve division in the popliteal fossa and its depth have significant implications for popliteal block (7,15-17). Vloka et al. (15) suggested that insertion of the needle at 100 mm above the popliteal crease was most suitable placement, as a different opinion according to the classical teaching. Consequently, the nerve may divide into its terminal divisions at variable levels extending from sacral plexus till the popliteal fossa. Recognizing these anatomical variations can help clinicians in performing nerve blocks.

Conclusion

The anatomical variants related to the division of the sciatic nerve and piriformis muscle should be always kept in mind during surgical approaches and other clinical procedures. Knowledge such variations and differences has clinical significance to plan them and to get better treatment outcomes.

Conflict of interest and financial disclosure: Authors of this study have no conflict of interest and financial disclosure to declare.

References

1. Natsis K, Totlis T, Konstantinidis GA, Paraskevas G, Piagkou M, Koebke J. Anatomical variations between the sciatic nerve and the piriformis muscle a contribution to surgical anatomy in piriformis syndrome. *Surg Radiol Anat* 2014;36(3):273-80.
2. Cassidy L, Walters A, Bubb K, Shoja MM, Tubbs RS, Loukas M. Piriformis syndrome: Implications of anatomical variations, diagnostic techniques, and treatment options. *Surg Radiol Anat* 2012;34(6):479-86.
3. Kanawati AJ. Variations of the sciatic nerve anatomy and blood supply in the gluteal region: A review of the literature. *ANZ J Surg* 2014;84(11):816-9.
4. Pokorny D, Jahoda D, Veigl D, Pinskerová V, Sosna A. Topographic variations of the relationship of the sciatic nerve and the piriformis muscle and its relevance to palsy after total hip arthroplasty. *Surg Radiol Anat* 2006;28(1):88-91.
5. Smoll NR. Variations of the piriformis and sciatic nerve with clinical consequence: A review. *Clin Anat* 2010;23(1):8-17.
6. Adibatti M, V S. Study on variant anatomy of sciatic nerve. *J Clin Diagn Res* 2014;8(8):AC07-9.
7. Grgić V. Piriformis muscle syndrome: Etiology, pathogenesis, clinical manifestations, diagnosis, differential diagnosis and therapy. *Lijec Vjesn* 2013;135(1-2):33-40.
8. Güvençer M, Iyem C, Akyer P, Tetik S, Naderi S. Variations in the high division of the sciatic nerve and relationship between the sciatic nerve and the piriformis. *Turk Neurosurg* 2009;19(2):139-44.
9. Prakash, Bhardwaj AK, Devi MN, Sridevi NS, Rao PK, Singh G. Sciatic nerve division: A cadaver study in the Indian population and review of the literature. *Singapore Med J* 2010;51(9):721-3.
10. Coelho P, Melo C, Bernardes A. Rare anatomical variation of absence of the sciatic nerve: Completely substituted by the tibial and common fibular nerve. *Acta Med Port* 2013;26(3):283-6.
11. Battaglia PJ, Scali F, Enix DE. Co-presentation of unilateral femoral and bilateral sciatic nerve variants in one cadaver: A case report with clinical implications. *Chiropr Man Therap* 2012;20(1):34.
12. Hopayian K, Song F, Riera R, Sambandan S. The clinical features of the piriformis syndrome: A systematic review. *Eur Spine J* 2010;19(12):2095-109.
13. Delabie A, Peltier J, Havet E, Page C, Foulon P, Le Gars D. Relationships between piriformis muscle and sciatic nerve: radioanatomical study with 104 buttocks. *Morphologie* 2013;97(316):12-8.
14. Gomes BA, Ramos MR, Fiorelli RK, Almeida CR, Fiorelli SK. Topographic anatomical study of the sciatic nerve relationship to the posterior portal in hip arthroscopy. *Rev Col Bras Cir* 2014;41(6):440-4.
15. Vloka JD, Hadzić A, April E, Thys DM. The division of the sciatic nerve in the popliteal fossa: Anatomical implications for popliteal nerve blockade. *Anesth Analg* 2001;92(1):215-7.
16. Saleh HA, El-fark MM, Abdel-Hamid GA. Anatomical variation of sciatic nerve division in the popliteal fossa and its implication in popliteal nerve blockade. *Folia Morphol (Warsz)* 2009;68(4):256-9.
17. Chiang EP, Dangerfield P, Asay D, Cucchiaro A, Berger JS. Ultrasound imaging of the sciatic nerve division in the popliteal fossa: a volunteer study. *Open J Anesthesiol* 2013;3(5):288-292.
18. Beaton LE, Anson BJ. The relation of the sciatic nerve and of its subdivisions to the piriformis muscle. *Anat Rec* 1937;70(1):1-5.
19. Beaton LE, Anson BJ. The sciatic nerve and the piriformis muscle: Their interrelation a possible cause of coccygodynia. *J Bone Joint Surg* 1938;20(3):686-8.
20. Pais D, Casal D, Bettencourt Pires MA, Furtado A, et al. Sciatic nerve high division: two different anatomical variants. *Acta Med Port* 2013;26(3):208-11.
21. Broadhurst NA, Simmons DN, Bond MJ. Piriformis syndrome: Correlation of muscle morphology with symptoms and signs. *Arch Phys Med Rehabil* 2004;85(12):2036-39.
22. Kirschner JS, Foye PM, Cole JL. Piriformis syndrome, diagnosis and treatment. *Muscle Nerve* 2009;40(1):10-18.
23. Moore KL, Dalley AF. Clinically Oriented Anatomy. Fourth Edition. London: Lippincott, Williams & Wilkins; 1999:560.
24. Khan RJ, Fick D, Khoo P, Yao F, Nivbrant B, Wood D. Less invasive total hip arthroplasty: Description of a new technique. *J Arthroplasty* 2006;21(7):1038-46.
25. Sosna A, Pokorny D, Jahoda D. Sciatic nerve palsy after total hip replacement. *J Bone Joint Surg* 2005;87(8):1140-1.