






Presentation of ultrasound and magnetic resonance imaging findings of omphalopagus conjoined twins in the intrauterine and postpartum period

Omfalopagus yapışık ikizlerin intrauterin ve postpartum dönem ultrasonografi ve manyetik rezonans görüntüleme bulgularının sunumu

Turgay Kara¹  Halil İbrahim Şara²  Fatih Ateş³ 
Sibel Özler⁴  Mehmet Sedat Durmaz³ 

¹ Kahramanmaraş Sutcu Imam University Faculty of Medicine, Department of Radiology, Kahramanmaraş, Turkey

² Health Sciences University, Ankara Dr. Abdurrahman Yurtaslan Oncology Health Application and Research Center, Ankara, Turkey

³ Selcuk University Faculty of Medicine, Department of Radiology, Konya, Turkey

⁴ Selcuk University Faculty of Medicine, Department of Perinatology, Konya, Turkey

Abstract

Conjoined twins are extremely rare congenital malformations. Any associated genetic, environmental or demographic factors have not been identified. The phenomenon occurs between the 13th and 15th day after fertilization due to failure in splitting of embryonic axis. Twins are classified according to the major site of union, with the suffix pagus meaning fixed or fastened. Omphalopagus twins are the second most common variety of conjoined twins and usually are joined at the umbilicus.

A 31-year-old pregnant female admitted for routine gestational control. Obstetric ultrasound (US) revealed two fetuses which were adherent from abdominal region. Their livers were fused however other organs were separated. Hepatic veins and portal veins were separated in both fetuses on color Doppler evaluation. Fetal magnetic resonance imaging (MRI) confirmed the diagnosis as omphalopagus conjoined twins. Twins were successfully delivered by cesarean section at 34th gestational week.

Herein, US and MRI features of this rare anomaly in intrauterine and postpartum period are presented.

Keywords: Twins, conjoined; ultrasonography, prenatal; MRI.

Öz

Yapışık ikizlik oldukça nadir görülen konjenital malformasyonlardandır. Oluşmasında herhangi bir genetik, çevresel veya demografik faktör tanımlanmamıştır. Bu fenomen fertilizasyondan sonraki 13. ve 15. günler arasındaki embriyonel bölünmedeki yetersizlik sonucu meydana gelir. İkizler, ana kaynaşma bölgesine sabit veya bağlanmış anlamına gelen pagus son ekinin eklenmesiyle adlandırılır ve sınıflandırılırlar. Omfalopagus ikizleri, yapışık ikizlerin en yaygın ikinci çeşididir ve genellikle karın bölgesinden birleşiktirler. Olgumuzda 31 yaşındaki hamile bir kadın 22. gebelik haftasında rutin gebelik kontrolü için başvurdu. Obstetrik ultrason (US) görüntülemeye karın bölgesinden yapışık iki fetüs tespit edildi. Karaciğerleri birleşmiş ancak diğer organları ayrı görünümdeydi. Renkli Doppler incelemede her iki fetüsün hepatik venleri ve portal venleri ayrı olarak izlendi. İkizler 34. gebelik haftasında sezaryen ile başarıyla doğurtuldu. Bu olgu sunumunda, bu nadir anomalinin intrauterin ve postpartum dönemdeki US ve MRG özellikleri sunulmuş ve literatüre katkı sağlamak amaçlanmıştır.

Anahtar Sözcükler: Omfalopagus, yapışık ikiz, ultrasonografi, MRG, intrauterin.

Corresponding author: Turgay Kara
Kahramanmaraş Sutcu Imam University Faculty of Medicine,
Department of Radiology, Kahramanmaraş, Turkey
E-mail: trgykr@gmail.com
Application date: 16.08.2020 Accepted: 08.10.2020

Introduction

Conjoined twins are extremely rare congenital malformations. The prevalence ranges from 1 in 50 000 to 1 in 100 000 births worldwide. It has been reported that conjoined twins are seen three times more in female sex than male sex. The process by which monozygotic twins do not fully separate is not clear however the phenomenon occurs between the 13th and 15th day after fertilization because of the failure in embryonic splitting. Twins are classified according to the major site of union, with the suffix pagus meaning fixed or fastened. Most frequent type of conjoint twins is thoracopagus. Omphalopagus twins are the second most common variety of conjoined twins and usually are joined at the umbilicus. The stillbirth rate is very high and seems not to vary significantly with type. Accompanying malformations are directly associated with the area of fusion. Besides, an increased rate of malformations is seen far from the area of fusion (1).

Case

A 31-year-old female patient admitted to our hospital for routine follow up of her third pregnancy. During the fetal anomaly scan with ultrasonography (US), it was seen that there was a twin pregnancy and fetuses were consistent with 22 weeks gestational age. Fetuses were adherent to each other in the abdominal region. Their kidneys and spleens were normal. The livers were fused in appearance. On color Doppler evaluation, hepatic veins and portal veins were separate in both fetuses. The portal hiluses of the livers were selected separately (Figure-1a). The fetuses' hearts and stomach were separate but their livers were fused. Because of the presence of these findings, fetuses were identified as omphalopagus. Subsequent fetal MRI revealed that the fetuses were adherent to the abdominal region (Figure-1b). Both fetuses had two umbilical arteries and one umbilical vein. No additional anomaly was detected in fetuses except fusion. After the diagnosis of omphalopagus confirmed by MRI, the twins were successfully delivered by cesarean operation at 34th gestational week. The combined birth weight of babies was 2 kg. The babies were fused from epigastrium to umbilicus (Figure-1d). Babies were reevaluated with MRI afterbirth (Figure-1c). Imaging findings overlapped with findings in the intrapartum period. Twins were followed up at pediatric intensive care service. Since omphalopagus twins have best chances of survival if

successfully separated, one month after birth, a separative operation was planned thus patients were transferred to another hospital available for separative operation.

Discussion

Conjoint twinning is a rare anomaly that is more common in female gender. There is no known risk increase with parity, race, maternal age or inheritance (2). The conjoined twin is monozygotic, monoamniotic, monochorionic. There are varieties named according to the type and site of union. These are thoracopagus, omphalopagus, pyopagus, ischiopagus, craniopagus, cephalopagus, rachipagus and parapagus (1, 3).

Omphalopagus twins constitute 18-33% of conjoined twins (3). They usually converge from the front side of the umbilicus level, including the lower thorax. As seen in our case, liver fusion occurs in 80% of cases. The pericardium may be common, but the hearts are always separated as in our case (3, 4). Stomachs and proximal small intestines are usually separated; at 33% of cases, the small intestines are adherent at the level of the Meckel diverticulum on the distal ileum (3, 5). However, we did not determine such a union in our twins which had separated gastrointestinal tracts. Shared terminal ileum and proximal colon often have double blood circulation and vascular studies can help deciding on the distribution of intestines in separating twins. The colon is separated distally and each of the twins has a rectum. There are four arms and four legs without pelvic or urethral fusion (5).

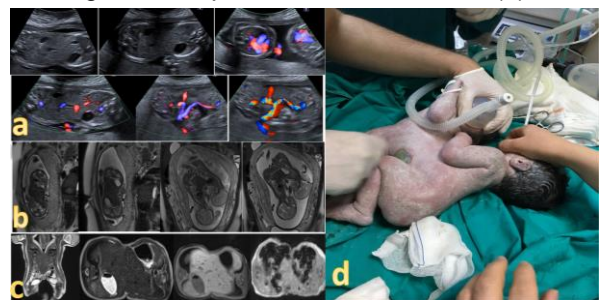

Figure-1. a) US and color Doppler images of omphalopagus conjoined fetuses. The livers were fused. Hepatic veins and portal veins were separated. b) Intrauterine T2 weighted MRI images of omphalopagus conjoined fetuses. c) Postpartum T2 and T1 weighted MRI images of omphalopagus conjoined twins. Twins were attached from abdomen and livers were fused. d) Conjoint omphalopagus twins were attached at their epigastrium, post-cesarian image.

Antenatal diagnosis of typical conjoined twins can be done by US even in the first trimester. However, we could identify the pathology in the second trimester because it was the first time the pregnant mother admitted to the hospital for this pregnancy. The US allows direct, real-time review of conjoined twins. It can detect details such as the correct diagnosis of accompanying congenital anomalies and the degree of fusion. The prenatal diagnosis of common organs is of great importance in terms of possible surgical approach or termination of the pregnancy. However, maternal obesity, oligohydramnios, and fetal head involvement may reduce the imaging quality of US during late gestation (4, 6).

The first case in literature diagnosed by US have been reported in the 28th week of gestation in 1977 (7). From that day on, some criteria and diagnostic handicaps were determined for US (2). Ultrasonographic diagnosis is possible in the first trimester. For example, the earliest diagnosis was reported about 7 weeks of gestation (8). However, close follow-up is needed to confirm ultrasonographic diagnosis (9).

It is thought that some tips are useful to diagnose conjoined twins with ultrasound. Some of these tips are; fetal pole in the form of a "V" or "Y" bifid in the first trimester, fetal anomalies such as omphalocele and complex cardiac malformations, presence of more than 3 vessels in the umbilical cord, parallel extension of spinal vertebrae one to the other, bi-cephalic or bi-caudal presentation, different fetal position in same examination. When these findings are encountered, it should be remembered that there may be conjoined twins (2).

Especially in conjoined twins, MRI is better than US in terms of fetal evaluation. MRI is an excellent technique with its ability to distinguish soft tissues. For this reason, we reevaluated our case with MRI. On MRI, we found that two fetuses had two umbilical arteries and one umbilical vein in each fetus, livers were fusion. In the postpartum period MRI evaluation yielded

findings that overlap with our intrapartum findings (Figure-1c).

Since the diagnose is done primarily by imaging methods; fetal US, color Doppler and MRI evaluation is essential for the decision of elective termination of pregnancy or type of separative surgery after birth. Although success in surgical separation of conjoined twins has improved, surgical separation is still a major challenge. The procedure requires a multi-disciplinary team, accurate imaging to assess organ sharing and a consideration of aspects related to survival and ethics in each case (10).

Conclusion

Conjoined twins are rare and complex. Ultrasonography is the basis of fetal imaging, but it has been shown that the combination of ultrasonography and fetal MRI is superior to ultrasonography alone in conjoint twin pregnancies. MRI can provide additional information that may help ultrasonography for antenatal characterization of such anomalies. MRI gives more anatomical information compared to US in preoperative assessment and especially in conditions that make sonographic evaluation difficult, such as maternal obesity and oligohydramnios. In conclusion, this article aimed to contribute to the literature by presenting findings of intrauterine and postpartum US and MRI in this rare condition.

Conflicts of interest

The authors certify that they have no affiliations with or involvement in any organization or entity with any financial interest (such as honoraria; educational grants; participation in speakers' bureaus; membership, employment, consultancies, stock ownership, or other equity interest; and expert testimony or patent-licensing arrangements), or non-financial interest (such as personal or professional relationships, affiliations, knowledge or beliefs) in the subject matter or materials discussed in this manuscript.

References

1. Hortu İ, Ergenoğlu AM, Yenieli AO, Özçeltik G. Neural Tube Defect with Parasitic Rachipagus Twin (Heteropagus): Case Report *Türkiye Klinikleri J Gynecol Obst* 2016; 26 (3): 189-92.
2. Sabih D, Ahmad E, Sabih A, Sabih Q. Ultrasound diagnosis of cephalopagus conjoined twin pregnancy at 29 weeks. *Biomedical Imaging and Intervention Journal* 2010; 6 (4): e38.
3. McHugh K, Kiely EM, Spitz L. Imaging of conjoined twins. *Pediatric Radiology* 2006; 36: 899–910.

4. Mete A, Cebesoy FB, Bayram M, Kutlar İ. Ultrafast magnetic resonance imaging of omphalopagus conjoined twins. *Gaziantep Medical Journal* 2011; 17 (2): 103-4.
5. Kingston C, McHugh K, Kumaradevan J, Kiely E, Spitz L. Imaging in the Preoperative Assessment of Conjoined Twins. *RadioGraphics* 2001; 21:1187–208.
6. Abdullah H, Wahab NA, Abu Bakar K. Fetal MRI of thoraco-omphalopagus conjoined twins. *BMJ Case Rep* 2017; Jun 13 doi: 10.1136/bcr-2017-219793.
7. Fagan CJ. Antepartum diagnosis of conjoined twins by ultrasonography. *American Journal of Roentgenology* 1977; 129 (5): 921-2.
8. Taner MZ, Kurdoglu M, Taskiran C, Kurdoglu Z, Himmetoglu O, Balci S. Early prenatal diagnosis of conjoined twins at 7 weeks and 6 days' gestation with two-dimensional Doppler ultrasound: a case report. *Cases Journal* 2009; 2: 7.
9. Weiss JL, Devine PC. False positive diagnosis of conjoined twins in the first trimester. *Ultrasound in Obstetrics & Gynecology* 2002; 20: 516–21.
10. Mutchinick OM et al. Conjoined twins: a worldwide collaborative epidemiological study of the International Clearinghouse for Birth Defects Surveillance and Research. *Am J Med Genet C Semin Med Genet.* 2011 (15); 157: 274-87.