

Lodine-131 uptake in a patient with cholelithiasis on post-therapeutic scan

Kolelitiaziste postablatif tüm vücut tarama sintigrafisinde I-131 tutulumu

Mertcan Guven¹  Aysin Oral¹  Sadik Tamsel²  Aysegul Akgun¹ 

¹ Department of Nuclear Medicine, Ege University Faculty of Medicine, Izmir, Turkiye

² Department of Radiology, Ege University Faculty of Medicine Izmir, Turkiye

ABSTRACT

A 71-year-old male patient was diagnosed with papillary carcinoma follicular variant after bilateral total thyroidectomy and radioactive iodine treatment was applied. The post-therapeutic whole-body scan demonstrated a focal 131-I uptake in the right lobe of the liver in the right upper quadrant of the abdomen. Single-photon emission computed tomography/computed tomography (SPECT/CT) was performed to determine the precise localization of 131-I uptake. It was understood that the identified focal 131-I activity was due to cholelithiasis. In the same period, free-floating gallstones in the lumen and the gallbladder neck were observed on the abdominal ultrasonography.

Keywords: Differentiated thyroid cancer, Iodine-131 scintigraphy, cholelithiasis, SPECT/CT.

ÖZ

71 yaşında erkek hasta, bilateral total tiroidektomi sonrası papiller karsinom foliküler varyant tanısı aldı ve hastaya radyoaktif iyot tedavisi uygulandı. Postablatif 10. Günde uygulanan I-131 tüm vücut tarama sintigrafisinde batın sağ üst kadranda karaciğer sağ lobunda fokal I-131 tutulumu dikkati çekti. Bunun üzerine tek foton emisyon bilgisayarlı tomografisi/ bilgisayarlı tomografi (SPECT/BT) uygulandı. Tanımlanan fokal I-131 tutulumunun kolelitiazis nedeniyle olduğu anlaşıldı. Aynı dönem abdominal ultrasonografisinde safra kesesi boynunda ve lümen içinde serbest yüzen safra kesesi taşları izlendi.

Anahtar Sözcükler: Diferansiye tiroid karsinoma, Iyot-131 sintigrafi, kolelitiazis, SPECT/BT.

A 71-year-old male patient was diagnosed with differentiated thyroid carcinoma follicular variant after bilateral total thyroidectomy, and the tumor size was 6 cm. The patient was given 3.7 GBq (100mCi) 131-I treatment. Meanwhile, serum thyroid-stimulating hormone (TSH) level was 70 IU/mL, thyroglobulin (Tg) level was 0.15 ng/mL, and anti-Tg was <15 IU/mL during ablation. Then post-therapeutic 131-I whole-body scan was performed. On the whole-body scan, in addition to activity uptake in the thyroid bed consistent with residual thyroid tissue, focal 131-I uptake was observed in the right upper quadrant of the

abdomen in the area compatible with the right lobe of the liver. On the SPECT/CT images performed upon this finding, it was determined that the gallbladder was distended and focal 131-I uptake was in one of two localizations of gallstones. An abdominal ultrasound performed in the same period revealed normal liver size and parenchyma, a 12 mm diameter stone impacted in the gallbladder neck, and a 2.5 cm stone free-floating in the lumen. According to the patient's medical record, gallstones are known and followed for a long time (Figure-1).

Corresponding author: Mertcan Guven
Department of Nuclear Medicine, Ege University Faculty of
Medicine, Izmir, Turkiye
E-mail: drmertguven@gmail.com
Application date: 06.02.2022 Accepted: 01.03.2022

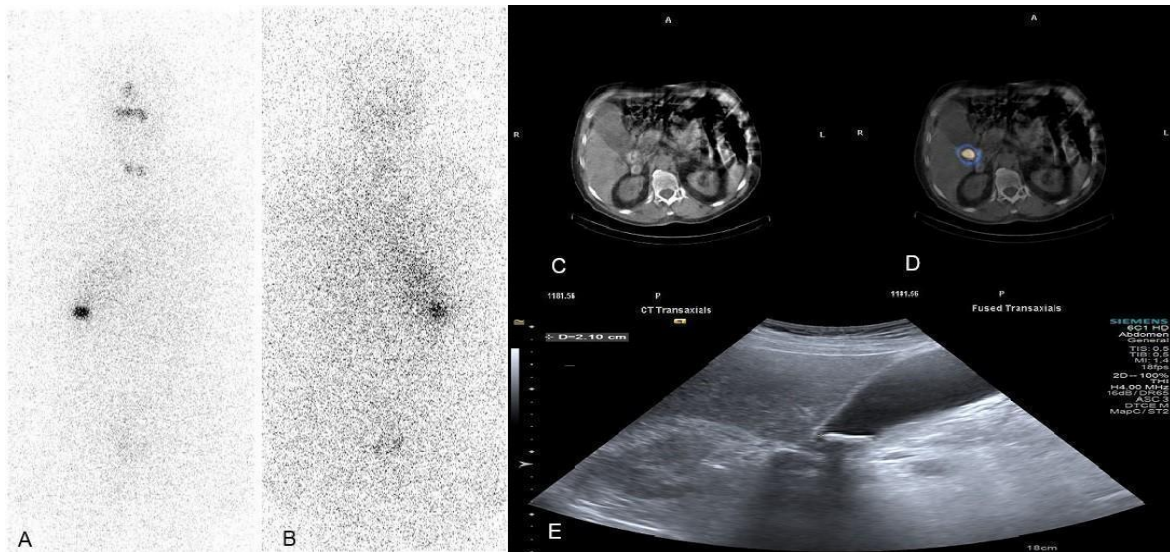


Figure-1. Intense focal uptake was identified at the region of the gallbladder on the post-therapeutic ¹³¹I whole-body scan. Anterior (A) and posterior (B) views are shown. Focal ¹³¹I uptake is observed in the area compatible with cholelithiasis on CT (C) and fused SPECT/CT (D) images. Cholelithiasis is demonstrated in the gallbladder on the abdominal ultrasound image (E).

Differentiated thyroid cancers include papillary and follicular thyroid cancers and are the most common thyroid malignancy. After total thyroidectomy, disease-free survival rates are high with ¹³¹I ablation in selected cases. The sensitivity and specificity of imaging with ¹³¹I are high in differentiated thyroid cancer. However, false-positive ¹³¹I uptakes can be seen due to body secretions, inflammation, and non-thyroid neoplasms (1, 2). Additional imaging methods are needed when ¹³¹I uptake is incompatible with Tg.

Due to the metabolism of radiolabeled Tg in the liver, diffuse radioactivity uptake is almost always seen in the liver. However, focal radioactivity uptake may be due to benign cystic lesions, malignant lesions, delayed hepatic excretion, and NIS expression in the gallbladder mucosa (3). Focal uptake may also be seen due to liver

metastasis, but this is not very common and its frequency is 0.5% (4). In addition, liver metastases usually occur in end-stage disease. When focal uptake is observed, the possibility of metastases can be excluded with SPECT/CT imaging.

Iodine-¹³¹I uptake in cholelithiasis may be due to the induction of iodine organification by myeloperoxidase by leukocytes secondary to inflammation. Unexpected false-positive uptake in ¹³¹I whole-body scintigraphy causes diagnostic difficulties due to the low-resolution imaging properties of ¹³¹I. As in our case, if there is focal ¹³¹I uptake in the liver and there is no elevation of Tg and anti-Tg to suggest metastasis, unnecessary tests and treatments can be avoided with SPECT/CT imaging.

Conflict of interest: The authors declared no conflict of interest

References

1. Aylin O, Bülent Y, Cenk E, Zeynep B. Unexpected False-positive I-131 Uptake in Patients with Differentiated Thyroid Carcinoma. *Mol Imaging Radionucl Ther* 2018; 27 (3): 99-106.
2. Vincenzo T, Vito A, Michele I, et al. False positive diagnosis on ¹³¹I iodine whole-body scintigraphy of differentiated thyroid cancers. *Endocrine* 2016; 53 (3): 626-35.
3. Omur O, Akgun A, Ozcan Z, Sen C, Ozkiliç H. Clinical implications of diffuse hepatic uptake observed in postablative and post-therapeutic ¹³¹I scans. *Clin Nucl Med* 2009; 34 (1): 11-4.
4. C. Brient, S. Mucci, D. Taieb, et al. Differentiated thyroid cancer with liver metastases: lessons learned from managing a series of 14 patients. *Int Surg* 2015; 100 (3): 490-6.