




Percutaneous balloon kyphoplasty experience in mid-thoracic vertebra fractures

Orta seviye torakal vertebra fraktürlerinde perkütan balon kifoplasti deneyimi

Gokhan Gurkan¹  Ismail Kaya²  Murat Atar³  Inan Uzunoglu⁴ 

Ilker Deniz Cingoz²  Baran Taskala⁵  Nurullah Yuceer¹ 

¹ Department of Neurosurgery, Katip Celebi University Atatürk Training and Research Hospital, Izmir, Turkiye

² Department of Neurosurgery, Dumlupinar University Kutahya Evliya Celebi Training and Research Hospital, Kutahya, Turkiye

³ Department of Neurosurgery, Istanbul Sultan 2. Abdulhamid Han Training and Research Hospital, Istanbul, Turkiye

⁴ Department of Neurosurgery, Diskapi Yildirim Beyazit Training and Research Hospital, Ankara, Turkiye

⁵ Department of Neurosurgery, Basaksehir Cam and Sakura City Hospital, Istanbul, Turkiye

ABSTRACT

Aim: Balloon kyphoplasty is a popular minimally invasive technique for vertebral fractures. Although vertebral fractures occur mostly in the thoracolumbar region, compression fractures can be seen in the entire vertebral column. The mid-thoracic levels are difficult areas in terms of complications in minimally invasive procedures. Our study aimed to examine the effect of balloon kyphoplasty on vertebral height, kyphosis angle, and cement leaks as a complication in mid-thoracic vertebral fractures.

Materials and Methods: Radiological images, patient files, and pathology results of patients who underwent kyphoplasty due to a single or multiple mid-thoracic vertebral fractures between 2017 and 2020 were retrospectively analyzed.

Results: A total of 19 patients (9 males and 10 females) and 28 operated vertebrae were included in the study. The mean age of the patients was 58.42±18.79 (23-86) years, and the mean operation time was 40.18±15.01 minutes (17-99). The amount of cement used during the procedures was 3.68±1.13 mL (1.5-7), and postoperative cement leakage was observed in 12 levels (42.9%). Anterior and median vertebral heights and kyphosis angle improved significantly compared to preoperative values (p<0.001). The duration of hospital stay was found to be 4.42±0.69 hours (4-6).

Conclusion: The balloon kyphoplasty method is reliable in restoring the vertebra and reducing the angle of kyphosis, although there is a high risk of cement leakage at mid-thoracic vertebrae levels.

Keywords: Balloon kyphoplasty; Cobb angle; cement leakage.

ÖZ

Amaç: Vertebra kırıklarında uygulanan perkütan balon kifoplasti yöntemi, popüler minimal invaziv bir tekniktir. Vertebra kırıkları çoğunlukla torakolomber bölgede meydana gelirse de tüm vertebral kolonda kompresyon fraktürü görülebilir. Orta torakal seviyeler minimal invaziv işlemlerde komplikasyon açısından riskli bölgelerdendir. Çalışmamızda orta torakal vertebra kırıklarında uygulanan perkütan balon kifoplasti yönteminin vertebra yüksekliğine, kifoz açısına etkisini ve komplikasyonu olan sement kaçaqlarını incelemeyi amaçladık.

Corresponding author: Gokhan Gurkan
Department of Neurosurgery, Katip Celebi University Atatürk
Training and Research Hospital, Izmir, Turkiye
E-mail: gokhangurkan88@gmail.com
Application date: 08.12.2021 Accepted: 31.03.2022

Gereç ve Yöntem: 2017-2020 yılları arasında tek ya da çoklu seviye orta torakal vertebra fraktürü nedeni ile kifoplasti uygulanan hastaların radyolojik görüntüleri, hasta dosyaları ve patoloji sonuçları retrospektif olarak incelendi.

Bulgular: Çalışmaya toplamda 19 hasta (9 erkek ve 10 kadın) ve 28 işlem yapılan vertebra dâhil edildi. Hastaların yaş ortalaması 58.42 ± 18.79 (23-86) yıl olarak hesaplandı. Operasyon süresi $40,18 \pm 15,01$ dk (17-99) idi. İşlem sırasında kullanılan sement miktarı $3,68 \pm 1,13$ mL (1,5-7) idi. Postoperatif sement kaçağı 12 (%42,9) seviyede görüldü. Anterior ve median vertebra yükseklikleri ile kifoz açısı operasyon öncesine göre anlamlı ölçüde iyileşme gösterdi ($p<0.001$). Hastanede kalış süresi $4,42 \pm 0,69$ saat (4-6) olarak hesaplandı.

Sonuç: Balon kifoplasti yöntemi orta torakal vertebra seviyelerinde sement kaçağı riski fazla olmasına rağmen, vertebra yüksekliğinin restorasyonu ve kifoz açısını azaltması yönünden güvenilir bir tedavi yöntemidir.

Anahtar Sözcükler: Balon kifoplasti, Cobb açısı, sement kaçağı.

INTRODUCTION

Percutaneous vertebroplasty and balloon kyphoplasty are the most popular treatment methods for vertebral compression fractures (1). Vertebroplasty, one of these minimally invasive techniques, does not restore vertebral height, while the repetition of vertebral compression and kyphosis is more common in later periods (2, 3). At the same time, the risk of cement extravasation during vertebroplasty procedure is higher than kyphoplasty (4). In balloon kyphoplasty, a balloon is used to raise the vertebral corpus, followed by cement injection. The balloon creates a space within the vertebral body and compresses the alveolar bone, limiting the risk of cement leakage (5). In kyphoplasty, the height of the fractured vertebral body and kyphotic angle are tried to be corrected together with the balloon (2, 3).

Vertebral fractures occur mostly in the thoracolumbar region (6). The fact that thoracic vertebrae have steeper angles and thin pedicles than lumbar vertebrae and their connection to ribs increase the difficulty of the procedure and the risk of complications even in minimally invasive procedures.

This study aims to examine the improvements in vertebral heights and kyphosis angle and determine the complications in patients treated with balloon kyphoplasty in mid-thoracic vertebral fractures.

MATERIALS and METHODS

Patients

The patients admitted to our clinic between 2017 and 2020 due to a single or multiple mid-thoracic (Th 5-6-7-8) vertebral fractures, who had

vertebral edema in magnetic resonance imaging (MRI) ([MRI], low signal on T1W images, and high signal on T2W images) with no neurological deficits were included in the study. Balloon kyphoplasty surgery was performed on these patients by the same surgical team. Radiological images, patient files, and pathology results of the patients were analyzed retrospectively.

Surgical Procedure

The surgical procedure was performed by experienced spinal surgeons. The patients were placed in the prone position, supported by chest and side pillows. The surgical area was disinfected. Fractured vertebra levels were confirmed by fluoroscopy. Marking was made with a trocar so that the upper-outer edge of the thoracic vertebral pedicle was aligned. Local anesthetic was applied over the skin, aiming at the entry-level of the pedicle. Afterward, it was entered unilaterally with a needle after a 0.5 cm skin incision. After reaching the pedicle with the needle, the needle was replaced with the trocar. In order not to damage the nerve roots and vascular structures, the trocar was advanced from the upper outer edge of the pedicle. A biopsy was taken from the bone structure for each level after reaching the vertebral corpus. A balloon of the appropriate size to the vertebral corpus was sent through the trocar. Vertebral height was tried to be restored by fluoroscopy control after administering contrast material through the balloon. Thus, a new cavity was created within the fractured vertebra. Afterward, bone cement was started to be injected into this cavity. Fluoroscopy images were obtained during the injection. First, the deepest part of the fractured vertebra was filled with cement. Then, the trocar was withdrawn a little, and the more

superficial parts were continued to be filled. When cement leakage was observed outside the broken vertebra into the epidural, disc space, or vascular structures, it was waited for a while, and then cement was continued to be applied to the empty areas of the fractured bone.

Clinical Outcome Evaluation

Control computed tomography (CT) (Johanson and Johanson, USA) was taken within 24 hours after the operation. After observing the wound sites, the patients who were mobilized were discharged after the postop follow-up period was completed.

Data Collection

Data on operation time, the amount of bone cement injected into each vertebra, bone cement leakage, and duration of hospital stay were retrospectively collected. Cobb angle was determined in tomography imaging for kyphosis. The vertebral anterior height (distance between upper and lower endplates) and vertebral median height (distance between the middle points of upper and lower endplates) were measured (Figure-1).

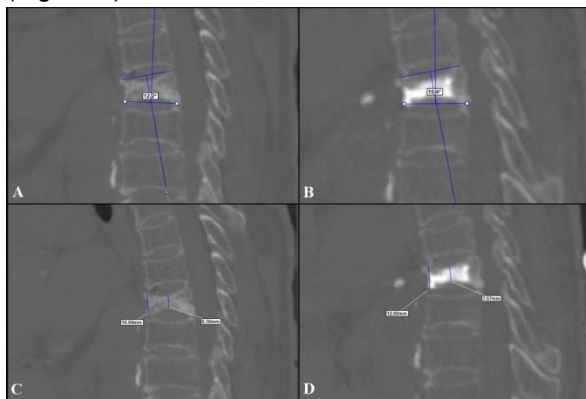


Figure-1. A) Preoperative sagittal CT scan. The Cobb angle for the patient is 12.2°. B) Postoperative sagittal CT scan. The Cobb angle for the same vertebrae 10.4°. C) Anterior and median vertebra height measurement in CT for another patient. Anterior-median height measurement is 10.59, 6.38 mm respectively. D) Same as the patient in C, postoperatively measurement is 12.0, 7.67 mm respectively.

Statistical Analysis

The SPSS v24 (IBM-USA) program was used for the statistical analysis of the data. Continuous variables were expressed as mean \pm standard deviation values, while categorical variables as numbers and percentages. The Paired-Samples T-test was used to compare the means of

preoperative and postoperative data. The p-value of <0.05 was considered statistically significant.

Ethics

Informed consent was obtained from each patient included in the evaluation. The study was approved by the institutional ethics committee (24.12.2020-1097) and performed fully per The Code of Ethics of the World Medical Association (Declaration of Helsinki) for experiments involving humans.

RESULTS

A total of 19 patients who underwent the surgical procedure, as nine males (47.4%) and ten females (52.6%), were included in the study. The mean age of the patients was 58.42 ± 18.79 years (range 23 to 86).

Treatment outcomes

The total number of levels in these patients with single and multiple mid-thoracic vertebral fractures was 28 (Table-1). When the etiologies of the fractured vertebrae were examined, the possibility of metastasis was considered for each vertebral level in 2 oncology patients, while there was a trauma for 26 levels.

The mean operation time was 40.18 ± 15.01 minutes (17-99). The balloon size used was 10 mm for 1 T7 level, 15 mm for 25 mid-thoracic vertebra levels, and 20 mm for two mid-thoracic vertebra levels. The amount of bone cement injected was 3.68 ± 1.13 mL (1.5-7) (Table-2).

Before the operation, the anterior and median heights in the mid-thoracic vertebrae were measured as 13.81 ± 2.69 mm and 13.24 ± 3.09 mm, respectively. The same heights were 15.01 ± 2.64 mm and 15.17 ± 2.67 mm, respectively, in the postoperative measurements. Vertebra heights were found to be significantly increased ($p < 0.001$). Also, kyphosis angle was significantly corrected (from 9.67 ± 4.66 to 7.11 ± 4.41 ; $p < 0.001$) (Table-3).

Table-1. Distribution of the vertebral segments.

Vertebra Level	Number (%)
T5	1 (3.6)
T6	7 (25)
T7	11 (39.3)
T8	9 (32.1)
Total	28 (100)

Table-2. Characteristic of patients and operations.

Characteristic	Value
Age (y)	58.42 ± 18.79
Gender (male)	9 (47.4%)
Operation time (min)	40.18 ± 15.01
Amount of cement injected (mL)	3.68 ± 1.13
Length of hospital stay (hours)	4.42 ± 0.69
Etiology	
○ Malignancy	2 (7.1%)
○ Trauma	26 (92.9%)
Balloon	
○ 10	1 (3.6%)
○ 15	25 (89.3%)
○ 20	2 (7.1%)
Postoperative Leak	
○ None	16 (57.1%)
○ Intradiscal	5 (17.9%)
○ Extracorporal	3 (10.7%)
○ Intravasal	4 (14.3%)

Table-3. Tomographic results of the 19 cases.

	Preoperative	Postoperative	P-value
Vertebral anterior height (mm)	13.81 ± 2.69	15.01 ± 2.64	<0.001
Vertebral median height (mm)	13.24 ± 3.09	15.17 ± 2.67	<0.001
Cobb angle (°)	9.67 ± 4.66	7.11 ± 4.41	<0.001

All patients were mobilized after the postoperative follow-up period was completed, and the mean hospital stay was 4.42±0.69 hours (4-6).

Biopsy results of all patients, including oncology patients who were thought to have a possible vertebral metastasis, resulted in bone fragments.

Complications

In the postoperative radiological evaluations, cement leakage occurred in a total of 12 fractured vertebrae of 9 patients, while no other

side effects were observed. These leaks were intradiscal at five levels, extracorporeal at three levels, and intravasal at four levels. There was no spinal cord injury or vascular injury during the operation. Postoperative cardiac embolism, pulmonary embolism, or fat embolism were not observed, and there were no neurological deficits or pneumothorax.

DISCUSSION

Percutaneous kyphoplasty is an effective minimally invasive surgical procedure performed safely in vertebral collapse fractures (7). Although vertebral collapse fractures usually occur in the thoracolumbar region, mid-thoracic vertebra fractures can cause respiratory problems (8). The aim of the treatment of symptomatic vertebral collapse fractures is to correct the vertebral height, reduce the kyphosis angle and increase the quality of life (9).

In mid-thoracic vertebral kyphoplasties, the small pedicle size of the vertebra, the risk of pneumothorax and segmental artery injury, and the presence of severe angulation caused by kyphosis not found in the lower thoracic and lumbar regions may pose special difficulties (10).

The bilateral kyphoplasty approach has recently been replaced by the unilateral kyphoplasty approach due to shorter operation times, less radiation exposure, and lower complication rates (11). In the meta-analysis of Huang et al., the operation time was reported to be shorter in unilateral kyphoplasties. In our study, we applied the unilateral kyphoplasty approach to all our patients. The mean operation time was determined as 40.18±15.01 minutes.

It has been previously stated that spinal strength is directly related to the amount of cement injection (12). In the study by Belkoff et al. showing the mechanical effect of the amount of cement on the vertebra, it was reported that administering 2 ml of bone cement to the vertebral corpus may be sufficient to fulfill the corpus strength. Nevertheless, they recommended 4 ml of bone cement to the thoracic vertebral corpus and 6 ml of bone cement to the lumbar region to regain strength (13). The mean amount of cement used in our study was 3.68±1.13 ml, and it was similar to the literature.

As stated above, the main purpose in the treatment of vertebral fractures is to restore the fractured vertebra to its former height and correct

the related kyphosis angle. Ge et al. compared vertebral anterior and median heights in the preop and postop period after extrapedicular thoracic kyphoplasty and found significant improvements in their follow-up. In our study, the anterior and median vertebrae heights of the mid-thoracic vertebrae were compared in the preop and early postop period, and the increased values were found to be significant, similar to the literature. This result suggests that the balloon used in kyphoplasty is an effective material to restore the vertebral corpus. In the meta-analysis of Wang et al. comparing vertebroplasty and balloon kyphoplasty, it was revealed that the use of balloons significantly reduced the angle of kyphosis (14). In our study, kyphoplasty balloons were used at different vertebral levels in sizes suitable for the vertebra, and it was found that the kyphosis angle was significantly reduced compared to the preoperative period.

Kyphoplasty complications include cement leakage, new or adjacent segment fractures, pulmonary embolism, spinal cord compression, radiculopathy, infections, and mortality (15). In the meta-analysis of Bouza et al. on balloon kyphoplasty, the cement leakage rate was found to be 18.3% (16). In our study, the rate of cement leakage was 42.9%, and it is a high rate compared to the literature. However, only mid-thoracic segment vertebrae were included in the study. Although it is related to the fracture type, the most common leakage was into the intradiscal space at a rate of 17.9%. This result indicates that the upper and lower endplates at the fractured vertebra levels are affected as well. Precautions to be taken before and during the surgical procedure would minimize the risk of cement leakage. These include examining the imaging of the patient before the operation adequately, avoiding repetitive attempts at the same vertebral point, increasing cement viscosity during injection, and stopping the procedure, and

waiting for cement leakage during fluoroscopy control. Nevertheless, surgeons should have detailed knowledge of thoracic vertebra anatomy and sufficient experience in spine surgery.

The length of stay in the hospital after the operation depends on the general condition of the patient, the cause of the trauma, but also varies according to the surgical team and the conditions of the health institution. In the study of Ge et al. in which they gave information about the extrapedicular approach technique to the thoracic vertebra, the mean post-operative hospital stay was 5.1 days (17). In our study, this period was calculated as 4.42 ± 0.69 hours. The reason for stating the duration of hospital stay in days in the study of Ge et al. might be due to a new surgical access method was tried in the patients, and the complications that may occur afterward could not be predicted. In our study, we used the classical transpedicular entry method. In addition, our patients had only isolated thoracic vertebral fractures as a result of trauma. Since they did not have any pathologies requiring long-term follow-up, the patients were mobilized and discharged after hourly follow-up.

CONCLUSION

In our study, the effect of the balloon kyphoplasty method applied in the mid-thoracic vertebral collapse on vertebra anterior and median heights were investigated. The types of cement leakage were determined as complications that may occur while applying this treatment method. Before and after the operation, kyphosis angle changes were calculated. It was observed that the balloon kyphoplasty method was effective in restoring the vertebra to its previous height and correcting the kyphosis angle.

Conflict of interest: The authors report no relevant conflict of interest or disclosures relevant to this viewpoint.

References

1. Lavelle WF, Khaleel MA, Cheney R, Demers E, Carl AL. Effect of kyphoplasty on survival after vertebral compression fractures. *Spine J.* 2008; 8 (5): 763-9.
2. Kasper DM. Kyphoplasty. *Semin Intervent Radiol.* 2010; 27 (2): 172-84.
3. Edidin AA, Ong KL, Lau E, Kurtz SM. Mortality risk for operated and nonoperated vertebral fracture patients in the medicare population. *J Bone Miner Res.* 2011; 26 (7): 1617-26.
4. Hiwatashi A, Moritani T, Numaguchi Y, Westesson PL. Increase in vertebral body height after vertebroplasty. *AJNR Am J Neuroradiol.* 2003; 24 (2): 185-9.

5. Teyssedou S, Saget M, Pries P. Kyphoplasty and vertebroplasty. *Orthop Traumatol Surg Res.* 2014 ;100 (1 Suppl): S169-79.
6. Garnier L, Tonetti J, Bodin A, Vouaillat H, Merloz P, Assaker R, et al. Kyphoplasty versus vertebroplasty in osteoporotic thoracolumbar spine fractures. Short-term retrospective review of a multicentre cohort of 127 consecutive patients. *Orthop Traumatol Surg Res.* 2012; 98 (6 Suppl): S112-9.
7. Wardlaw D, Cummings SR, Van Meirhaeghe J, Bastian L, Tillman JB, Ranstam J, et al. Efficacy and safety of balloon kyphoplasty compared with non-surgical care for vertebral compression fracture (FREE): a randomised controlled trial. *Lancet.* 2009; 373 (9668): 1016-24.
8. Leech JA, Dulberg C, Kellie S, Pattee L, Gay J. Relationship of lung function to severity of osteoporosis in women. *Am Rev Respir Dis.* 1990; 141 (1): 68-71.
9. Kircelli A, Coven I. Percutaneous Balloon Kyphoplasty Vertebral Augmentation for Compression Fracture Due to Vertebral Metastasis: A 12-Month Retrospective Clinical Study in 72 Patients. *Med Sci Monit.* 2018; 24: 2142-8.
10. Kim HS, Kim SW, Ju CI. Balloon Kyphoplasty through Extrapedicular Approach in the Treatment of Middle Thoracic Osteoporotic Compression Fracture : T5-T8 Level. *J Korean Neurosurg Soc.* 2007; 42 (5): 363-6.
11. Huang Z, Wan S, Ning L, Han S. Is unilateral kyphoplasty as effective and safe as bilateral kyphoplasties for osteoporotic vertebral compression fractures? A meta-analysis. *Clin Orthop Relat Res.* 2014; 472 (9): 2833-42.
12. Liebschner MA, Rosenberg WS, Keaveny TM. Effects of bone cement volume and distribution on vertebral stiffness after vertebroplasty. *Spine (Phila Pa 1976).* 2001; 26 (14): 1547-54.
13. Belkoff SM, Mathis JM, Jasper LE, Deramond H. The biomechanics of vertebroplasty. The effect of cement volume on mechanical behavior. *Spine (Phila Pa 1976).* 2001; 26 (14): 1537-41.
14. Wang H, Sribastav SS, Ye F, Yang C, Wang J, Liu H, et al. Comparison of Percutaneous Vertebroplasty and Balloon Kyphoplasty for the Treatment of Single Level Vertebral Compression Fractures: A Meta-analysis of the Literature. *Pain Physician.* 2015; 18 (3): 209-22.
15. Taylor RS, Fritzell P, Taylor RJ. Balloon kyphoplasty in the management of vertebral compression fractures: an updated systematic review and meta-analysis. *Eur Spine J.* 2007; 16 (8): 1085-100.
16. Bouza C, Lopez-Cuadrado T, Almendro N, Amate JM. Safety of balloon kyphoplasty in the treatment of osteoporotic vertebral compression fractures in Europe: a meta-analysis of randomized controlled trials. *Eur Spine J.* 2015; 24 (4): 715-23.
17. Ge J, Cheng X, Li P, Yang H, Zou J. The Clinical Effect of Kyphoplasty Using the Extrapedicular Approach in the Treatment of Thoracic Osteoporotic Vertebral Compression Fracture. *World Neurosurg.* 2019; 131: e284-e9.