

A comprehensive analysis of subungual melanomas in a tertiary center:

Is amputation outmoded?

Bir üçüncü basamak merkezde subungual melanomların kapsamlı analizi:

Amputasyon eski bir seçenek mi?

Mehmet Emre Yeğin^{ID}

Vasif Mammadov^{ID}

Ege Topaloğlu^{ID}

Ersin Gür^{ID}

Yiğit Özer Tiftikcioğlu^{ID}

Tahir Gürler^{ID}

Ege University Faculty of Medicine, Plastic, Reconstructive and Aesthetic Surgery Department, Izmir, Türkiye

ABSTRACT

Aim: Subungual melanoma is a rare entity. The literature lacks information about its treatment. Alternative treatments exist; amputation or wide local excision (WLE), with or without sentinel lymph node biopsy (SLNB). This study discusses the classical approach for subungual melanoma and compares it with the alternatives.

Materials and Methods: A retrospective analysis of subungual melanoma cases between 2008 and 2020 in a tertiary center was done.

Results: Thirteen patients were found to have subungual melanoma. Amputation and SLNB were the treatment of choice in 12 patients with invasive diseases. In one patient with a in-situ illness, WLE and SLNB were applied. Mean Breslow thickness was found to be 4.2 mm. The preoperative evaluation showed no signs of metastases in 10 patients, and these patients had SLNB. Two patients had pathological lymph node characteristics in the preoperative evaluation and had elective lymph node dissection (ELND) without SLNB. The mean follow-up was six years, and seven patients died during the follow-ups. Six patients died of natural causes, while one died of systemic disease.

Conclusion: Subungual melanoma is a disease that can be controlled with amputation. WLE can be used in in-situ melanomas, but amputation is still a good choice for invasive illnesses.

Keywords: Amputation, lymph node dissection, melanoma, neoplasm metastasis, sentinel lymph node.

ÖZ

Amaç: Subungual melanom nadir görülen bir durumdur. Literatürde tedavisi hakkında detaylı bilgi bulunmamaktadır. Alternatif tedaviler mevcuttur; sentinel lenf nodu diseksiyonu ile birlikte veya yalnızca amputasyon veya geniş lokal eksizyon (WLE) uygulanabilmektedir. Bu çalışmada subungual melanom için klasik yaklaşım tartışılmış ve alternatifleri ile karşılaştırılmıştır.

Gereç ve Yöntem: Üçüncü basamak bir merkezde 2008 ve 2020 yılları arasındaki subungual melanom vakalarının retrospektif analizi yapılmıştır.

Bulgular: 13 hastada subungual melanom tespit edilmiştir. İnvaziv hastalığı olan 12 hastada tedavi ampütasyon ve SLNB'dir. Yalnızca in-situ melanomu olan bir hastaya, WLE ve SLNB uygulanmıştır. Ortalama Breslow kalınlığı 4,2 mm'dir. Ameliyat öncesi değerlendirmede hastaların 10'unda metastaz bulgusu görülmemiş ve bu hastalara SLNB uygulanmıştır. İki hastada preoperatif değerlendirmede patolojik lenf nodu özellikleri saptanmış ve SLNB'siz elektif lenf nodu diseksiyonu (ELND) tedaviye eklenmiştir. Ortalama takip süresi 6 yıldır ve takipler sırasında 7 hasta kaybedilmiştir. Hastaların altısı doğal nedenlerle, bir hasta ise sistemik hastalıklardan kaybedilmiştir.

Corresponding author: Mehmet Emre Yeğin
Ege University Faculty of Medicine, Plastic, Reconstructive and
Aesthetic Surgery Department, Izmir, Türkiye
E-posta: mehmetemreyegin@yahoo.com
Application date: 23.05.2022 Accepted: 03.10.2022

Sonuç: Subungual melanom amputasyon ile kontrol altına alınabilen bir hastalıktır. WLE, in-situ melanomlarda kullanılabilir; ancak amputasyon invaziv hastalıklar için hala iyi bir seçimdir.

Anahtar Sözcükler: Amputasyon, lenf nodu diseksiyonu, melanom, neoplazi metastazi, sentinel lenf nodu.

INTRODUCTION

Subungual melanoma is a rare malignant melanoma subtype (1). Due to its atypical localization, it is known that the time elapsed from the onset of the symptom to the moment of diagnosis takes a long most time, and advanced disease can be encountered in diagnosis (2, 3). In addition to the atypical localization, the lack of consensus on many issues related to the disease and the low counts of described cases in the literature cause differences in treatment and follow-up approach in various clinics (2).

Recently, literature discussing the surgical treatment of subungual melanoma has begun to include wide local excisions instead of amputations (2, 4). In our clinic, amputation and SLNB are applied in accordance with the literature. In this study, the problems and the solution methods we encounter in our cases are explained.

MATERIALS and METHODS

This study was approved by the local ethical committee on 29/01/2021 with approval number 21-1.1T/17. Patients diagnosed with malignant melanoma between 2008 and 2020 were retrospectively analyzed. Thirteen patients with subungual-localized melanoma were identified out of 632 melanoma patients for whom operations were held in our clinic. We collected data about gender, age at the diagnosis, histopathological features such as regression, Breslow thickness, and Clark level, mitosis, ulceration, satellite, lympho-vascular invasion, performed surgeries, sentinel lymph node and regional lymph node dissection results, recurrence, survival time, primary tumor localization, systemic metastasis from previous chart records of the patients.

RESULTS

A total of thirteen patients were found to have subungual melanoma. Eight of thirteen patients were male (61%), and five were female (39%).

The mean age at diagnosis was 64 years (min. 30, max. 88). Mean Breslow thickness was 4.2mm (min. 0.83mm, max.12mm). None of our patients had distant metastases at the time of diagnosis.

Subungual melanoma histopathological subtypes were NOS in two (15%) and acral lentiginous in eleven (85%) of our patients. After the excisional biopsy, one patient's defect, whom the pathological diagnosis was malignant melanoma in situ (7%), was reconstructed with wide local excision and cross finger flap. In contrast, the other patients' defects, whose pathological diagnoses were invasive malignant melanoma (93%) and had an amputation at different levels, had stump repair was performed In seven patients (53%), first finger of the hand in three patients (23%) the first finger of the foot, in two patients (15%) fourth finger of the hand, and one patient (7%) the fifth finger of the hand was involved. In ten of thirteen patients, the first finger of the hand or foot was involved. (Figure-1 and Figure-2) Lymph node dissection with amputation was performed in two patients (15%) with suspicious lymph nodes detected on preop imaging. One of them was metastatic in axillary lymph node dissection. The other patient, who had a previous history of Chronic Lymphocytic Leukemia, was found to have reactive lymph nodes in popliteal lymph node dissection and CLL-affected lymph nodes in inguinal lymph node dissection. Axillary dissection was performed in two patients (15%) who were found to have metastatic lymph nodes by sentinel lymph node biopsy. Reactive lymph nodes were reported in their pathology report. The mean follow-up time was six years (min. six months, max. 12 years). None of the patients presented with recurrence in follow-ups. Seven of thirteen patients passed away during follow-ups. Only one of the patients was found to die because of systemic disease. Six other patients died because of natural causes, such as MI or Chronic Obstructive Pulmonary Disease (COLD) (Table-1).

Table-1. Demographics and surgical treatments of the patients. NOS: Non-specified subtype, LM: Lentigo Melanoma, ALM: Acral Lentiginous Melanoma, ALMis: In-situ ALM, MTPA: Amputation at Metatarsophalangeal Joint level, MCPA: Amputation at Metacarpophalangeal Joint level, IPA: Amputation at Interphalangeal Joint Level, PIPA: Amputation at Proximal Interphalangeal Joint level, DIPA: Amputation at Distal Interphalangeal Joint level, WLE: Wide Local Excision, SLNB: Sentinel Lymph Node Biopsy, LND: Lymph Node Dissection, Ax.: Axillary, Ing.: Inguinal, Pop.: Popliteal.

Patients	Localization, Type	Age	Death Age & Cause	Surg.	Result	Breslow (mm)	LN D	TNM	Cl. Stage	Path. Stage
#1	Left foot D1, NOS	64	65 SVO	MTPA + SLNB	NOS + 1R	4.6	-	T4aN 0M0	IIb	IIb
#2	Left hand D1, LM	62	-	MCP A+SLNB	ALM+ 4R	0.83	-	T1bN 0M0	Ib	Ib
#3	Left hand D4, ALM	70	71 SVO	MTPA + SLNB	ALM + 6R	-	-	T3bN 0M0	IIb	IIb
#4	Right hand D4, ALM	88	90 BrCa	MCP A + SLNB	ALM+ 1M1R	30	Ax. 0/14	T4bN 1aM0	III	IIIc
#5	Right hand D1, NOS	44	45 MI	DIPA + SLNB	NOS+ 1M	12	Ax. 0/6	T4bN 1aM0	III	IIIc
#6	Right foot D1, ALM	71	73 COLD	MTPA + LND	ALM+ 6R	1.7	Pop 0/3, ing. 0/3	T2aN 0M0	Ib	Ib
#7	Left hand D1, ALM	59	-	MPA+ SLNB	ALM+ 1R	2.6	-	T3aN 0M0	IIa	IIa
#8	Left hand D1, ALM	47	-	DIPA	ALM	2.66	-	T3aN 2bM0	III	IIIb
#9	Right hand D1, ALM	79	79 MI	PrA	ALM	6	-	T4bN 0M0	IIc	IIc
#10	Right hand D5, ALMis	30	-	WLE + Cross finger +SLNB	ALMis	-	-	Tis	0	0
#11	Right hand D1, ALM	73	79 M1 disease	PIPA + SLNB	ALM	3	-	T3aN 0M0	IIa	IIa
#12	Left foot D1, ALM	79	-	DIPA + SLNB	ALM+ 1R	2.9	-	T3aN 0M0	IIa	IIa
#13	Left hand D1, ALM	68	-	IPA + LND	ALM+ 2M	8	Ax. 2/14	T43b N2bM0	III	IIIc

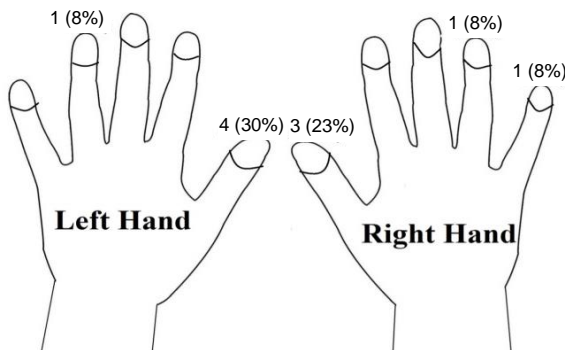


Figure-1. Hand subungual melanoma involvement sites.

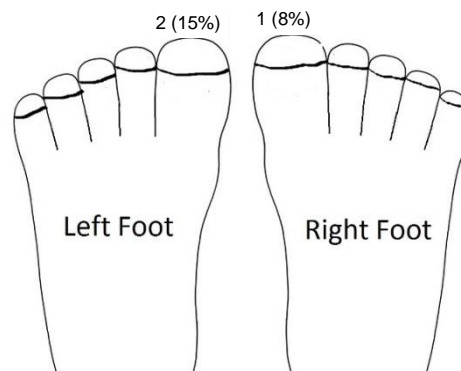


Figure-2. Foot subungual melanoma involvement sites.

DISCUSSION

Our study includes patients with subungual malignant melanoma in a retrospective analysis. In our clinical practice, excisional biopsy is performed after nail extraction in patients with suspected subungual melanoma, amputation for wide local excision, and sentinel lymph node biopsy is applied to all patients if the relevant lesion is detected as malignant melanoma.

Subungual melanoma is a rare subtype of malignant melanoma and is not often encountered in daily practice. Controversial to the significant role of UV exposure in the etiology of malignant melanoma, it is speculated that trauma may play a significant role in the etiology of subungual melanomas (5). It takes a more significant portion of melanomas in blacks and Asian races, even though the incidence of subungual melanoma is similar in all races (3). Interestingly, subungual melanomas are relatively rare in Caucasian people because the prevalence of melanomas in the other areas of the body is more encountered than in blacks and Asians. Since the Turkish population also belongs to the Caucasian race, it can be expected to detect subungual melanoma in only thirteen of 632 patients.

It has been reported in previous publications that the time from the onset of symptoms to diagnosis of subungual melanoma is longer than in other melanomas (2, 3, 5). Our findings also support this. Delayed diagnose causes advanced stage and lymph node involvement at the time of diagnosis (3). It is reported that the tumor thickness and disease stage are prognostic factors (6). Among the reasons for the late diagnosis of the patients, atypical localization, misdiagnosed with other conditions such as hematoma, melanonychia, and onychomycosis and the lack of suspicion of a severe problem, and delayed referring to health institutions can be listed (2, 7). It is important to perform an early excisional biopsy for differential diagnoses with other similar clinical situations. Full-thickness biopsy should be preferred to obtain as much accurate information about the tumor as possible (8). Reilly et al. reported not only the acral lentiginous histopathological subtype of subungual melanoma but also nodular, superficially spreading, and epithelioid subtypes (3). Yet, we identified only acral lentiginous and NOS subtypes in our study.

There is a dispute regarding the surgical treatment of subungual melanoma. Especially in recent years, many publications argue that the traditional treatment method for subungual melanoma, amputation, should be replaced with wide local excision (2). However, as there is no consensus in the literature, we believe amputation might be a better choice due to the close anatomical relationship with the distal phalanx. In our clinic, patients diagnosed with subungual melanoma after an excisional biopsy with nail extraction, affected fingers are routinely amputated at the MCP, PIP, or DIP level, depending on the proximity of the tumor borders. The literature has reported that there is no difference in the local recurrence between more proximal and distal amputations like ours (9, 10). In only the patient diagnosed with malignant melanoma in situ, rather than amputation, only wide local excision was performed. Since in situ melanoma is a more benign entity, we performed a more conservative surgery, which is congruent with the literature (2). Moreover, our clinic is a tertiary center and receives patients from surrounding settlements. We frequently encounter patients that miss their follow-ups due to the limited transportation utilities. Reconstruction after wide local excision requires close follow-up for recurrence. Considering all of these factors, we suggest that amputation is a better option for disease control. For reconstruction, various methods such as skin graft, local flap, or free flap after wide local excision of subungual melanoma have been reported (9, 11, 12). We perform stump closure with a volar skin flap after amputation. Only in the patient with in-situ subungual melanoma we reconstructed the defect with cross finger flap after wide local excision.

There is no definite opinion in the literature about routine dissections after a positive SLNB, whether it increases overall survival in patients with subungual melanoma or not (3). Yet, in our algorithm, we apply SLNB to every patient diagnosed with subungual melanoma and perform complementary dissection in case of sentinel lymph node involvement. We cannot obtain a healthy statistical analysis with only twelve patients, but our data can be used in future studies.

Since it is a rare disease, various publications from various centers are essential to gain comprehensive, unprejudiced information. From our point of view, being a tertiary center grants a

possibility of suffering from referral bias for studies. Additionally, as it is a rare malignant melanoma subtype, our study lacks a large population. Inherently, however, there are a few cases in the literature, and there are areas open to discussion, such as surgical treatment options, sentinel lymph node sampling, and regional lymph node dissection. In future meta-analysis, focusing on these issues will expand our knowledge. Furthermore, publications in which amputation is advocated may have been short in recent years. However, to better evaluate and support wide local excision as a contrary technique, we believe results of algorithms that use amputation as a preferred technique should be adequately represented in future meta-

analyses since any counterbalance may cause us to suffer from publication bias and distorted apprehension.

CONCLUSIONS

There is no consensus in the literature regarding the surgical treatment of subungual melanoma. Publications are advocating both amputation and wide local excision. Considering the lack of agreement regarding sentinel lymph node sampling and dissection decisions, we can say that future publications on this subject will help shape our approach to subungual melanoma.

Acknowledgements: The authors report that there are no competing interests to declare.

References

1. Dawber RP, Colver GB. The spectrum of malignant melanoma of the nail apparatus. *Seminars in dermatology* 1991;10(1):82-7.
2. Cochran AM, Buchanan PJ, Bueno Jr RA, Neumeister MW. Subungual melanoma: a review of current treatment. *Plastic and reconstructive surgery*, 2014;134(2):259-73.
3. Reilly DJ, Aksakal G, Gilmour RF, Gyorki DE, Chauhan A, Webb A, Henderson MA. Subungual melanoma: Management in the modern era. *Journal of Plastic, Reconstructive & Aesthetic Surgery* 2017;70(12):1746-52.
4. Anda-Juárez MCD, Martínez-Velasco MA, Fonte-Ávalos V, Toussaint-Caire S, Domínguez-Cherit J. Conservative surgical management of in situ subungual melanoma: long-term follow-up. *Anais brasileiros de dermatologia* 2016;91(6):846-8.
5. Möhrle M, Häfner HM. Is subungual melanoma related to trauma? *Dermatology* 2002;204(4):259-61.
6. Cohen T, Busam KJ, Patel A, Brady MS. Subungual melanoma: management considerations. *The American journal of surgery* 2008;195(2):244-8.
7. Deinlein T, Hofmann-Wellenhof R, Zalaudek I. Acral melanoma mimicking subungual hematoma. *J Am Acad Dermatol*. 2016;75(5):e181-e183. doi:10.1016/j.jaad.2016.02.12228.
8. O'Connor EA, Dzwierzynski W. Longitudinal melonychia: clinical evaluation and biopsy technique. *J Hand Surg Am*. 2011;36(11):1852-1854. doi:10.1016/j.jhssa.2011.08.029.
9. Rayatt SS, Dancey AL, Davison PM. Thumb subungual melanoma: is amputation necessary?. *J Plast Reconstr Aesthet Surg*. 2007;60(6):635-638. doi:10.1016/j.bjps.2006.10.014.
10. Quinn MJ, Thompson JE, Crotty K, McCarthy WH, Coates AS. Subungual melanoma of the hand. *J Hand Surg Am*. 1996;21(3):506-511. doi:10.1016/S0363-5023(96)80371-6.
11. Oh BH, Jang HS, Lee J, Choi MJ, Nam KA, Chung KY. Delayed Reconstruction for the Non-Amputative Treatment of Subungual Melanoma. *Ann Dermatol*. 2015;27(4):417-422. doi:10.5021/ad.2015.27.4.417.
12. Lee KT, Park BY, Kim EJ, et al. Superthin SCIP Flap for Reconstruction of Subungual Melanoma: Aesthetic Functional Surgery. *Plast Reconstr Surg*. 2017;140(6):1278-1289. doi:10.1097/PRS.0000000000003881.