



COLLECTING DUCT (BELLINI DUCT) CARCINOMA OF KIDNEY : TWO CASE REPORTS

BÖBREĞİN TOPLAYICI DUKTUS (BELLİNİ DUKTUS) KARSİNOMU : İKİ OLGU SUNUMU

Aylin Orgen ÇALLI

Ayşegül Akder SARI

Murat ERMETE

Filiz DAĞ

Izmir Training and Research Hospital Department of Pathology

Anahtar Sözcükler : böbrek karsinomu, toplayıcı duktus, bellini duktus

Key Words : renal carcinoma, collecting duct, bellini ductus

ABSTRACT

Collecting duct carcinomas are usually large tumors located in the medulla or central parts of the kidney with extension into the perinephric fat and invasion of the renal pelvis. In this report, the clinicopathological features of two cases of Bellini's duct carcinoma are presented to add to review of the related literature.

ÖZET

Toplayıcı duktus karsinomları sıklıkla perinefritik yağ dokusuna yayılım ve renal pelvise invazyon gösteren, böbreğin medulla ya da santral kısımlarında lokalize büyük tümörleridir. Bu yazıda iki Bellini duktus karsinom olgusunun klinikopatolojik özellikleri ilgili literatürler eşliğinde sunulmaktadır.

INTRODUCTION

Collecting duct carcinoma is an unusual variant of renal cell carcinoma with only approximately 100 cases described in the literature to date (1). The first description of collecting duct carcinoma is attributed to Mancilla- Jimenez et al (2) who described three cases of papillary renal cell carcinoma in which atypical hyperplastic changes were noted in the collecting duct epithelium, since that time, there have been a substantial number of reports of collecting duct carcinoma in the literature (1-5). Previous reports have suggested that this tumor originates from the collecting duct epithelium, based on its location in the renal medulla, the histopathological features of the tumor cells and an architecture similar to that of the distal collecting duct tubules. An origin from the collecting duct is further supported by atypical hyperplasia of the collecting duct epithelium adjacent to the neoplasm as well as immunohistochemical studies (1,4,5). In view of the paucity of reports, we deemed it in opportune time to describe the results of microscopic and immunohistochemical studies of two cases of our own experience.

CASE REPORT

Clinical findings

Case 1 - A 67-year-old woman developed left flank pain and macroscopic haematuria one months prior to admission to our hospital. An ultrasonogram and computerized tomography scan were performed and revealed a left kidney tumor measuring up to 7 cm in diameter. The patient underwent left radical nephroadrenalectomy with a preoperative diagnosis of renal tumor.

Case 2 - A 49-year-old woman presented with bilateral groin and left flank pain. Physical examination, which was within normal limits, revealed a febrile woman with stable vital signs. At abdominal ultrasound examination 3 cm nodule in the superior pole of the left kidney was noticed. The patient underwent left radical nephrectomy.

Gross Pathology

In both of the cases; macroscopic appearances were similar. The tumors were firm, grayish-white in color, lobulated, and ranged from 5 to 6cm. They were ill defined or poorly circumscribed lesions occupying most or a large part of the renal parenchyma. In Case 2, enlarged lymph nodes were found in the hilar region of the kidney.

Microscopic pathology

Light microscopy showed that the tumors had papillary and infiltrating ductal architectures. Some ducts had prolongations suggesting invasive features (Figure 1). Papillae with true fibrovascular cores were lined by cuboidal to columnar cells with pleomorphic hyperchromatic nuclei, prominent eosinophilic macronuclei and abundant eosinophilic cytoplasm and hobnail appearance. The cells were similar to the collecting duct epithelium. Typically, these tumors were of high nuclear grade corresponding to Fuhrman grades 3 or 4. There were collections of cells with acinar formation infiltrating through a desmoplastic stroma. Either necrosis or mitotic activity was present in both of the tumors. Areas of

necrosis were prominent in Case 2 (Figure2) . In Case 2, a neutrophilic infiltrate was seen within and around the tumor. Five metastatic lymph nodes were identified in 15 lymph nodes in Case 2.




Figure 1. Irregular angulated tubules are associated with striking stromal desmoplasia (H&E x100)

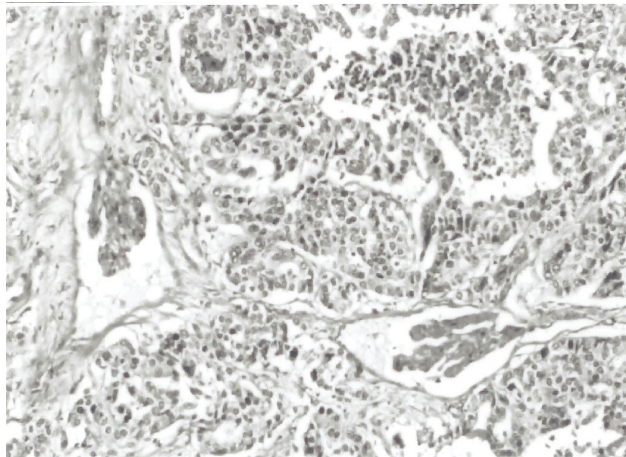


Figure 2. Case no : 1. tubules are less well formed and there is nuclear anaplasia, and focus of necrosis (H&E x200)

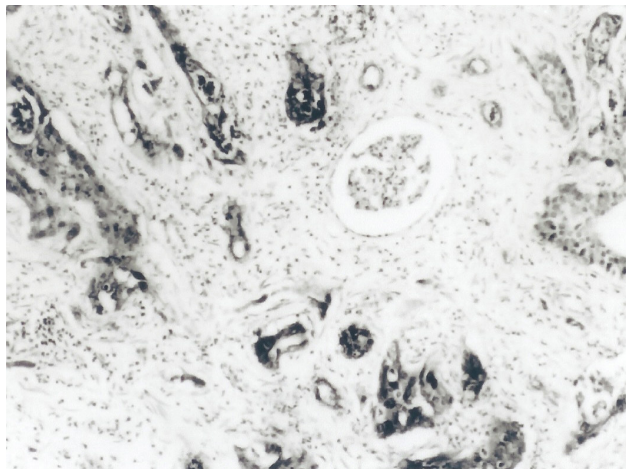


Figure 3A. Case No : 1. tumor cells show cytoplasmic positivity with antibodies to UEA-1. (Hematoxylin counterstain: magnification x200)

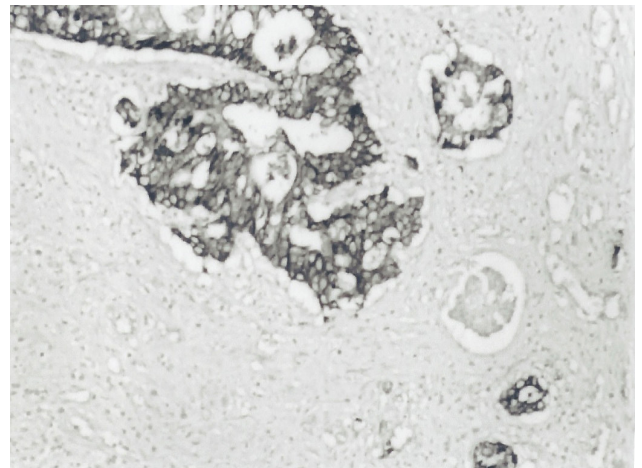


Figure 3B. Positive immunostaining for high molecular weight cytokeratin (34BE12). (Hematoxylin counterstain: magnification x200)

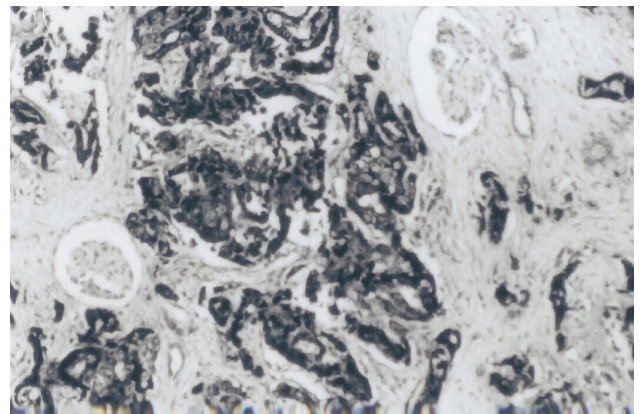


Figure 3C. Strong positive staining for CEA in the tumor cells. (Hematoxylin counterstain: magnification x400)

Immunohistochemistry

High-molecular weight keratin (34BE12), Ulex europaeus agglutinin-1 (UEA-1), and carcinoembryonic antigen (CEA) which commonly have affinity for collecting duct carcinoma were also strongly positive in our cases (Figure 3A,B,C). Vimentin and epithelial membrane antigen were negative in both of the cases. Leu-M1 was negative in Case 2, but positive in Case 1.

DISCUSSION

This rare high grade renal cell carcinoma, collecting duct type, accounts for less than 1% of surgical cases (3,6). Its recognition remains somewhat controversial. Collecting duct carcinoma that, in contrast to the usual type, is thought to arise from or differentiate toward collecting (Bellini's) ducts, hence its alternate designation as a Bellini duct carcinoma (4). Since Cromie defined this rare disease, other investigators have subsequently considered its origin as being the collecting duct epithelium of Bellini (1-5). The largest series (six cases) was reported by Fleming and Lewi (7). Fleming and Lewi defined the diagnostic criteria and established collecting duct carcinoma of the kidney as a separate histological entity arising in the renal medulla. These tumors are centered in medulla, have a tubulopapillary architecture, and

surrounded by a desmoplastic reaction (7). These tubules may be of varying dimensions and impart a sponge-like appearance to the tumor (7,8). Often, the edge of the tumor is ill defined and shows extensive permeative pattern of growth. Often, cells with a hobnail pattern are present, sometimes only focally, lining the tubules and microscopic cysts. These are diagnostically helpful because hobnail cells are not seen in other types of renal cell carcinoma (1,8). Hobnail appearance was focally seen in our cases.

In our experience, the most difficult diagnostic problem is distinguishing Bellini's duct carcinoma from papillary renal cell carcinoma. But, collecting duct carcinoma is distinguished from the papillary type of renal cell carcinoma by their location, lack of multifocality, architecture, antigenic expression, and even karyotypic composition. Papillary renal cell carcinomas are often large and have tan, granular-cut surfaces with well-defined borders contrasting with the gray-white coloration and the infiltrative gross appearance of collecting duct carcinoma (1,8). Typically, papillary renal cell carcinoma neither diffusely infiltrate the kidney, nor does it elicit the desmoplastic stromal reaction and acute inflammation that characteristically are associated with collecting duct carcinoma (9). The other important characteristic findings; intensive desmoplastic stromal reaction and diffusely infiltrative pattern were seen in both of our cases. Vascular and lymphatic infiltration are more common in collecting duct carcinoma. Immunohistochemistry is particularly useful for distinguishing collecting duct carcinoma from papillary renal cell carcinoma. Several reports have described a characteristic immunohistochemical profile that includes immunoreactivity for carcinoembryonic antigen (CEA), peanut agglutinin (PNA), and Ulex europaeus agglutinin (UEA) (1,3). The tumor cells usually react with antibodies to broad spectrum and low-molecular weight keratins. High-molecular weight keratin (CK19, 34BE12) is commonly present. Vimentin, Leu-M1 and

lysozyme were variably expressed. The staining pattern supports, but does not prove, an origin from the distal nephron, since high molecular weight cytokeratin and PNA are normally expressed in distal tubule and the collecting ducts but not in the proximal tubular epithelium (1). Papillary renal cell carcinomas often react with antibodies to cytokeratin 7 but frequently lack high molecular weight cytokeratin (1). The histopathologic features and immunohistochemical findings in our cases are consistent with the diagnoses of collecting duct carcinoma.

The number of cases so far identified is too small to know whether their behaviour is significantly different from the usual type, although the available data suggest an aggressive behaviour (5). Most cases reported previously had a tendency for early dissemination and fatal clinical course (5,8). Approximately 35% to 40% of patients have metastases at presentation. Common metastatic sites include regional lymph nodes, bone, lung, and liver. In Case 2, five metastatic lymph nodes were identified in 15 lymph nodes. Immunoreactive agents such as interferon or interleukin, and combination chemotherapy for relapsed disease or metastatic lesions, usually seem to be ineffective (1,5,8). Our first patient (Case 1) refused to take any further therapy including chemotherapy, even though she had developed both lung and liver metastases. She died 21 months after the operation. Unfortunately; the second patient was lost during follow-up.

Identification of the Bellini's duct carcinoma has important diagnostic and, potentially, prognostic ramifications. The diagnostic process should involve meticulous attention to the architectural, histologic, and immunohistochemical findings. Caution should be exercised when infiltrative nature, stromal desmoplasia, dysplasia in adjacent collecting ducts, and expression of high molecular weight cytokeratin are present, and their acceptance should be contingent on the presence of otherwise characteristic histoarchitectural features of collecting duct carcinoma.

REFERENCES

1. Srigley JR, Eble JN. Collecting duct carcinoma of kidney. *Semin Diagn Pathol* 1998;15: 54-67.
2. Mancilla- Jimenez R, Stanley FJ, Blath RA . Papillary renal cell carcinoma, a clinical, radiologic and pathologic study of 34 cases. *Cancer* 1976;98:2469-2480.
3. Kennedy SM, Merino MJ, Linehan WM, et al. Collecting duct carcinoma of the kidney. *Hum Pathol* 1990;21: 449-456.
4. Rumpelt HJ, Störkel S, Moll R, et al. Bellini duct carcinoma : Further evidence for this rare variant of renal cell carcinoma. *Histopathology* 1991;18: 115-122.
5. Dimopoulos MA, Logothetis CJ, Markowitz A, et al. Collecting duct carcinoma of the kidney. *Br J Urol* 1993;71: 388-391.
6. Cromie WJ, Davis CJ, DeTure FA. Atypical carcinoma of kidney, possibly originating from collecting duct epithelium. *Urology* 1979;13: 315-317.
7. Fleming S, Lewi HJE. Collecting duct carcinoma of kidney. *Histopathology* 1986;10: 1131-1141.
8. Natsume O, Ozono S, Futami T, et al. Bellini duct carcinoma, a case report. *Jpn J Clin Oncol* 1997;27: 107-110.
9. Delahunt B, Eble JN. Papillary renal cell carcinoma: a clinicopathologic and immunohistochemical study of 105 tumors. *Mod Pathol.* 1997 ;10:537-544.