

## Familial mediterranean fever in the differantial diagnosis of pediatric acute scrotum

Çocukluk çağında akut skrotum ayırıcı tanısında ailesel akdeniz ateşi

Makay B B<sup>1</sup>, Kefi A<sup>2</sup>, Ünsal E<sup>1</sup>

<sup>1</sup>Dokuz Eylül Üniversitesi Tıp Fakültesi, Çocuk Sağlığı ve Hastalıkları AD

<sup>2</sup>Dokuz Eylül Üniversitesi Tıp Fakültesi, Üroloji AD

### Summary

*The acute pediatric scrotum is a common clinical condition that can present a diagnostic dilemma for even the most experienced physician. The most important condition to rule out is torsion of the testis. Here we present a case of familial Mediterranean fever (FMF) with two episodes of scrotal swelling to remind that FMF should also be considered in the differential diagnosis of pediatric acute scrotum.*

**Key words:** Pediatric acute scrotum, differential diagnosis, familial Mediterranean fever

### Özet

*Pediyatrik akut skrotum, en deneyimli klinisyenler için bile tanı koyması zor bir bilmece olabilir. Ayırıcı tanıda dışlanması gereken en önemli durum testis torsiyonudur. Bu yazıda, pediyatrik akut skrotumun ayırıcı tanısında akıldan tutulmasını hatırlatmak için iki kez skrotal şişlik atağı geçiren bir ailesel Akdeniz ateşi hastası sunduk.*

**Anahtar sözcükler:** akut skrotum, ailesel Akdeniz ateşi

### Introduction

Familial Mediterranean Fever (FMF) is a genetic disorder mainly characterized by recurrent fever, abdominal pain, skin rash, and arthritis. The clinical picture of the disease has been expanded with the description of additional features such as protracted febrile myalgia [1], pericarditis [2], and scrotal swelling [3]. Acute scrotum is rarely seen as a complication of FMF. Here we present a case with recurrent acute scrotum in the course of FMF.

### Case Report

A 5-year-old Turkish boy with FMF was consulted to urology department of our institution with a swollen, red, and painful left scrotum that started the day before admission. He was first seen by a general physician at a local hospital and referred to our center with a provisional diagnosis of testicular torsion. On admission, physical examination showed a swollen, tender and

erythematous left hemiscrotum (Fig 1). The cremasteric reflexes were present. He had no fever or abdominal pain. He was diagnosed at the age of 2, and mutation analysis was homozygous for M694V. He was on regular colchicine, however, he missed a few drug doses in the last days. White blood cell and platelet counts, as well as erythrocyte sedimentation rate were normal. Scrotal ultrasonography showed epididymal and testicular enlargement, scrotal skin thickening, and mild hydrocele on the left side (Fig 2). Nuclear scanning excluded testicular torsion, and unilateral epididymo-orchitis was considered. He had a previous history of similar attack with acute scrotum on the same side two years ago, which was diagnosed as bacterial epididymo-orchitis, and treated with antibiotics. He was considered to have a scrotal attack of FMF. He spontaneously recovered in two days.

Yazışma adresi: Balahan B. MAKAY Dokuz Eylül Üniversitesi Tıp Fakültesi, Çocuk Sağlığı ve Hastalıkları AD, İZMİR

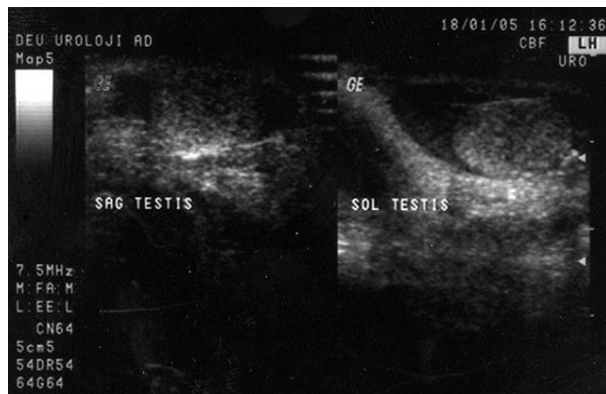
Makalenin geliş tarihi : 18.07.2006 ; kabul tarihi : 20.11.2006

## Discussion

FMF is an inherited disorder mainly characterized by recurrent fever, abdominal pain, skin rash, and arthritis.



**Figure 1.** A swollen left hemi-scrotum



**Figure 2.** Scrotal ultrasonography showing epididymal and testicular enlargement, scrotal skin thickening, and mild hydrocele on the left side.

The disease is most prevalent in people of Sephardic-Jewish, Arabic, Turkish, and Armenian ancestry. Generally, the attacks last within 24 to 72 hours and occur at irregular intervals. The disease-related gene MEFV codes for a protein that guides neutrophil's participation in the inflammation. The symptoms of FMF are due to inflammation of one or more of the serosal membranes such as peritoneum, pleura, and synovium. Thus, FMF is also called "recurrent polyserositis". The tunica vaginalis, an extension of the peritoneal sac, may be affected as well. Therefore the acute scrotum episode is considered to be another attack of the disease.

Acute scrotal swelling in the course of FMF has only been described in a few studies. First was described in 1988 by Eshel et al in Jewish children [3]; followed by Gedalia et al in the same population [4].

Recently, Majeed et al reported the series of acute scrotal attacks of FMF in Arabic children [5]. The frequency of scrotal swelling was ranged between 9-17% and 27-43% of the patients with scrotal involvement had more than one attack [3][5]. In these studies, the genetic mutations of the patients were not reported. It has been previously speculated that homozygotes for M694V experience more severe disease, however a recent nationwide Turkish study did not reveal any correlation between this mutation and severity of FMF [6]. Regarding our patient had this mutation, we speculate if there is a relationship between acute scrotal attacks and M694V mutation. Lausch et al reported another case of FMF homozygous for M694V who developed acute scrotum [7].

The attacks of acute scrotum may accompany peritonitis or occur alone. It is mostly unilateral. Eshel et al demonstrated that peritoneal involvement during an attack of acute scrotum is relatively rare suggesting that this condition is local rather than a generalized peritoneal reaction [8]. This condition is self limiting in 24 to 72 hours and expected to recover completely without significant sequela. Unfortunately, Livneh et al reported a patient with FMF in whom recurrent episodes of acute scrotum complicated by ischemic testicular necrosis [9]. At the third acute scrotal attack of the aforementioned patient, inguinal exploration revealed a thick tunica vaginalis with massive adhesions to testis. In the previous reports, recurrent peritoneal attacks had been shown to result in fibrous bands and adhesions in the abdominal cavity leading to obstructive ileus or strangulation of mesenteric artery causing small bowel necrosis. The scarring and adhesions that occurred during the previous scrotal attacks were considered to be the reason for interruption of testicular blood flow in that patient. So the clinicians remember the potential hazardous outcome of recurrent scrotal attacks in each FMF patient.

The acute pediatric scrotum is a common clinical condition that can present a diagnostic dilemma for even the most experienced physician. The most important condition to rule out is torsion of the testis. Other differentials are torsion of testicular appendages, hydrocele, varicocele, trauma, tumor, idiopathic scrotal edema, FMF, and Henoch-Schönlein purpura (HSP). Scrotal swelling may be the presenting feature of FMF. When the scrotal manifestation precedes the other symptoms of the disease, differential diagnosis from testicular torsion may be much more difficult. Thus each attending physician should keep in mind this entity and look for other signs and symptoms of FMF in all cases presenting with acute scrotum. Approximately 5% of

individuals with FMF have been reported to have HSP [10]. Considering the occurrence of the scrotal swelling in 10 to 15% of boys with HSP, clues for this disease should be looked for even in FMF patients.

Imaging studies, such as radionuclide scanning and color Doppler ultrasonography, are helpful to rule out torsion of the testis. The blood flow of the testis on color doppler ultrasound shows normal or high levels in the case of FMF while it shows lower levels or none at all in the case of testicular torsion. It is really an issue of debate whether to perform imaging studies in a patient with confirmed diagnosis of FMF who experience scrotal swelling. Examination of the cremasteric reflex may facilitate the decision. The cremaster reflex has been reported to be absent in most cases of testicular torsion [11]. The patient's age may be a clue to differentiate

both conditions. Classically, testicular torsion occurs in neonates or during puberty. The acute scrotum of FMF usually appears in young prepubertal boys. The mean age at onset of scrotal swelling was reported as 5.7-6.6 years [5][8]. So, we advocate the use of imaging studies in any patient with suspected testicular torsion, but under no circumstances should that examination replace basic clinical judgement.

Since the involvement of scrotum in FMF is not a typical clinical feature and there is little mention of it in textbooks, physicians have a difficulty in attributing this finding to FMF. It is easily misdiagnosed as testicular torsion leading to unnecessary operations. History of FMF, family history, record of previous attacks of acute scrotum, and spontaneous recovery after 24 to 72 hours help to differentiate these conditions.

### References

1. Langevitz F, Zemer D, Livneh A, Shemer J, Pras M. Protracted febrile myalgia syndrome, in patients with familial Mediterranean fever. *J Rheumatol* 1994; 21:708-9
2. Guindo J, Rodriguez A, Ramio J, Miguel Diaz MA, Subirana MT, et al. Recurrent pericarditis: Relief with colchicine. *Circulation* 1990; 82:1117-20
3. Eshel G, Zemer D, Bar-Yochai A. Acute orchitis in familial Mediterranean fever. *Ann Int Med* 1988; 109:164-5
4. Gedalia A, Mordehai J. Acute scrotal involvement in children with familial Mediterranean fever. *AJDC* 1992; 146:1419-20
5. Majeed HA, Ghandour K, Shahin HM. The acute scrotum in Arab children with familial Mediterranean fever. *Pediatr Surg Int* 2000; 16:72-4
6. Tunca M, Akar S, Onen F, Ozdogan H, Kasapcopur O, et al. Familial Mediterranean fever (FMF) in Turkey: results of a nationwide multicenter study. *Medicine (Baltimore)*. 2005;84(1):1-11.
7. Lausch E, Fisch M, Beetz R. Familial Mediterranean fever as an unusual cause of acute scrotum. *J Urology* 2001; 165:1262-63
8. Eshel G, Vinograd I, Barr J, Zemer D. Acute scrotal pain complicating familial Mediterranean fever in children. *Br J Surg* 1994; 81:894-6
9. Livneh A, Madgar I, Langevitz P, Zemer D. Recurrent episodes of acute scrotum with ischemic testicular necrosis in a patient with familial Mediterranean fever. *J Urology* 1994; 151: 431-2
10. Tekin M, Yalcinkaya F, Tumer N, Akar N, Misirlioglu M, Cakar N. Clinical, laboratory and molecular characteristics of children with Familial Mediterranean Fever-associated vasculitis. *Acta Paediatr* 2000;89:177-82
11. Rabinovitz R. The importance of the cremasteric reflex in acute scrotal swelling in children. *J Urol* 1984;132:89-90.