

## Subserosal mass-like adenomyosis: is it polypoid endometriosis?

### Subserozal kitle benzeri adenomyozis: polipoid endometriozis?

Akbulut M<sup>1</sup>Ege B Ç<sup>1</sup>Bir F<sup>1</sup>Soysal S<sup>2</sup><sup>1</sup>Pamukkale Üniversitesi Tıp Fakültesi Patoloji ABD, DENİZLİ<sup>2</sup>Pamukkale Üniversitesi Tıp Fakültesi Kadın Hastalıkları ve Doğum ABD, DENİZLİ

### Summary

Endometrial tissue is considered ectopic in the uterus if it is present on the uterine serosa (endometriosis) or if it is located excessively deep in the myometrium (adenomyosis). Occasionally, adenomyosis can be seen grossly as an enlarged and globular uterus because of the myometrial hypertrophy accompanies it. A 58-year-old woman underwent vaginal hysterectomy and bilateral salpingo-oophorectomy for endometrial polyp and suspected subserosal leiomyoma. Thus, she was found to have an endometrial polyp and diffuse adenomyosis. Histopathological examination of the subserosal nodule revealed adenomyosis instead of leiomyoma. Subserosal nodular formations of adenomyosis, mimicking leiomyoma is possible even without significant enlargement of the uterus.

**Key Words:** *Adenomyosis, endometriosis, subserosal mass*

### Özet

*Endometriyal doku uterin serozada (endometriyozis) ya da myometriyum içinde (adenomyozis) yerleşmiş ise ektopik olarak değerlendirilir. Arasında, gross incelemede eşlik eden myometriyal hipertrofi nedenli uterus büyümüş ve globuler bir hal almış olabilir. 58 yaşında kadın bir hastada endometriyal polip ve subserozal leiomyom ön tanısı ile vajinal histerektomi ve bilateral salpingooferektomi yapılmıştır. Sonuçta endometriyal polip ve yaygın adenomyozis saptanan hastada, subserozal kitlenin histopatolojik incelemesinde leiomyom yerine adenomyozis izlenmiştir. Subserozal nodüler gelişim gösteren adenomyozis, uterusu belirgin bir büyümeye neden olmadan da leiomyomu taklit edebilir.*

**Anahtar Kelimeler:** *Adenomyozis, endometriyozis, subserozal kitle*

### Introduction

Adenomyosis, a benign penetration of endometrium into the myometrium, is characterized histologically by ectopic endometrial glands and stroma surrounded by hypertrophic and hyperplastic myometrium (1). Endometrial tissue is considered ectopic in the uterus if it is present on the uterine serosa (endometriosis) or if it is located excessively deep in the myometrium (adenomyosis). On macroscopic examination, the cut surface of the myometrium is often trabeculated. But a distinct tumor nodule especially a subserosal mass-like adenomyosis is very rare (2,3).

Here we report a case of subserosal mass-like adenomyosis, which was a finding that initially caused difficulties in diagnosis and raised the question of endometriosis or adenomyoma.

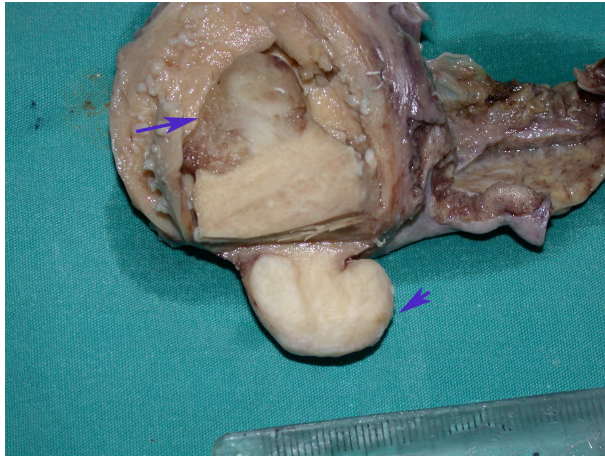
The clinico-pathologic features, pathogenesis and differential diagnosis of a subserosal mass-like adenomyosis are described.

### Case Report

A 58-year-old, gravida 4, para 2, woman presented with postmenopausal bleeding. She had hypertension for which she has been on Hyperium since 5 years. Physical and ultrasound examinations indicated an endometrial polyp and a subserosal fibroid, both in the anterior fundus. Also, histopathologic examination of pre-op curetage of the uterus revealed an endometrial polyp. The patient underwent vaginal hysterectomy and bilateral salpingo-oophorectomy. Postoperative recovery was uneventful.

Yazışma adresi: Metin AKBULUT, Pamukkale Üniversitesi Tıp Fakültesi, Patoloji Anabilim Dalı, DENİZLİ, TURKEY

Makalenin geliş tarihi : 11.07.2006 ; kabul tarihi : 13.03.2007



**Fig. 1** Endometrial polyp and subserosal nodule in the anterior fundus (Large arrow shows endometrial polyp and small arrow shows areas of subserosal nodule containing foci of adenomyosis)

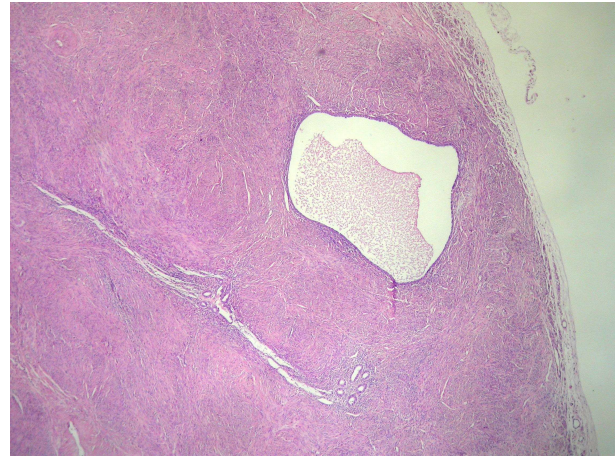
Macroscopically, the uterus, measuring 8x5x3 cm, revealed an endometrial polyp and a subserosal nodule measuring 1,5x1x1 cm in the anterior fundus, but they had no relation between each other (Fig-1). The endometrial polyp was pink-brown. The cut surface of the subserosal nodule was almost white with a punctate and patchy pinkness on it. Macroscopically, the uterine cervix, both ovaries and tubes were unremarkable.

Microscopically, the endometrial glands were atrophic and the glands in the polyp were variously sized and shaped, lined by proliferative epithelium and placed on a fibrovascular stalk. Multiple irregular islands of endometrial glands and stroma were embedded diffusely in the myometrium. Complete histological staining of the uterine subserosal nodule that was considered to be subserosal leiomyoma preoperatively; demonstrated abundant smooth muscle and irregularly distributed benign glands close to the serosal surface.

The glands in the endometrial islands were inactive and lined by benign appearing endometrial epithelium (Fig-2). No atypical features and hemosiderin deposition were identified. Features of conventional endometriosis were not present elsewhere despite of several sections in our patient.

### Discussion

Adenomyosis is easily recognized by the presence of intramyometrial aggregates of endometrial glands and endometrial stromal cells surrounded by hypertrophic smooth muscle (4). Properly oriented section is important in order to avoid misdiagnosing a normal histologic finding as adenomyosis. However; the depth of endometrial penetration before one calls it adenomyosis remains unclear (5-7).



**Fig 2.** Benign glands located close to the subserosal surface (H&E x10)

The presence of myometrial hypertrophy around the foci of adenomyosis and the distance over 25 % of the total thickness of the myometrium between the endomyometrial junction and the closest adenomyotic foci are useful criteria for adenomyosis (6).

Adenomyosis is often found incidentally in 15-30 % of hysterectomy specimens and may be asymptomatic in 50% of cases (5). The symptoms of adenomyosis are believed to be related to the extent of adenomyosis and the depth of adenomyosis penetration and variably presents with a palpably enlarged uterus and/or abnormal bleeding and dysmenorrhea (2,8).

On gross examination the cut surface of the myometrium is trabeculated and contains hemorrhagic foci with sometimes visible cysts. Although it is accepted that a distinct tumor nodule is not present, when it is focal, adenomyosis may mimic a leiomyoma. Clinically, mass-like subserosal nodules of the uterus is almost always considered to be a subserosal leiomyoma, as in this case. Although other conditions such as adenomyosis, endometriosis, adenomyoma and leiomyosarcoma may also result nodular lesions (9).

The differential diagnosis includes endometriosis of serosal uterus (2). Endometriosis is defined as the presence of endometrial tissue outside the endometrium or myometrium and in particular, is a distinctly different disease process from adenomyosis (10,11). Endometriosis may occur anywhere in the body and mimic a neoplasm, because rarely, endometriosis can take the form of polypoid masses that project from the serosal surfaces (12). Also Sakamoto et al suggested that subserosal adenomyosis may develop as a variant of pelvic endometriosis on the basis of distribution of the ectopic tissues and the patients' mean age at the time of the hysterectomy. The uterus was not enlarged in this type of adenomyosis (2).

Appearance varies with the hormonal fluctuations of menstrual cycle. The glands were inactive in appearance. Extensive fibrosis and hemosiderin laden macrophages may be seen. We have no encountered dense fibrous adhesions at laparotomy and obvious fibrosis and hemosiderin deposition adjacent to endometrial islands. Also features of conventional endometriosis were not present elsewhere despite of several sections in our patient. As a result, this lesion may be differentiated from the major variant of Mullerianosis, namely endometriosis, by the absence of evidence of a cyclical hormonal response (haemorrhage) (13).

An adenomyoma is considered as a focal form of adenomyosis and may be difficult to distinguish from uterine leiomyoma on imaging (11). The most common location for adenomyomas is the uterine corpus and

endocervical region (14). Macroscopic gross appearance is usually that of a well circumscribed polypoid mass, cystic areas can be seen on sectioning. The histological appearance of adenomyomas is that of a proliferation of endometrial glands, endometrioid stroma and smooth muscle without atypical features (14). It may usually involve or originate in the endometrium and grow as a polyp or rarely located in the myometrium.

To the best of our knowledge, uterine adenomyosis with mass-like manifestations is rare. Subserosal nodular formations of adenomyosis, mimicking leiomyoma is possible even without significant enlargement of the uterus. Pathologists and clinicians should be aware of the existence of this type of nonneoplastic lesion and should avoid overdiagnosis and overtreatment.

## References

1. Ota H, Igarashi S, Hatazawa J, Tanaka T. Is adenomyosis an immune disease? Hum Reprod Update 1998; 4(4): 360–7.
2. Sakamoto A. Subserosal adenomyosis: a possible variant of pelvic endometriosis. Am J Obstet Gynecol 1991; 165(1): 198–201.
3. Keating S, Quenville NF, Korn GW, Clement PB. Ruptured adenomyotic cyst of the uterus--a case report. Arch Gynecol 1986; 237(3): 169–73.
4. Goldblum JR, Clement PB, Hart WR. Adenomyosis with sparse glands. A potential mimic of low-grade endometrial stromal sarcoma. Am J Clin Pathol 1995; 103(2): 218–23.
5. Azziz R: Adenomyosis: Current perspectives. Obstet Gynecol Clin North Am 1989; 16: 221– 235.
6. Ferenczy A: Pathophysiology of adenomyosis. Hum Reprod Update 1998; 4: 312–322.
7. Tulandi T: Adenomyosis: An old disease deserving a new attention. Hum Reprod Update 1998; 4: 311.
8. Sammour A, Pirwany I, Usbutun A, Arseneau J, Tulandi T. Correlations between extent and spread of adenomyosis and clinical symptoms. Gynecol Obstet Invest 2002; 54(4): 213–6.
9. Fukunaga M. Tumor-like cystic endosalpingiosis of the uterus with florid epithelial proliferation. A case report. APMIS 2004; 112(1): 45–8.
10. Matarese G, De Placido G, Nikas Y, Alviggi C. Pathogenesis of endometriosis: natural immunity dysfunction or autoimmune disease? Trends Mol Med 2003; 9(5): 223–8.
11. Hulka CA, Hall DA, McCarthy K, Simeone J. Sonographic findings in patients with adenomyosis: can sonography assist in predicting extent of disease? AJR Am J Roentgenol 2002; 179(2): 379–83.
12. Dadmanesh F, Young RH, Clement PB (1999) Polypoid endometriosis. A clinicopathologic analysis of 15 cases (abstract). Mod Pathol 12:115A.
13. Heatley MK, Russell P. Florid cystic endosalpingiosis of the uterus. J Clin Pathol 2001; 54(5): 399–400.
14. Gilks CB, Clement PB, Hart WR, Young RH. Uterine adenomyomas excluding atypical adenomyomas and adenomyomas of the endocervical type: a clinicopathologic study of 30 cases of an underemphasized lesion that may cause diagnostic problems with brief consideration of adenomyomas of other female genital tract sites. Int J Gynecol Pathol 2000; 19: 195–205.

*\*It was presented as a poster at the 'XXIII World Congress of Pathology and Laboratory Medicine', 26–30 May, 2005, İstanbul.*