

**Subdural haematoma following spinal anesthesia for cesarean section**

## Sezaryende spinal anestezi sonrası gelişen subdural hematoma

Karaman S Demir F Günüşen İ

Ege Üniversitesi Tıp Fakültesi, Anesteziyoloji ve Reanimasyon Anabilim Dalı, İzmir, Türkiye

**Summary**

Intracranial subdural haematoma is an exceptionally rare complication of spinal anesthesia. A 30 year old pregnant woman was scheduled for an emergency cesarean section. Spinal anesthesia was induced using a 25-gauge needle with an atraumatic bevel. Two days after spinal anesthesia, the patient complained of a typical post-dural puncture headache. Despite oral analgesic, fluid therapy and bed rest, the headache persisted and neurologic complaints accompanied, a MRI was performed and a 2 cm subdural haematoma in the left parietal region was determined. Prolonged headache should be regarded as a warning sign of intracranial subdural haematoma.

**Key Words:** Cesarean section, spinal anesthesia, subdural haematoma.

**Özet**

*Spinal anestezinin son derece nadir komplikasyonlarından biri intrakraniyal subdural hematomdur. Acil sezaryen planlanan 30 yaşındaki gebeye 25-gauge atravmatik iğne ile spinal anestezi uygulandı. İki gün sonrasında hastanın tipik postspinal baş ağrısı şikayetleri oluştu. Oral analjezikler, sıvı tedavisi ve yatak istirahati tedavisine rağmen nörolojik semptomlar gelişmesi ve baş ağrısının kalıcı hale gelmesi üzerine MR çekilen hastada sol parietal bölgede 2 cm subdural hematoma saptandı. Uzamış baş ağrısı intrakranial subdural hematoma açısından uyarıcı bir semptom olarak dikkate alınmalıdır.*

**Anahtar Sözcükler:** Sezaryen, spinal anestezi, subdural hematoma.

**Introduction**

Subdural haematoma is a rare but potentially life-threatening complications of dural puncture after spinal anesthesia or accidental puncture with a Tuohy needle (1-3). The most common complication of spinal anesthesia is post-dural puncture headache (PDPH) (4). Post-dural puncture headache usually appears 24 to 48 hours after dural puncture, and rarely after 7 days. Most headaches last less than a week and 95% of them resolve with 6 weeks (3). Prolonged PDPH may be caused by an intracranial complication such as subdural haematoma (1). This report describes the occurrence of cerebral subdural haematoma in a 30-year-old patient undergoing cesarean section under spinal anesthesia.

**Case**

A 30-year-old woman (58 kg, 160 cm, gravida 1 para 0, at 29 weeks gestation) was scheduled for emergency cesarean section under spinal anesthesia because of early membrane rupture.

She had no history of previous trauma, headache or coagulation abnormalities. Preoperative routine laboratory blood test, including platelet count, prothrombin time and activated prothromboplastin time, were normal at admission. The patient received no anticoagulants. After insertion of a 16 G intravenous cannula, the patient was given 15 ml.kg<sup>-1</sup> balanced crystalloid solution, infused i.v. over 10-15 min before intrathecal injection of the drug. Spinal anesthesia was induced with a 25-gauge Quincke spinal needle (EXELINT®, EXELINT INTERNATIONAL, Co., USA) between L<sub>3/4</sub> interspace in the sitting position at the first attempt. The intrathecal injection of 2.2 ml of 0.5% heavy bupivacaine was completed in 10 seconds after free flow of clear cerebrospinal fluid was observed, and there was no blood or paresthesias. Sensory block height was evaluated with bilateral pin-prick test at the midclavicular line. The operation was started when sensorial block level reached T<sub>4</sub>. No haemodynamic disturbances occurred during spinal anesthesia for the cesarean section, which lasted 50 min. The patient was given 2.9 L of intravenous fluids during the operation. Peri-operatively, the patient complained of shivering which was responded to with 10 mg intravenous pethidine. The

Yazışma Adresi: Semra KARAMAN

Ege Üniversitesi Tıp Fakültesi, Anesteziyoloji ve Reanimasyon Anabilim Dalı, İzmir, Türkiye

Makalenin Geliş Tarihi: 19.08.2010 Kabul Tarihi: 01.10.2010

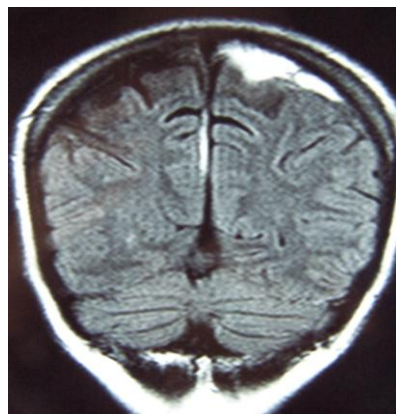
operation was successfully performed and the patient was transferred to the obstetric recovery room.

Two days postoperatively, the patient experienced mild frontal and occipital headache, which was assumed to be a PDPH by the obstetrician, because it was more intense in the sitting position. Bed rest, hydration and NSAID were ordered. The patient and the baby were not discharged because the baby had to be hospitalized in the neonatal unit. After three days, on the 5th postoperative day the patient consulted with the anaesthesiology team because pain persisted. The symptoms were considered to be PDPH and medical treatment which included hydration, bed rest, NSAIDs and paracetamol plus caffeine was ordered. The headache ceased, but on postoperative day 8 the patient experienced a period of weakness and numbness in her right lower extremity which lasted about 2 minutes with the pain's character changing from postural to non-postural. On postpartum day 11 the patient complained of weakness and numbness in the right lower and upper extremity and the right part of her face, which lasted again for 2-3 minutes. Neurologic assessment was performed; the patient was conscious and oriented, she had no sensory or motor loss, or asymmetry. The headache still persisted and because of repeated neurologic complaints, magnetic resonance imaging (MRI) of the cranium was performed. It showed an acute to subacute subdural haematoma in the left parietal region with no mass effect (Figure-1). After neurosurgical evaluation, management of the subdural haematoma consisted of conservative treatment with close observation without surgical intervention. The patient showed a marked clinical improvement. A second MRI scan 15 days later (26 days postoperatively) showed that the left subdural haematoma was still present (Figure-2). It had now decreased in size. The patient was discharged on the 40<sup>th</sup> day and recovered fully 8 weeks after the dural puncture.

## Discussion

Acute intracranial subdural haematoma is rare but a potentially lethal complication that can occur after spinal anesthesia, epidural anesthesia or myelography (1,5,6). A review of the literature shows that several risk factors may be implicated in the development of a subdural haematoma after a spinal anesthesia. These factors include use of large-bore needles (7-11), multiple injection attempts (7,10), patients with alcohol abuse (8), and patients taking anticoagulants (11,12). Cortical atrophy may also present a predisposition to spontaneous subdural haematoma (13).

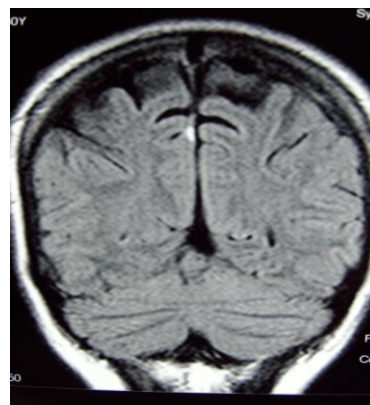
PDPH is the most frequent complication of spinal anesthesia (4). It is possible that parturients are at a high risk of developing PDPH (14).



**Figure-1** Brain MRI scan 11 days after spinal anesthesia showing left-sided subdural haematoma.

The increased incidence of PDPH in parturients may be attributed to numerous factors including peripartum dehydration, which could reduce the production of cerebrospinal fluid (CSF), postpartum diuresis, abrupt release of intra-abdominal pressure and venacaval compression at delivery, which reduces epidural venous pressures. It is probably caused by persistent leakage of CSF through the dural puncture site, with secondary caudal displacement of the brain, resulting in traction on pain-sensitive structures like blood vessels (1,15). These same forces may induce stretching and tearing of cerebral bridging veins, with subsequent hemorrhage and formation of subdural haematomas (1,8). In most cases, PDPH is relieved with bed rest and analgesics. However, if the headache persists, intracranial bleeding may be a cause.

The concurrence of neurological symptoms with PDPH does not mean certainty of the formation of intracranial hemorrhage (14). Continuous loss of CSF leads to intracranial hypotension. Intracranial hypotension is an increasingly recognized neurologic syndrome characterized by postural headache that occurs or worsens shortly after assuming the upright position and disappears or improves after resuming the recumbent position.



**Figure-2.** Brain MRI scan 26 days after spinal anesthesia showing decreasing size of subdural haematoma.

Additional symptoms may include neck pain, nausea, emesis, interscapular pain, photophobia, diplopia, dizziness, change in hearing, visual blurring, cranial nerve palsies and radicular upper extremity symptoms (16). The occurrence of a subdural haematoma increases the intracranial pressure which can be associated with non-postural headache, convulsions, hemiplegia, disorientation and more serious neurological symptoms. Differentiation between the neurological symptoms of intracranial hypotension and subdural haematoma can be difficult. A change in headache characteristics from postural to non-postural should be a warning sign. CT scan of the skull usually gives the correct diagnosis. However, an intracranial haematoma 7-21 days old may have the same radiological density as the brain, so magnetic resonance imaging (MRI) or CT scan with contrast may be more reliable (7). The delayed diagnosis, in many cases, implies that subdural haematoma was not taken into consideration as a complication of spinal anesthesia. In our case, diagnosis was delayed because only the headache persisted, and PDPH is a well known and expected complication, especially in a young female pregnant patient. The patient had short neurologic attacks which could not be determined with a neurologic examination. A neurologic etiology was only taken into consideration when the character of pain changed and the patient's neurologic complaint's repeated.

A review of the literature disclosed 25 cases of subdural haematoma following spinal anesthesia (14). Among these 25 cases, the age of patients ranged between 20 to 88 years. The earliest diagnosis of subdural haematoma was six hours after spinal anesthesia and the latest was 29 weeks. Subdural haematoma after spinal anesthesia occurred most frequently on the left side of the brain (13 cases were left-sided, six right-sided, four bilateral and two were intracerebral).

The management of subdural haematoma is either

conservative or surgical. Small haematomas often resolve spontaneously. Early blood patching may decrease the risk of subdural bleeding by preventing a fall in CSF volume and subsequent intracranial hypotension. However, when an epidural blood patch is performed in the presence of intracranial hemorrhage, rebound intracranial hypertension and neurological deterioration can result. Surgery was performed in 20 of these 25 cases of subdural haematoma following spinal anesthesia in a review of the literature, and was followed by postoperative mortality of four patients (14). The patient in our case was also observed with conservative treatment.

The true incidence of subdural haematoma after dural puncture is not known (1, 14). In most cases, non postural headache and vomiting are the warning signs. In addition, changes in headache characteristics (intractable headache associated with retro-orbital and frontal pains) were observed in most cases. Most patients with headaches are probably treated without further investigations. Small subdural haematomas are known to resolve spontaneously but they may be catastrophic as evident from the deaths recorded as a complication of lumbar puncture. Therefore, the true incidence of subdural haematoma after spinal anesthesia may be greater than the published case reports suggest.

Consequently, when a patient complains of severe, prolonged headache, unrelieved by conservative treatment after spinal anesthesia, the possibility of subdural haematoma should be considered. In these patients, early neurologic or neurosurgical consultation is recommended. Subdural haematoma should be investigated urgently either with computed tomography or magnetic resonance imaging. An early diagnosis of the haematoma may allow medical treatment of subdural haematoma; thus surgical evacuation may be avoided.

## References

1. Acharya R, Chhabra SS, Ratra M, Sehgal AD. Cranial subdural haematoma after spinal anesthesia. *Br J Anesth* 2001; 86: 893-895.
2. Landman UN, Jerome RM, Glass PSA. Subdural hematoma after atraumatic spinal. *J Clin Anesth* 2005; 17: 379-381.
3. Velarde CA, Zuniga RE, Leon RF, et al. Cranial nerve palsy and intracranial subdural hematoma following implantation of intrathecal drug delivery device. *Reg Anesth Pain Med* 2000; 25: 76-78.
4. Macon ME, Armstrong L, Brown EM. Subdural hematoma following spinal anesthesia. *Anesthesiology* 1990; 72: 380-381.
5. Vaughan DJ, Stirrup CA, Robinson PN. Cranial subdural haematoma associated with dural puncture in labour. *Br J Anesth* 2000; 84: 518-520.
6. Suess O, Stendel R, Baur S, et al. Intracranial haemorrhage following lumbar myelography: Case report and review of the literature. *Neuroradiology* 2000; 42: 211-214.
7. Bjarnhall M, Ekseth K, Bostrom S, Vegfors M. Intracranial subdural haematoma: A rare complication following spinal anesthesia. *Acta Anaesth Scand* 1996; 40: 1249-1251.
8. Baldwin LN, Galizia EJ. Bilateral subdural haematomas: A rare diagnostic dilemma following spinal anesthesia. *Anesth Inten Care* 1993; 21: 120-121.
9. Kelsaka E, Sarihasan B, Baris S, Tur A. Subdural hematoma as a late complication of spinal anesthesia. *J Neurosurg Anesth* 2003; 15: 47-49.

10. Van de Kelft E, De la Porte C, Meese G, Adriaensen H. Intracranial subdural hematoma after spinal anesthesia. *Acta Anaesth Belg* 1991; 42: 177-180.
11. Ortiz M, Aliaga L, Baturell C, et al. Intracranial subdural haematoma - a rare complication after spinal anesthesia. *Eur J Anaesth* 1991; 8: 245-248.
12. Cantais E, Behnamou D, Petit D, Palmier B. Acute subdural hematoma following spinal anesthesia with a very small spinal needle. *Anesthesiology* 2000; 93: 1354-1356.
13. Blake D W, Donnan G, Jensen D. Intracranial subdural haematoma after spinal anesthesia. *Anesth Inten Care* 1987; 15: 341-342.
14. Zeidan A, Farhat O, Maliki H, Baraka A. Does postdural puncture headache left untreated lead to subdural hematoma? Case report and review of the literature. *Int J Obstet Anesth* 2006; 15: 50-58.
15. Benzon HT, Wong CA. Postdural puncture headache; mechanisms, treatment, and prevention. *Reg Anesth Pain Med* 2001; 26: 293-295.
16. Mokri B. Headaches caused by decreased intracranial pressure: Diagnosis and management. *Curr Opinion Neuro* 2003; 16: 319-326.