

Unicornuate uterus with non-communicating rudimentary horn mimicking acute abdomen in an adolescent

Adolesanda akut batın tablosunu taklit eden non-komunikan rudimenter horn ile birlikte uterus unikornis

Özlem Dural Cenk Yaşa Funda Güngör Uğurlucan Ercan Baştu Samet Topuz
İstanbul University Faculty of Medicine, Department of Gynecology and Obstetrics, İstanbul, Turkey

Abstract

Unicornuate uterus with a rudimentary horn is the rarest anomaly of the Müllerian system, causing many gynecologic and obstetrical complications and symptoms such as abnormal bleeding, severe dysmenorrhea, and pain. We aimed to report a case of a 17-year-old adolescent presenting with acute abdomen and diagnosed with non-communicating functional rudimentary horn during emergency minilaparotomy and treated afterwards.

Keywords: Unicornuate uterus, rudimentary horn, acute abdomen, dysmenorrhea, Müllerian anomaly, endometriosis.

Öz

Rudimenter horn ile birlikte uterus unikornis en nadir karşılaşılan mülleryan anomalidir ve birçok obstetrik ve jinekolojik komplikasyona ve anormal kanama, dismenore ve ağrı gibi semptomlara neden olabilmektedir. Biz, akut batın tablosu nedeni ile yapılan acil laparotomi sırasında non-komunikan rudimenter horn ile birlikte uterus unikornis tanısı konulan ve definitif tedavisi ikinci bir seansta uygulanan 17 yaşındaki bir adolesan hastayı sunmayı amaçladık.

Anahtar Sözcükler: Uterus unikornis, rudimenter horn, akut batın, dismenore, mülleryan anomali, endometriozis.

Introduction

Congenital uterine anomalies may develop due to abnormal development or fusion of the Müllerian ducts or failure of resorption of the septum and canalization early in the embryonic period (1). In the general population, the incidence of Müllerian anomalies is uncertain and most of the cases are asymptomatic until childbearing age. However, approximately 7% of girls will have a Müllerian anomaly, diagnosed before or after puberty (1). Diagnosis of Müllerian anomalies should be considered in any patient who complains of increasingly severe dysmenorrhea since menarche. Unicornuate uterus with a rudimentary horn is the rarest congenital anomaly of the Müllerian system. It has an estimated prevalence of 1 in 100.000 among women of reproductive age. An estimated 75% of such horns do not communicate with the unicornuate uterus. Overall, approximately 25% of horns are both functional and non-communicating (2).

In the presence of functional endometrium, this anomaly may lead to hematometra, endometriosis and infertility due to retrograde menstruation. When pregnancy occurs in a rudimentary horn, there is a high rate of rupture associated with high morbidity. These horns usually require surgical resection for symptomatic relief and to prevent rudimentary horn pregnancy (3). Most patients present during or after the third decade of life, with abdominal pain or dysmenorrhea (2). Here we report a case of a 17-year-old adolescent presenting with acute abdomen and diagnosed with non-communicating functional rudimentary horn.

Case Report

A 17-year-old girl was admitted to the emergency department of a small center with severe abdominal pain in the left hypogastric area accompanied by nausea and vomiting. Abdominal examination revealed guarding and rebound tenderness at the left iliac (inguinal) area. Her past medical history was unremarkable except for severe dysmenorrhea, which was minimally relieved by analgesics since menarche at age 13. Transabdominal ultrasound revealed a large irregular complex mass resembling an endometrioma of 5.3x6.3 cm in the left hemi-pelvis. White blood cell count was 15.000/mm³.

Corresponding Author: Özlem Dural
İstanbul University Faculty of Medicine, Department of
Gynecology and Obstetrics, İstanbul, Turkey
Received: 07.02.2016 Accepted: 07.03.2016

Because there was no access to laparoscopy, emergent mini laparotomy was performed and revealed severe endometriosis involving the left ovary and posterior cul-de-sac, a left rudimentary horn, left hematosalpinx and a ruptured endometrioma involving the entire left ovary. A normal right unicornuate uterus, tube, and ovary were seen. Ovarian cystectomy was performed. The ruptured endometrial cyst was considered as the main cause of acute abdominal pain. The patient was referred to our tertiary care center for further evaluation prior to definitive surgery while on continuous use of oral contraceptive pills.

During assessment of the patient at our institution, magnetic resonance imaging (MRI) was performed and revealed a right-sided unicornuate uterus with a functional left-sided uterine horn and a single cervix; no renal anomalies were identified (Figure 1A). Four months after the initial surgery, she was taken to the operating room for vaginoscopy and hysteroscopy; single cervix was seen and a single tubal ostium on the left side was observed. Laparotomy was performed for the resection of the rudimentary uterine horn at the same session. On the left side, a rudimentary uterine horn and hematosalpinx were observed (Figure 1B). The left tube and ovary were densely adherent to the pelvic sidewall and colon. Excision of the left rudimentary uterus and the left tube with extensive adhesiolysis was performed.

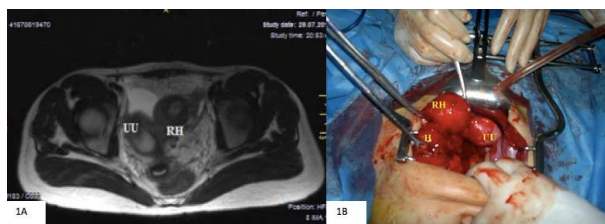


Figure-1. A. Magnetic resonance imaging showing the unicornuate uterus (UU) and the rudimentary horn (RH) **B.** The unicornuate uterus (UU), the rudimentary horn (RH), and the hematosalpinx (H)

Histopathologic examination revealed a rudimentary uterine horn with endometrial tissue. The left tube showed

changes consistent with hematosalpinx. The postoperative course was uneventful. The patient anonymity was preserved and an informed consent form was signed by the patient agreeing with the publication of data.

Discussion

A unicornuate uterus with a non-communicating rudimentary horn develops due to normal development and maturation of one of the Müllerian ducts along with hypoplasia of the contralateral Müllerian duct, resulting in a spectrum of anomalies (4). Congenital uterine anomalies (CONUTA) common ESHRE/ESGE Working Group has classified unicornuate uterus as Class U4 (hemiterus) with and without rudimentary cavity (5).

Obstructive anomalies of the Müllerian system are an uncommon cause of adolescent dysmenorrhea. Onset of dysmenorrhea soon after menarche with an increase in symptom severity should raise clinical suspicion of these anomalies. In the presence of a non-communicating horn with functional endometrium, menstrual collection leads to cyclic abdominal pain. Another cause of pain in these patients is endometriosis, which is thought to result from transtubal menstrual reflux (6).

In these cases, while a specific diagnosis can be obtained clinically following menarche in many patients, they may rarely present with an acute abdomen and the condition may be diagnosed during emergency surgery, as in our case (7,8). Pelvic ultrasound can be used for screening but has a sensitivity of only 26% in detecting these anomalies (9). Our patient presented with acute abdomen and a preoperative diagnosis was not made correctly by ultrasound in the emergency department of a small center. MRI seems to be gold standard for diagnosis of these anomalies (10). This imaging modality allows surgeons to plan their procedures. Surgical resection often necessary if the diagnosis of a non-communicating rudimentary horn with functional endometrium is made for symptomatic relief and preventing possible complications.

References

1. Breech LL, Laufer MR. Mullerian anomalies. *Obstet Gynecol Clin N Am* 2009;36(1):47-68.
2. Atmaca R, Gemen AT, Burak F, Kafkasli A. Acute abdomen in a case with noncommunicating rudimentary horn and unicornuate uterus. *JLS* 2005;9(2):235-7.
3. Kuscu NK, Lacin S, Kartal O. Rupture of rudimentary horn pregnancy at the 15th week of gestation: A case report. *Eur J Obstet Gynecol Reprod Biol* 2002;102(2):209-10.
4. Junqueira B, Allen L, Spitzer R, et al. Müllerian duct anomalies and mimics in children and adolescents: Correlative intraoperative assessment with clinical imaging. *Radiographics* 2009;29(4):1085-103.
5. Grimbizis GF, Gordts S, Sardo ADS, et al. The ESHRE/ESGE consensus on the classification of female genital tract congenital anomalies. *Hum Reprod* 2013;28(8):2032-44.
6. Matalliotakis IM, Koumantakis G, Koumantakis EE. Pulmonary endometriosis in a patient with unicornuate uterus and noncommunicating rudimentary horn. *Fertil Steril* 2002;78(1):183-5.

7. Graziani M, Carnevale E, Cacchione O, Fassanelli S. Hematometra in urogenital malformation: A rare cause of postmenarchal acute abdomen. *Radiol Med* 1995;89(1-2):168-71.
8. Kinjo K, Kasai T, Ogawa K. Hematometra and ruptured hematosalpinx with ipsilateral renal agenesis presenting as diffuse peritonitis. *Intensive Care Med* 1997;23(3):354.
9. Jayasingue Y, Rane A, Harry S, et al. The presentation and early diagnosis of the rudimentary uterine horn. *Obstet Gynecol* 2005;105(6):1456-67.
10. Letterie GS, Haggerty M, Lindee G. A comparison of pelvic ultrasound and magnetic resonance imaging as diagnostic studies for mullerian tract abnormalities. *Int J Fertil Menopausal Stud* 1995;40(1):34-8.