








Dorsal approach technique for the visualization of the aortic arch

Aort kemeri görüntülenmesinde dorsal yaklaşım tekniği

Fırat Ökmen¹  Hüseyin Ekici¹  Metehan İmamoğlu¹  Sabahattin Anıl Arı² 
Sabina Garakhanova¹  Ahmet Mete Ergenoğlu¹  Ahmet Özgür Yeniel¹ 

¹ Department of Obstetrics and Gynecology, Faculty of Medicine, Ege University, Izmir, Turkey

² Menemen State Hospital, Department of Obstetrics and Gynecology, Izmir, Turkey

Abstract

Aim: In this study, we aimed define a new technique to visualize the aortic arch in order to diagnose aortic arch anomalies with a dorsal approach when fetal spine is in anterior position within the uterus.

Materials and Methods: 115 patients who were referred to the prenatal screening unit between gestational weeks 20-40 were admitted to the study. 110 patients with normal cardiac findings and 5 fetuses with postnatally confirmed diagnosis of coarctation of aorta were evaluated with the new technique.

Results: Aortic arch of 115 fetuses were successfully visualized with the technique defined in detail.

Conclusion: The dorsal approach for the visualization of the aortic arch seems as a durable and a convenient technique for the fetal cardiac evaluation, especially in terms of better diagnostic capability for aortic arch pathologies under circumstances where the ventral approach is not feasible.

Keywords: Fetal ultrasonography, aortic arch, fetal cardiac evaluation, congenital heart disease, coarctation of aorta.

Öz

Amaç: Bu çalışmada, fetus dorso-anterior pozisyondayken aort kemerinin görüntülenmesi ve anomalilerinin tespiti için yeni bir teknik tanımlamayı amaçladık.

Gereç ve Yöntem: 20. ile 40. gebelik haftalarında prenatal değerlendirme birimine yönlendirilen 115 gebe çalışmaya dahil edildi. Normal bulgulara sahip 115 fetus ile doğum sonrası konfirme edilmiş beş aort koarktasyonlu fetus tanımlanan yeni teknik ile değerlendirildi.

Bulgular: 115 dorso anterior duruşlu fetusta aort kemeri tanımlanan yeni teknikte başarıyla gösterilmiştir.

Sonuç: Aort kemerinin izlenmesinde dorsal yaklaşım, özellikle ventral yaklaşımın mümkün olmadığı durumlarda aort kemerinin patolojileri için daha iyi tanı kabiliyeti ile uygun bir teknik olarak kullanılabilir.

Anahtar Sözcükler: Fetal ultrasonografi, aort kemeri, fetal kardiyak değerlendirme, konjenital kalp hastalıkları, aort koarktasyonu.

Introduction

Among all congenital malformations affecting fetuses and new-born infants, congenital heart disease (CHD) is the most-common group. The incidence of moderate-to-severe CHD has been reported to be 5–6 per 1,000 live-born infants in many publications (1). It is estimated that,

approximately 80% of CHD occurs in fetuses of mothers without known risk factors. Therefore, screening for fetal CHD is a challenging task (2, 3). CHD is accounted for the largest proportion (30% to 50%) of mortality caused by birth defects (4).

Corresponding author: Sabahattin Anıl Arı
Menemen State Hospital, Department of Obstetrics and
Gynecology, Izmir, Turkey
E-mail: s.anil.ari.md@gmail.com

Application date: 07.11.2019

Accepted: 11.03.2020

Many studies have shown the importance of prenatal diagnosis in congenital heart defects for improving the morbidity rates among these patients (5-7). However, the percentage of prenatal diagnosis of CHD's are reported to be between %30-50 (6-8). Therefore, developing newer diagnostic techniques to improve the detection rates of CHDs stands as a requirement.

The visualization of aortic arch has been defined as a ventral approach in the sagittal plane, while the fetal spine is in a posterior position within the uterus (9). To the best of our knowledge, a dorsal approach to visualize the arch while the fetal spine is adjacent to the anterior wall has never been described so far. Our aim in this study is to define this technique and prove that it is durable in situations when the fetal position is inappropriate for the ventral visualization of the aortic arch.

Materials and Methods

Patients enrolled in this study were selected among the patients who were referred to the antenatal screening unit at the Obstetrics and Gynecology department of Ege University Hospital between January 2017 and January 2018 for second trimester anomaly screening. The local ethics committee of Ege University approved the trial.

All patients were evaluated at 20-40 gestational weeks. The Doppler measurements were conducted by the same experienced physician (F.O.) for all patients using a Voluson E8 ultrasound machine (GE Healthcare, United Kingdom) with a Rab 4-8d 4D probe (GE Healthcare, United Kingdom). Informed consent was obtained from all participants.

The technique was tested in 110 patients with a postnatally confirmed normal cardiac anatomy and 5 patients with a postnatally confirmed diagnosis of coarctation of aorta (CoA). The prenatal diagnosis of CoA was performed via visualization of the aortic arch on a sagittal plane with ventral approach, followed by the demonstration of turbulent flow with color Doppler and increased blood flow with spectral Doppler. Patients were re-evaluated with the dorsal approach technique described below and same diagnostic parameters were obtained.

Determination of fetal situs and lie is required on the first hand. The probe is positioned as to visualize the fetal spine on a sagittal plane as shown in (Figure-1). Then, the probe is moved towards the left of the fetus and the spine, and tilted with an angle to the right in order to obtain a

complete image of the arch and the descending aorta (Figure-2). A rotation of 15 degrees towards left side of the fetus should also be performed for the appropriate visualization for the late second trimester and third trimester fetuses (Figure-3). The aortic arch and the descending aorta can completely be visualized if these steps are sequentially followed.

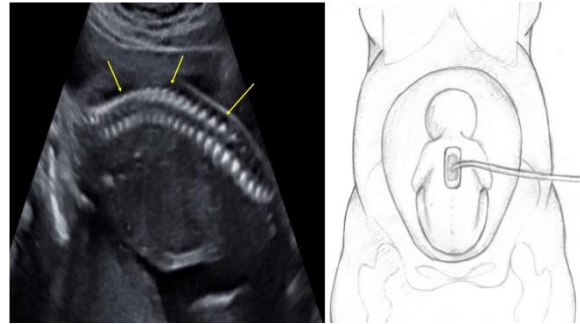


Figure-1. Fetal spine (arrows) in the sagittal plane.

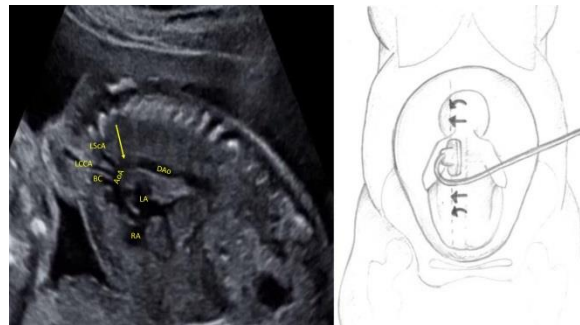


Figure-2. Aortic arch with the dorsal approach. Arrows point to aortic isthmus. LSCA: Left subclavian artery; LCCA: Left common carotid artery; BC: Brachiocephalic artery; AoA: Aortic arch; DAo: Descending aorta; LA: Left atrium; RA: Right atrium.

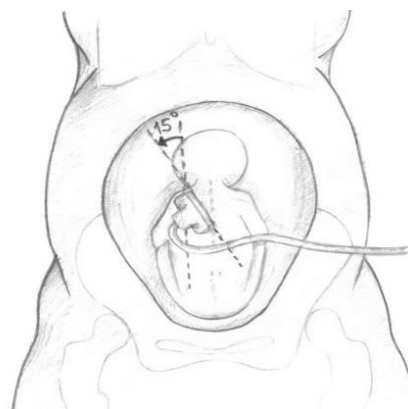


Figure-3. Rotation of the probe to visualize the aortic arch with advancing gestational age.

Results

Total number of 115 patients, consisting of 110 fetuses with normal cardiac anatomy and 5 patients with postnatally confirmed diagnosis of CoA were evaluated. 110 patients with a mean gestational age of 30.7 weeks were included and aortic arch were successfully visualized with the dorsal approach.

Mean gestational age for the diagnosis of CoA was found to be 30 weeks for the five patients with CoA. Two patients were found to be having ventricular septal defects (VSD) and one patient had a persistent left superior vena cava and a VSD associated with CoA. Other two cases had isolated CoA only. Gestational week of diagnosis and additional findings are listed in (Table-1).

Table-1. Diagnosis weeks and additional findings of patients with CoA.

Patient Number	Gestational week of Diagnosis	Additional Findings
1	33	Ventricular septal defect
2	25	Ventricular septal defect
3	24	Isolated
4	33	Ventricular septal defect + persistent left superior vena cava
5	35	Isolated

Dorsal approach for the visualization of the aortic arch was found to be successful to demonstrate the CoA in all five patients. All patients were re-evaluated with postnatal echocardiography and the diagnosis was confirmed. (Figure-4) shows the ultrasound image of one of the patients with CoA with the dorsal approach.

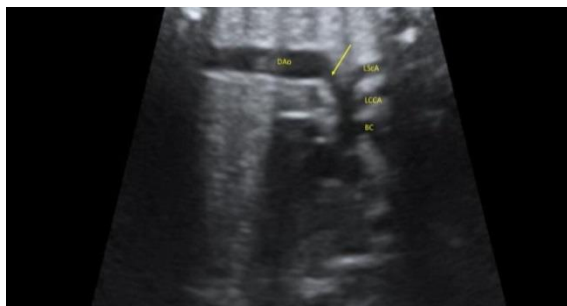

Figure-4. Ultrasound image of CoA with the dorsal approach. Arrows point to aortic isthmus and coarctation. LScA: Left subclavian artery; LCCA: Left common carotid artery; BC: Brachiocephalic artery; DAo: Descending aorta.

Discussion

Fetal cardiac evaluation is undoubtedly a challenging process, both to practice and teach, due to the rich variation in complex pathologic presentations. Sagittal visualization of fetal aortic arch presents additional information to the findings acquired in the three-vessel trachea view in order to evaluate the aortic arch anomalies such as CoA and interrupted aortic arch.

CoA is shown to be observed in 5 % of newborns with a diagnosis of CHD (10). An increased risk of recurrence is also reported as 2-6 % with the history of a prior newborn with CoA. The risk is reported as 4 % if the mother has a diagnosis of CoA (11,12).

There is a number of techniques defined for the sagittal visualization of the aortic arch with a ventral approach. Yoo et al. defined their technique with the principal of positioning the probe in order to visualize the ascending aorta and the descending aorta in the same plane in the three-vessel view on the first hand, and rotating the probe 90 degrees afterwards to obtain the candy cane view of the aortic arch with its branches towards fetal head and neck (9). Another ventral approach is defined as visualizing the aortic arch in the left parasagittal plane by sliding the probe from the sagittal view of the thoracic fetal spine to the left.

However, in some instances, the fetal position may not always be ideal for the ventral approach to be performed. With advancing gestational age, the fetal chin is approximated to the fetal thorax and the echogenicity of the ribs increase. In addition, fetal spine is frequently observed in the anterior position. Dorsal approach for the aortic arch seems durable for the fetal cardiac evaluation to be appropriately completed under these circumstances.

The advancing technology of modern ultrasonography devices, especially three-dimensional (3D) and four-dimensional (4D) screening techniques have significantly contributed to the increased rate of detection of cardiac pathologies so far. However, the use of ultrasonography devices bearing these technologies are costly and may not be available in every hospital setting. Therefore, improvement of two-dimensional (2D) techniques may also be beneficial for widespread application of fetal cardiac screening in terms of decreasing the costs and increasing the number of patients screened.

Dorsal approach also bears some limitations. Increased vertebral echogenicity with advancing gestational age may interfere with the sagittal views. In addition, if the fetal lie is longitudinal and the spine is located in proximity to the maternal right side, obtaining an ideal view may be difficult because the probe would need to be moved to the lateral of the maternal abdomen with advanced gestational age.

Our technique has not been tested in patients with interrupted aortic arch. However, we believe that the dorsal approach for the visualization of

the aortic arch would be beneficial in this group of patients as well.

Conclusion

The dorsal approach for the visualization of the aortic arch seems as a durable and a convenient technique for the fetal cardiac evaluation, especially in terms of better diagnostic capability for aortic arch pathologies under circumstances where the ventral approach is not feasible.

We declare that we have no conflict of interest.

Conflict of interest: The authors have not declared any conflict of interest in this study.

References

1. Hunter, L.E. and J.M. Simpson, Prenatal screening for structural congenital heart disease. *Nat Rev Cardiol*, 2014. 11 (6): 23-34.
2. Kleinert, S., Routine prenatal screening for congenital heart disease. *Lancet*, 1996. 348 (9031): 836.
3. Stumpflen, I., et al., Effect of detailed fetal echocardiography as part of routine prenatal ultrasonographic screening on detection of congenital heart disease. *Lancet*, 1996. 348 (9031): 854-7.
4. Gilboa, S.M., et al., Mortality resulting from congenital heart disease among children and adults in the United States, 1999 to 2006. *Circulation*, 2010. 122 (22): 2254-63.
5. Familiari, A., et al., Risk Factors for Coarctation of the Aorta on Prenatal Ultrasound: A Systematic Review and Meta-Analysis. *Circulation*, 2017. 135 (8): 772-85.
6. Trines, J., et al., Effectiveness of prenatal screening for congenital heart disease: assessment in a jurisdiction with universal access to health care. *Can J Cardiol*, 2013. 29 (7): 879-85.
7. Oster, M.E., et al., A population-based study of the association of prenatal diagnosis with survival rate for infants with congenital heart defects. *Am J Cardiol*, 2014. 113 (6): 1036-40.
8. Jaeggi, E.T., et al., Comparative analysis of pattern, management and outcome of pre- versus postnatally diagnosed major congenital heart disease: a population-based study. *Ultrasound Obstet Gynecol*, 2001. 17 (5): 380-5.
9. Yoo, S.J., et al., Fetal sonographic diagnosis of aortic arch anomalies. *Ultrasound Obstet Gynecol*, 2003. 22 (5): 535-46.
10. Ferencz C, Rubin J, Loffredo C, Magee C. Epidemiology of congenital heart disease: the Baltimore-Washington Infant Study, 1981–1989. Mt. Kisco, New York: Futura Publishing; 1993. 11 (5): 455-6.
11. Nora JJ, Berg K, Nora AH. Cardiovascular diseases: Genetics, epidemiology and prevention, New York: Oxford University Press; 1991: 53-81.
12. Allan LD, Crawford DC, Chita SK, Anderson RH, Tynan MJ. Familial recurrence of congenital heart disease in a prospective series of mothers referred for fetal echocardiography. *Am J Cardiol* 1986; 58: 334-7.